

VEGF expression and new blood vessel after dental X-ray irradiation on fractured tooth extraction wound

by Niluh Woroprobosari

FILE	NILUH_RINGGA_OK-AUP_21_APRIL_2016.DOC (17.17M)		
TIME SUBMITTED	24-MAY-2016 12:30PM	WORD COUNT	3692
SUBMISSION ID	677755928	CHARACTER COUNT	18959

VEGF expression and new blood vessel after dental X-ray irradiation on fractured tooth extraction wound

Niluh Ringga Woroprobosari,¹ Jenny Sunariani,² and Eha Renwi Astuti³

¹Department of Dental Radiology, Faculty of Dentistry, Universitas Islam Sultan Agung, Semarang-Indonesia

²Department of Oral Biology, Faculty of Dental Medicine, Universitas Airlangga, Surabaya-Indonesia

³Department of Dental Radiology, Faculty of Dental Medicine, Universitas Airlangga, Surabaya-Indonesia

ABSTRACT

Background: Dental X-ray has an important role in dentistry. Complication case such as tooth fracture extraction requires this examination to determine the appropriate treatment measures. Dental X-ray can also cause a negative impact to the body at cellular and even molecular level. **Purpose:** The aim of this study was to evaluate the decrease of vascular endothelial growth factor (VEGF) expression and new blood vessels number caused by dental X-ray irradiation on fractured tooth extraction wound on day 3 and 7 after extraction. **Method:** We used 30 wistar rats which was randomly divided into 6 groups. Each rat's central insisive of left mandible was fractured and then extracted after or without X-ray irradiation. Group KA and KB were control groups without irradiation. Group P1 A and P1 B were treatment groups with 0.08 mSv irradiation dose. Group P2 A and P2 B were treatment groups with 0.16 mSv irradiation dose. The subject from group KA, P1 A, and P2 A were sacrificed and sockets were collected at day 3. The subject from group KB, P1 B, and P2 B were sacrificed and sockets were collected at day 7. Socket were processed and painted with hematoxylin eosin and immunohistochemistry, then observed with a microscope. Data processing was performed with SPSS 16 through one way anova test and post hoc Tukey test HS. **Result:** The lowest means expression of VEGF and the number of new blood vessels on the day 3 was found in P2 A group, and the highest found in the KA group. The lowest means expression of VEGF and the number of new blood vessels on the day 7 was found in P2 B group, and the highest found in the KB group. **Conclusion:** Dental X-ray irradiation dose of 0.08 mSv and 0.16 mSv causes decrease of VEGF expression and new blood vessels in the wound fractured tooth extraction in day 3 and day 7 post-extraction.

Keywords: X-ray irradiation; VEGF; angiogenesis; socket healing

Correspondence: Niluh Ringga Woroprobosari, Fakultas Kedokteran Gigi Universitas Islam Sultan Agung, Jl. Kaligawe Semarang, Indonesia. E-mail: niluhringga@gmail.com

INTRODUCTION

Tooth extraction is a common action performed by a dentist. Tooth extraction process can cause complications with a prevalence of 37.6% in Indonesia. Fractures are the most common complication encountered in Indonesia with a prevalence of 30.4%.¹ Tooth extraction injures the dental tissues area where the tooth extracted, including sockets, mucous, and blood vessels. This leads to the wound healing process by the body.² Angiogenesis is a process occurred in the proliferation phase.³ Proliferation phase occurs in the range of day 3 to day 5 post-injury.⁹ This process is characterized by the formation of new blood vessels around the wound.⁴ Vascular endothelial growth factor (VEGF) is a growth factor initiates the formation of new blood vessels through the formation mechanism of budding.⁵

Dental X-ray plays an important role to support a diagnosis and to determine appropriate treatment, such as in the fracture extraction case.⁶ The common radiographs used to examine tooth extraction fractures is periapical radiographs.⁷ The use of dental X-ray irradiation in medical examination can also give negative impacts. Soft X-ray irradiation at 50 Rad, 100 Rad, and 700 Rad can slow down the wound healing process, inhibit cells proliferation, and activate cell apoptosis. Soft X-ray irradiation also inhibits the cells cycle at day 3 up to day 5, which may be one of the cellular mechanism to slow down the wound healing process.⁸

Irradiation can inhibit the early inflammatory response by reducing the infiltration of macrophages and neutrophils. Irradiation can also damage the blood vessels, resulting in the formation and maturation of granulation tissues are inhibited. Fibroblasts are damaged and re-epitelisation process becomes slow cause the wound healing process requires more amount of time.⁹ Dental X-ray periapical irradiation at 0.08 mSv dose can cause apoptosis in mucosal cells. sudah dapat menyebabkan apoptosis pada sel mukosa. Irradiation dose 0.08 mSv is the dosage used for periapical radiographic examination.¹⁰

Researchers observed the expression of VEGF and the number of new blood vessels after exposed to dental X-ray irradiation on the fracture wound of wistar rat tooth extraction. VEGF expression was observed through immunohistochemistry examination, while the formation of new blood vessels was observed through histological preparation observation with hematoxylin eosin staining. Tissues sampling was collected on the third day post-treatment since the beginning of proliferation phase, and on the seventh day post-treatment for a final extended period of proliferation phase if the wound healing process is inhibited.⁵

1

MATERIALS AND METHODS

This research is laboratory experiment with post-test only control group design.¹¹ The sample was selected by using simple random sampling of the population that met the need of inclusion criteria. Thirty male wistar rats were used for this research and were divided into 6 randomized groups in which each group consists of 5 male wistar rats. The control groups are KA and KB group with fracture of the left mandibular central incisors extraction without dental X-ray exposure. The treatment groups consist of P1 A and P1 B group with fracture of the left mandibular central incisors extraction and 0.08 mSv dental X-ray exposure, and P2 A and P2 B group with fracture of the left mandibular central incisors extraction and 0.16 mSv dental X-ray exposure. KA, P1 A, and P2 A groups were examined on the third day, while KB, P1 B, and P2 B groups were examined on the seventh day after extraction. The research subjects were adapted first to the environment of Laboratory of Biochemistry, Faculty of Medicine, Universitas Airlangga for 7 days with the treatment on the form of food, drink, and appropriate cage that meets the ethical standard of Health Research Ethics and Airworthiness Committee of Faculty of Dental Medicine, Universitas Airlangga.

The fracture extraction were performed to the whole subject of research on the left mandibular central incisor, after being given intramuscular ketamine and diazepam anaesthesia. Each rat was in supine position (abdomen above) and the tongue of the rat was held under a sterile gauze rolls. Sonde was inserted in the depth of 2 mm into the gingival sulcus of the left mandibular central incisor and was moved around the sulcus to damage the periodontal ligament. The left mandibular central incisor was fractured by using diamond bur. The extraction of the remaining part of tooth fractures was resumed after dental X-ray exposure to the treatment group.

The rats were fixed by using wire netting first so that they could not move when the exposure was given. Cone beam periapical air photo was directed to the left mandibula of the rat. The extraction of the remaining fractures was performed after the dental X-ray irradiation was given.

The research subjects were anaesthetized by using 10% ether solution. Each rat was put in a glass box with a lid, then the entire wall of the inner box was sprayed with 10% ether and was closed again so that the steam can be fully inhaled by the rats. Left mandible was taken and was immediately put in a container of NBF 10 fixated solution.

Mandibular tissues fixation was performed in 10% neutral buffered formalin (NBF). The next stage was decalcification so that the calcium content within the tissues becomes lost and

facilitates the tissues processing to the next stage. Soft bone tissues were dehydrating, clearing, and then embedding into paraffin blocks to be easily cut with microtome. The pieces were placed into waterbath by using sengkeli with 40-50⁰ C temperature, until they stuck into object glass, and then were painted with hematoxylin staining eosin.¹² VEGF observation was performed by using monoclonal antibody VEGF Santa Cruz, SC-152 and the kit Novolink, Novocastra, RE7230-K. The painting process was performed according to the instructions of use. Then the preparation was performed with mounting by using entelan.¹² The results reading was done by observing the preparation under the light microscope with 1000x magnification. New blood vessels were observed by counting the number of lumens arterioles and venules around the sockets on the former extraction in one visual field quantitatively. VEGF expression was calculated by examining the positive expression of the growth factor on the dark brown coloured macrophage cells, in which this interpretation was done quantitatively. The reading of VEGF expression and new blood vessels were done five times visual field for each sample, before taking the mean value. The data were analyzed by SPSS 16 program through one way Anova test and post hoc test Tukey HS.

RESULTS

The mean and standard deviation value of VEGF expression and the number of new blood vessels after the exposure of dental X-ray irradiation on fracture wound of Wistar rat tooth extraction can be seen in Table 1. Figure 1 is a picture of VEGF positive expression. The figure of VEGF positive expressions are dark brown coloured and evenly circulated around blood vessel lumens in which can be observed in Figure 1-A (control group A) and B (control group B). Figure 1-C shows VEGF expressions in group P1 A which are brown coloured and less than in Figure A and B. The observation of group P1 B in Figure 1-D resulting in the similar figure to Figure 1-C. VEGF expressions are brown coloured and the least one is seen in Figure 1-E (group P2 A) and Figure 1-F (group P2 B).

The observation result of the new blood vessel can be seen in Figure 2. Figure 2-A shows a picture of the new and dense blood vessels in control group KA. The figure of dense blood vessels can also be seen in Figure 2-B which is in control group KB. The density of blood vessels can be seen from the lumens density of blood vessels formed. Group P1 A shows the rarer figure of blood vessel lumens in Figure 2-C than in figure A and B. It is also

shown in Figure 2-D, that is in group P1 B. Figure 2-E and F show the least density in group P2 A and P2 B, when are compared to the previous figures.

The data were then processed by using SPSS 16.0 program for Windows. First statistical test was conducted by using Kolmogorov Smirnov test to find out the distribution of the research data as a requirement prior to the one way Anova test. The test results of all groups show that p value is greater than 0.05 so it can be stated that all data were normally distributed. Levene test was also conducted first to see the variance homogeneity of the groups that will be compared. The results of Levene test show that the values were above 0.05, so it can be stated that the variance of the entire data is homogeneous variant. The analysis was then followed by parametric test using one way Anova test because the data had normally distributed and had homogeneous variances. The analysis was continued by post hoc test Tukey HS to compare whether there are any differences between each researched group.

DISCUSSION

The mean values of each group showed that the greater the dose of dental X-ray irradiation is given, the lesser the VEGF expression in the fracture sockets of tooth extraction on the day-3 and day-7. The decreased expression of VEGF is caused by the biological effects of ionized radiation. The biological effects can occur without the interference of threshold radiation dose, namely stochastic effects. Stochastic effects are often found in DNA damage. DNA damage can be directly or indirectly resulted from the formation of free radicals and water molecules.¹³

In the research conducted by Saputra the exposure of dental X-ray irradiation was given to the buccal mucosa of Wistar rats. The result showed that there was an increase of apoptosis and necrosis cells which were proportional to the increased dose of dental X-ray irradiation as much as 0.8 mSv, 0.16 mSv, and 0.24 mSv. Those results correspond with the results in this research, that there is damage to the body either cellular or molecular due to the exposure of dental X-ray irradiation even though only in small doses. The damage caused by the exposure to the dental X-ray irradiation is proportional to the increased doses given.

Macrophages, neutrophils, endothels, fibroblasts and smooth muscle cells are the cells that produce VEGF. Monocytes are the most damaged cells when experiencing oxidative stress compared to macrophages. The study showed that monocytes which were given oxidative stressor such as Tert-Buyl hydroperoxide (BOOH) 400 μ M did not express protein 5 Poly ADP-Ribose) polymerase 1 (PARP-1) and X-ray repair Cross-Complimenting protein 1

(XRCC1). The study identified that the probable cause is the transcriptional down-regulation on monocytes. The absence of XRCC1 expression resulted in the decreased expression of Lig III α (deoxyribonucleic acid ligase III α) for XRCC1 is a protein that stabilizes Lig III. Protein deoxyribonucleic acid protein kinase catalytic subunit (DNA-PKcs) that plays role in the double strand repairment is also not detected on monocytes.¹⁴

Monocytes are more sensitive to oxidative agents than macrophages and neutrophils as monocytes are the progenitor cells that differentiate into macrophages and dendritic cells.¹⁵ Energy absorption of radiation by water molecules within cells causes molecules excitation and ionizing. Ions generated from the reaction will form free radicals within the body and can penetrate the lipid bilayer of the membranes and then lead to the cell damage.¹⁶

The decreasing of monocytes results in the decreasing of macrophages within sockets. In addition, the cells ability to repair themselves and adapt to the ionizing X-rays radiation will be limited. Most of macrophage cells will fail to adapt dan will be exposed to the biological effects of the radiation, which whill lead to the cells death. Macrophage cells that die will become debris and can inhibit the recovery of the other cells. Such condition will cause the decreasing of VEGF, as monocytes and macrophages are two types of cells involved in releasing VEGF to initiate a series of angiogenesis processes.

Cell damage from dental X-ray irradiation does not only occur on monocytes alone. The number of cells on peritoneal macrophages culture of the rats decreases after exposed to X-ray irradiation at dose of 3 Gy nd 6 Gy.¹⁵ The damage on neutrophils, monocytes, and macrophages will result in the decreased expression of VEGF, in accordance with the results of this study.

The comparisons between group KA and P1 A, and group KB and P1 B have no significant difference in the statistical tests. However, the data averagely showed the difference of VEGF expressions between the each group. The non-significant result may be caused by the biological effects resulted in dental X-ray irradiation at a dose of 0.08 mSv which was minimum and could be neutralized by the body, so that the data still showed the decreased espresion of VEGF but did not appear statistically. The mean result of new blood vessels from each group shows that the gretaeer the dose of dental X-ray irradiation is given, the lesser the number of new blood vessels formed around the sockets of fracture extraction on the day-3 and day-7.¹⁷

The decreased number of new blood vessels as the increased dose of radiation are also related to the decreased expression of VEGF and the cells on the fracture sockets of tooth

extraction. VEGF is a cytokine that initiates the angiogenesis and vaskulogenesis processes. The decreased expression of VEGF results in the inhibition of endothelial signaling process to move forming the bud. Barriers bud formation lead to the formation of capillary network become blocked, so that there is a decrease in the number of new blood vessels in sockets.¹⁸

The biological effects of ionizing X-rays radiation also directly affect the cells cycle. *Soft* X-ray irradiation at dose of 5.21 Gy slows down the wound healing rate on the third until the ninth day. This is caused by the cells cycle disruption, in which the cells stop in phase G₀/G₁ and S, and becomes slow in phase G₂/M.⁸ Cells cycle disruption results in the reduced proliferation and the increased apoptosis process, causing an imbalance in the proliferation stage. The decreased proliferation of endothelial cells and fibroblasts hamper the formation of new blood vessels which affects the next wound healing stage.¹⁵

There is no significant difference in the comparison between group KA and P1 A and between group KB and P1 B. However, the average number of new blood vessels still shows the differences where the mean value of group P1 A is smaller than the mean value of group KA, and the mean value of group P1 B is smaller than the mean value of group KB. This result may be caused by the biological effects on dental X-ray irradiation at dose of 0.08 mSv that results in new blood vessels are still minimum, so they do not appear statistically compared to the group without dental X-ray irradiation. In conclusion, dental X-ray irradiation dose of 0.08 mSv and 0.16 mSv causes decrease of VEGF expression and new blood vessels in the wound fractured tooth extraction in day 3 and day 7 post-extraction.

REFERENCES

1. Tim Riskesdas. Penyakit tidak menular: kesehatan gigi. Riskesdas 2007. Departemen Kesehatan Republik Indonesia; 2008. p. 130-47.
2. Coulthard P, Keith H, Philip S, Theaker ED. Master dentistry: oral and maxillofacial surgery, radiology, pathology and oral medicine. 2nd ed. Edinburg: Churchill Livingstone; 2008. p. 241-5.
3. Monaco JL, Lawrence WT. Acute wound healing: an overview. Clin Plastic Surg 2003; 30: 1-12.
4. Mendonça RJ. Angiogenesis in wound healing. In: Davies J, editor. Tissue regeneration from basic biology to clinical application. Rijeka: InTech; 2012. p. 93-98.
5. Bao P, Kodra A, Tomic-Canic M, Golinko MS, Ehrlich HP, Brem H. The role of vascular endothelial growth factor in wound healing. J Surg Res 2009; 153(2): 347–58.

6. Williamson GF. Best practices in intraoral digital radiography. *RDHmag* 2011; 11(11): 79-89.
7. Peterson JL. Oral and maxillofacial surgery. 4th ed. St. Louis: Mosby Co; 2003. p. 116-7.
8. Liu X, Liu JZ, Zhang E, Li P, Zhou P, Cheng TM. Impaired wound healing after local soft X-ray irradiation in rat skin: time course study of pathology, proliferation, cell cycle, and apoptosis. *J Trauma*. 2005; 59(3): 682-90.
9. Gu Q, Wang D, Cui C, Gao Y. Effects of radiation on wound healing. *J Environ Pathol Toxicol Oncol* 1998; 17(2): 117-23.
10. Saputra D. Apoptosis dan nekrosis sel mukosa rongga mulut akibat radiasi sinar-x dental radiografik. Surabaya: Universitas Airlangga; 2012. p. 61-78.
11. Notoatmodjo S. Metodologi penelitian kesehatan. Jakarta: PT. Asdi Mahasatya; 2005. p. 167.
12. Survana SK, Layton C, Bancroft JD. Bancroft's theory and practice of histological techniques. 7th ed. Oxford: Elsevier Ltd; 2013. p. 70-139, 172-86, 316-52.
13. Alatas Z. Efek kesehatan pajanan radiasi dosis rendah. Prosiding Seminar Aspek Keselamatan Radiasi dan Lingkungan pada Industri Non-Nuklir. Jakarta: BATAN; 2003. p. 28-38.
14. Bauer M, Goldstein M, Christmann M, Becker H, Heylmann D, Kaina B. Human monocytes are severely impaired in base and dna double-strand break repair that renders them vulnerable to oxidative stress. *PNAS* 2011; 108 (52): 21105-10.
15. Cunha A, Lourenço A, Cancela J, Castelhana J, Carvalho S, Saiote A, *et al.* Effect of ionizing radiation on rat peritoneal macrophages. *Revista Do DETUA* 2007; 4(7): 818-21.
16. Azzam EI, Jay-Gerin J, Pain D. Ionizing radiation-induced metabolic stress and prolonged cell injury. *Can Let* 2012; 327(2012): 48-60.
17. Kumar V, Abbas AK, Fausto N, Aster J. Robbins and cotran pathologic basis of disease. 8th ed. Philadelphia: Saunders Elsevier; 2010. p. 54-71, 102-04.
18. Lalani Z, Wong M, Brey EM, Mikos AG, Duke PJ, Miller MJ, *et al.* Spatial and temporal localization of FGF-2 and VEGF in healing tooth extraction sockets in a rabbit model. *J Oral Maxillofac Surg* 2005; 63(10): 1500-07.

Table 1. The mean value of VEGF expression and new blood vessels on the day-3 and 7

Group	VEGF expression		The number of new blood vessels	
	Mean \pm SD		Mean \pm SD	
	Day-3 (A)	Day-7 (B)	Day-3 (A)	Day-7 (B)
K	5.80 \pm 1.09	6.60 \pm 1.52	455.00 \pm 57.41	420.80 \pm 90.47
P1	5.40 \pm 1.67	6.20 \pm 1.48	383.00 \pm 41.67	315.20 \pm 80.12
P2	3.00 \pm 1.23	2.60 \pm 1.14	276.20 \pm 67.11	192.00 \pm 35.34

Notes: K= Fractures of Wistar rats tooth extraction without dental X-ray irradiation (control);

P1= Fractures of Wistar rats tooth extraction with dental X-ray irradiation 0.08 mSv; P2= Fractures of Wistar rats tooth extraction with dental X-ray irradiation 0.16 mSv.

Table 2. The p value post hoc test Tukey HS of VEGF expression on the day-3

Researched group	KA	P1 A	P2 A
KA	-	0.888	0.017
P1 A	0.888	-	0.039
P2 A	0.017	0.039	-

Table 3. The p value post hoc test Tukey HS of VEGF expression on the day-7

Researched group	KB	P1 B	P2 B
KB	-	0.893	0.002
P1 B	0.893	-	0.004
P2 B	0.002	0.004	-

Table 4. The p value post hoc test Tukey HS of new blood vessels on the day-3

Researched group	KA	P1 A	P2 A
KA	-	0.150	0.001
P1 A	0.150	-	0.028
P2 A	0.001	0.028	-

Table 5. The p value post hoc test Tukey HS of new blood vessels on the day-7

Researched group	KB	P1 B	P2 B
KB	-	0.095	0.001
P1 B	0.095	-	0.049
P2 B	0.001	0.049	-

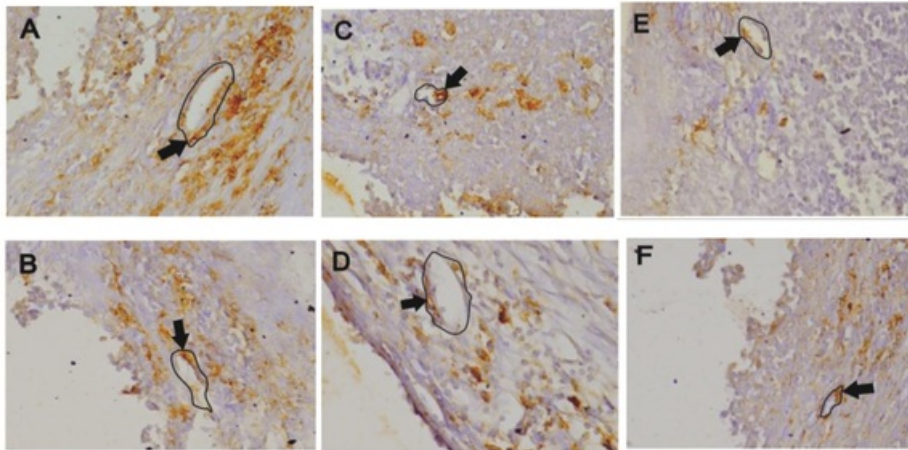


Figure 1. The picture of immunohistochemistry on VEGF expression (circled and pointed by black small arrow → blood vessel lumens) with monoclonal antibody VEGF anti-rats and paint material DAB on sockets of Wistar rats tooth extraction. The observation was performed by microscope with 1000x magnification. Positive expression is shown by the coloured figure around the blood vessel lumens. (A) group KA, (B) group KB, (C) group P1 A, (D) group P1 B, (E) group P2 A, (F) group P2 B.

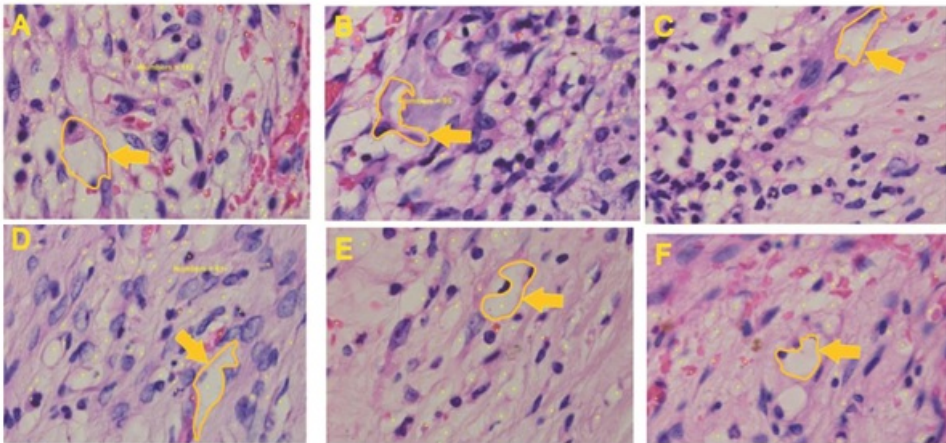


Figure 2. The figure of histological lumens of new blood vessels (circled and pointed by yellow small arrow → blood vessel lumens) with hematoxylin eosin painting. The observation was performed by microscope with 1000x magnification. (A) group KA; (B) group KB; (C) group P1 A; (D) group P1 B; (E) group P2 A; (F) group P2 B.

VEGF expression and new blood vessel after dental X-ray irradiation on fractured tooth extraction wound

ORIGINALITY REPORT

7%

SIMILARITY INDEX

2%

INTERNET SOURCES

5%

PUBLICATIONS

3%

STUDENT PAPERS

PRIMARY SOURCES

1	Submitted to iGroup Student Paper	2%
2	Submitted to University of Salford Student Paper	1%
3	Arundina, Ira, S. Theresia Indah Budhy, Intan Nirwana, Retno Indrawati, and Muhammad Luthfi. "Toxicity Test n-Hexane: Ethyl Acetate (3:7) Fraction of Sudamala (<i>Artemisia vulgaris</i> L.)", <i>Procedia Chemistry</i> , 2016. Publication	1%
4	Atiba, A.. "Aloe vera oral administration accelerates acute radiation-delayed wound healing by stimulating transforming growth factor- β and fibroblast growth factor production", <i>The American Journal of Surgery</i> , 201106 Publication	1%
5	dc.lib.unc.edu Internet Source	<1%
6	Asadi, Mohammad Reza, Giti Torkaman, Mehdi Hedayati, and Mahmood Mofid. "Role	<1%

of sensory and motor intensity of electrical stimulation on fibroblastic growth factor-2 expression, inflammation, vascularization, and mechanical strength of full-thickness wounds", The Journal of Rehabilitation Research and Development, 2013.

Publication

7 Koumoutsakos, Petros, Igor Pivkin, and Florian Milde. "The Fluid Mechanics of Cancer and Its Therapy", Annual Review of Fluid Mechanics, 2013. <1%

Publication

8 Rinastiti, M.. "Histological evaluation of rabbit gingival wound healing transplanted with human amniotic membrane", International Journal of Oral & Maxillofacial Surgery, 200603 <1%

Publication

9 David G Simpson. "Dermal templates and the wound-healing paradigm: the promise of tissue regeneration", Expert Review of Medical Devices, 07/2006 <1%

Publication

10 spandidos-publications.com <1%
Internet Source

11 www.researchgate.net <1%
Internet Source

12 Bahaa, Nevine, Safaa M. Shaker, and Azza <1%

Abd El Moneim Attia. "Microscopic study on the effect of early different fluids resuscitation on sepsis-induced acute lung injury in albino rat :", The Egyptian Journal of Histology, 2015.

Publication

13

Anna Fiedorowicz. "The ameboid phenotype of NG2 (+) cells in the region of apoptotic dentate granule neurons in trimethyltin intoxicated mice shares antigen properties with microglia/macrophages", Glia, 01/15/2008

Publication

<1%

14

www.rehab.research.va.gov

Internet Source

<1%

15

G. Perdigon. "Comparative effect of the adjuvant capacity of Lactobacillus casei and lipopolysaccharide on the intestinal secretory antibody response and resistance to Salmonella infection in mice", Food and Agricultural Immunology, 1995

Publication

<1%

EXCLUDE QUOTES ON

EXCLUDE MATCHES < 5 WORDS

EXCLUDE BIBLIOGRAPHY ON