

# The Role of Matrix Metalloproteinase-8 Enhance Periapical Bone Resorption in Chronic Apical Periodontitis

*by* Dian Agustin Wahjuningrum

---

**Submission date:** 11-Feb-2019 09:35AM (UTC+0800)

**Submission ID:** 1075980222

**File name:** Science\_and\_Clinical\_Lab\_Vol\_5\_June\_23-25-34.pdf (332.07K)

**Word count:** 2891

**Character count:** 16152

## **The Role of Matrix Metalloproteinase-8 Enhance Periapical Bone Resorption in Chronic Apical Periodontitis**

**DIAN AGUSTIN WAHJUNINGRUM**

ORCID No. 0000-0003-0787-8935

dawahjuningrum@gmail.com

Universitas Airlangga, Surabaya, Indonesia

---

### **ABSTRACT**

Nowadays, Chronic Apical Periodontitis closely associated with bacterial infections that result in alveolar bone resorption, still remains a pressing problem. One of the bacteria causing Apical Periodontitis is *Porphyromonas gingivalis* (Pg). Component of the Pg such as LPS has an ability to stimulate production of pro-inflammatory cytokines such as MMP8 that contributes to the degradation of periapical tissue. However, the role of MMP8 in periapical bone resorption remains unclear. The aim of this study was to analyze the role of MMP8 in periapical bone resorption. With Posttest only controlled group design, 21 of the three groups of male Rat Wistar were subjected. Chronic Apical Periodontitis was induced by exposure intrapulpal injection of 2 microliter PgLPS1435/1450 (1,0µg/ml) in aquades solution for three weeks on first upper molar. Group (P1) inducted LPS Pg, group (P2) got just LPS Pg solution and (Po) as control. After induction each subject was analyzed by MMP8 expression using immunohistochemistry assay. Data were analyzed using one-way Analysis of Variance (ANOVA) and Turkey's test statistics. The results showed expressions MMP8 in group P1 which were significantly different from group P2  $p = 0,001^*(p<0,05)$ . Macrophage expressing MMP8 may play an important role in increasing the destructive mediators in chronic apical periodontitis.

## KEYWORDS

Clinical laboratory, endodontic, MMP8, immunohistochemistry assay, experimental design, Indonesia

## INTRODUCTION

Caries can be considered as a factor triggering living micro-organisms to come into pulp. Tooth decay involving the pulp tissue can also be caused by physical agents, chemical agents, and bacterial agents. Generally, sufficient lesion removal is aimed to restore the condition of the pulp, but since in irreversible inflammation cases it can also cause damage to the periapical tissues, root canal treatment is needed. However, the damage of the periapical tissue, which is not eliminated though focal infection occurred at the root canals is eliminated, is still debatable. One of the main goals of root canal treatment is to eliminate bacteria and its products. In this case, focal infection paradigm becomes the base. Periapical damage has the role to the success and failure of endodontic treatment and until now, the mechanism of periapical damage is still debatable (Cohen et al., 2002; Nair, 2004). Many attempts have been held to increase the success of root canal treatment but the result is still unfavorable. Although adequate root canal treatment has been performed, there are root canal treatment failures, detectable through persistent and continuing periapical resorption (Nair, 2004). Gram-negative bacteria, especially *dark (black) pigmented bacteria (Porphyromonas)*, needs more attention since it has virulence factor of endotoxin in cell walls such as *lipopolysaccharides (LPS)* consisting of polysaccharides (polymerized sugars), lipids (fatty acids containing complexes), and proteins (Reife et al., 2005; Quinn et al., 2001; Wang et al., 2006; Stashenko et al., 2007). As a result, the body will be able to give the immune response by producing cytokines caused by LPS induction (Siqueira & Isabela, 2007).

The extracellular matrix is a complex integrated system responsible for the physiologic properties of the connective tissue. Invasion of microorganism from pulp to periapical tissue result in inflammation that can lead periapical bone destruction. Due to an array of proteolytic enzymes, this destructionist released because of the imbalance homeostasis during the host-bacterial interaction. Among the enzymes, *matrix metalloproteinase (MMPs)* play a key role in mediating and regulating periapical bone resorption characteristically observed in chronic apical periodontitis lesions (Stashenko, 2002; Janna, 2003). MMPs



are important in physiological growth and tissue remodeling. Their role in tissue destructive pathological conditions is evident but still not completely clarified (Janna, 2003).

*Matrix Metallo Proteinases* (MMPs) makes up a group of zinc and calcium dependent endopeptidases which degrades different types of *Extracellular Matrix* (ECM) depending on type of MMP. MMP8, furthermore, is known as pro-inflammatory cytokines associated with immune response (Kiili et al., 2002). MMP8 is also known as a potential cytokine in *osteoclastogenesis* and inflammation processes inducing bone damage (Utomo, 2009). Nevertheless, until nowadays, the exact mechanisms underlying the role of MMP8 in inflammation that triggers to *osteoclastogenesis* and bone resorption-remodeling remains unclear and is still considered as old one. MMP-8 levels in periapical exudates were significantly reduced during root canal treatment. Measuring MMP-8 levels in periapical exudates may be used as a biochemical indicator or molecular marker to monitor the inflammatory activity and success in root canal treatment.

### OBJECTIVE OF THE STUDY

12

The aim of this study was to analyze and describe the role of MMP8 in periapical bone resorption.

### MATERIALS AND METHODS

This experimental study was conducted by means of the test only on group design. As this is an experiment with the purpose for getting the evidence, the study uses animal for the object of the experiment (Robert, 1998). The type of research used is a laboratory experiment. Samples used in this research were adult male Wistar rats age of 8-12 weeks with the weight of 120-150 g (Utomo, 2009). The samples were divided into three groups by random allocation, which are the treatment group induced with LPS Pg induction solvent (P1), the treatment group 2 induced only with LPS Pg induction solvent (P2), and the control group (P0).

The sample used is a Wistar Rat of 8-12 weeks old, with 150 gr weight. These Wistar rats were obtained from the Laboratory of Molecular Biology, University of Brawijaya, Malang produced specifically for research. The adaptation has been performed during the first- 2- week at the site of action. The sample was divided into three groups, one control group, the treatment group, and the

LPS induction of the LPS group treated with solvent. The induction of LPS was done through *intrapulpa* of experimental animals that advance in anesthesia with *ketamine* 80mg/kg, intraperitoneal BB. Resection of the maxilla and its teeth for the preparation of the apical periodontal ligament examination was performed 3 weeks post-induction. Then, the samples were sent to the laboratory for *immunohistochemical* test.

Materials used in this research are lipopolisakarida<sub>1435/1450</sub> (*tetra-acetylated*), *Pg* (Astarte Biologics, WA, USA, catalog number 7010), and monoclonal antibodies against MMP8. *Pg*LPS<sub>1435/1450</sub> injection by intra pulp was conducted on the right maxillary first molar teeth of those experimental animals, wistar rats during three weeks to get periapical inflammation (Tripton, 1998). After three weeks, the wistar rats were fixed on the jaw retraction board, and then got anesthesia via intraperitoneal injection of ketamine (80mg/kg) and xylazine (10 mg/kg) in sterile PBS. The treatment was conducted through the perforation of the pulp roof of the first molar by using round bur no ¼. The size of the exposure is equivalent to the size of the diameter of the round bur. Two micro liters of *Pg*LPS<sub>1435/1450</sub> (1.0 ug/ml) in *aquades solution* was induced into intrapulp (Utomo, 2009). The closure of the cavity was then conducted by using a resin to prevent contamination with microorganisms located in the oral cavity after the treatment. After three weeks, Wistar rats got euthanize and maxillary molar resection. Finally the specimens from 21 samples were counterstained by using immunohistochemical technique and then MMP8 were counted at 400 × magnifications in hot-spot areas under a light microscope. The results were analyzed by using ANOVA test and Tukey HSD exams. *P* values less than 0.05 was considered to be significant.

## RESULTS AND DISCUSSION

The variables of this research included both observation and examination results on the number of cells in periapical tissues giving positive reaction to MMP8 by using immunohistochemical methods.

In Figure 1, it can be seen that cells giving a positive reaction had brown color. It indicates that there was a reaction between Ag (MMP8) and a monoclonal antibody (anti-MMP8).

The variable data obtained from the control group (Po), the treatment group with *Pg*LPS (P1) induction, and the treatment group with only the solvent *Pg*LPS (P2) was then shown in Table 1.

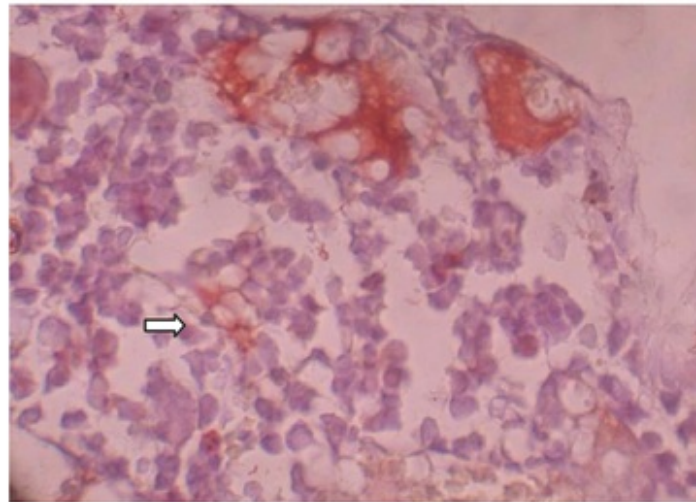


Figure 1. The Description of MMP8 expression in the periapical tissues of wistar rats through immunohistochemical examination. The positive expression of MMP8 was marked by arrows with 400x magnification.

Table 1 illustrates the description of the average (mean) and the standard deviation (SD) of the result data of the number of cells in the periapical tissues giving a positive reaction to monoclonal antibody, MMP8, through immunohistochemical methods. The normality distribution test (KS test) was then conducted on the result data.

Table 1. The results of the ANOVA F test for MMP8 variables

Sample group	N	Σ cell positive of MMP8		
		Mean ranks	SD	P
Po	7	0,43	0,535	25 p = 0,000*
P1	7	11,71	1,113	
P2	7	1,57	0,787	

\*Significant (p<0,05)

Table 2. The test result of the differences and the strength relation for MMP8 variables

	p0	p1	Beta	P
p0		0,000		
p1	0,000		0,972	0,000
p2	0,052	0,000		

\*Significant (p<0,05)



Based on the results, it was also known that the expression data of MMP8 in periapical tissues have homogeneous variance of  $p\text{-value} = 0.178$ , ( $p > 0.05$ ). To determine the difference of MMP8 among those groups, one-way analysis of variance (One way-ANOVA) was conducted, and then  $p\text{-value} = 0.000$  ( $p < 0.05$ ) was obtained. The results of ANOVA analysis also showed P1 significant differences of the average (mean) value of MMP8 variables in the groups ( $p = 0.000$ ) and then Tukey HSD to know the difference of MMP8 among those groups.

It is known that there was significant increase in MMP8 expression of Group P1,  $p < 0.05$  (see Table 2), than in that of Group P2 and Group Po. It then indicates that the induction of PgLPS in the periapical tissues could affect the increasing of MMP8 (Matsui et al., 2011; Kiili et al., 2002). It is because in inflammation condition induced by LPS on the periapical tissue lead to the recruitment of polymorph nuclear leukocytes (PMNs) to the site. LPS by Toll like receptor 2 (TLR2) and Toll like receptor 4 (TLR4) activated macrophage while in the periapical tissue; TLR 4 is more dominant than TLR 2. Domination TLR4 gave different impact for periapical tissue. While in the periodontitis marginalis, TLR2 more dominant give inflammation process more dominant. But in the periodontitis apicalis while TLR4 more dominant, give bone resorption process more dominant by osteoclast activation. Signaling TLR4 by IRAK pathway will releasing  $\text{NF}_k\text{B-I}_k\text{B}$  then  $\text{NF}_k\text{B}$  became active and get in macrophage nucleus cell. Proliferation process in the nucleus cell will expression cytokin like IL-8, IL-1 and  $\text{TNF}\alpha$  (Shin et al., 2002).  $\text{TNF}\alpha$  and IL-6 will induce bone marrow leucocytosis, while IL-8 as chemotactic neutrophil factor will arrange leucocytes to lesion. Releasing  $\text{TNF}\alpha$  will increase e-selectin production and MMP production. MMPs as proteolytic enzyme make collagen degradation in the matrix extracellular and basal membrane component. That is why periapical tissue gets degradation at matrix extracellular.

IL-1 also make monocyte decreased by VCAM and monocyte expression growth factor especially  $\text{TGF}\beta 1$  which keep bone remodeling balance.  $\text{TGF}\beta 1$  lead collagenase by fibroblast proliferation as host response balances injury by MMP8.

$\text{TNF}\alpha$  also activate macrophage by protein kinase A pathway and protein kinase B which will activate osteoblast to RANKL expression by TRAF6 make osteoclast mature and lead periapical bone resorption.

11 The activation mechanisms in vivo are not yet completely understood. The onset of collagen destruction in periodontitis is caused by the action of

collagenases, which are a subgroup of MMPs. This is because MMP8 serves as a stimulus factor of osteoclast. MMP8 does not only stimulate the migration of preosteoclast toward the bone surface that get resorption, but also enhances the maturation of osteoclast.

The stimulation of MMP expression by many growth factors and cytokines usually involves the activation protein-1 (AP-1) pathway. The extracellular stimulus activates the AP-1 transcription factor complexes to bind into the AP-1-binding site in the MMP gene stimulating MMP expression. AP-1 transcription factors regulate gene expression not only involved in development, differentiation and proliferation, but also in stress reactions, inflammation and tumor progression.

## CONCLUSIONS

MMP8 was also activated by the initial activator TAT2 (*tumor associated trypsin-2*) (Ala-Aho, 2002; Moilanen, 2003). This is the same with the research result conducted by Murakami (1998). Cellular mechanism that accompanies osteoclastic phase of bone resorption is osteoclast apoptosis followed by osteoblast chemo taxis, proliferation, and differentiation. The increasing of MMP8 expression increased bone damage factor, and accelerate the resorption process of damaged bone tissue. But the continuous expression of MMP8 weakened the differentiation of bone cells and the formation of mineralized nodule.

Therefore, some researchers assume that the precursors of osteoclast will get differentiation and will enhance the resorption of the periapical region when the expression of MMP8 is too fast.

## RECOMMENDATION

The study hopes that further research will open up opportunities to take advantage of MMP8 as a potential therapeutic for inflammation that would suppress the occurrence of resorption in periapical tissues and as diagnostic kit for indicator successful of root canal treatment.

## LITERATURE CITED

- 21  
Ala-Aho, R.  
2002 *Human collagenase-3 (MMP-13) in tumor growth and invasion.* Dissertation. Turku: University of Turku.



- 8  
Coats, S. R., Pham, T. T. T., Bainbridge, B. W., Reife, R. A., & Darveau, R. P.  
2005 *MD-2 mediates the ability of tetra-acylated and penta-acylated lipopolysaccharides to antagonize Escherichia coli lipopolysaccharide at the TLR4 signaling complex.* The Journal of Immunology, 175(7), 4490-4498. Retrieved on April 20, 2014 from <http://goo.gl/BBzdQf>
- 23  
Cohen, S. & Burns, C.R.  
2002 *Pathways of the pulp*, 8<sup>th</sup> ed. California: Mosby, p: 203, 690, 692, 693 696.
- 14  
Jaana A, Mukaiyama A, Itoh Y, Nagase H, Thogersen IB, Enghild JJ, Sasaguri Y, Mori Y.  
2003 *Degradation of interleukin 1IL-1 by matrix metalloproteinases.* J BiolChem; 271: 14657-14660
- 10  
Kiili, M., Cox, S.W., Chen, H.W., Wahlgren, J., Maisi, P., Eley, B.M., Salo, T. & Sorsa, T.  
2002 *Collagenase-8 (MMP-8) and collagenase-3 (MMP-13) in adult periodontitis: molecular forms and levels in gingival crevicular fluid and immunolocalization in gingival tissue.* J ClinPeriodontol 2002; 29: 224-232.
- 2  
Matsui, H., Yamasaki, M., Nakata, K., Amano K. & Nakamura, H.  
2011 *Expression of MMP8 and MMP13 in the development of periradicular lesions.* International Endodontic Journal. 44. 739-745. Retrieved on April 20, 2014 from <http://goo.gl/pZaHXn>
- 1  
Moilanen, M., Sorsa, T., Stenman, M., Nyberg, P., Lindy, O., Vesterinen, J., Paju, A., Konttinen, Y.T., Stenman, U.H. & Salo, T.  
2003 *Tumor-associated trypsinogen-2 (trypsinogen-2) activates procollagenases (MMP-1, -8, -13) and stromelysin-1 (MMP-3) and degrades type I collagen.* Biochemistry 2003; 42: 5414-5420.
- Murakami, T. & Yamamota, M.  
1998 *Transforming growth factor  $\beta$ 1 increases mRNA levels of osteoclastogenesis inhibitory factor in osteoblastic/stromal cells and inhibits the survival of*

*murine osteoclast-like cells*. Biochem Biophys Res Commun. 252;747-752. Retrieved on April 20, 2014 from <http://goo.gl/pvoL2i>

6

Nair, P.N.R.

2004 *Pathogenesis of apical periodontitis and the causes of endodontic failures*. Crit Rev. Oral Biol. Med. 15:348-81. Retrieved on April 20, 2014 from <http://goo.gl/Hx8Y4c>

Quinn, J. M., Itoh, K., Udagawa, N., Häusler, K., Yasuda, H., Shima, N., ... & Gillespie, M. T.

2001 *Transforming growth factor  $\beta$  affects osteoclast differentiation via direct and indirect actions*. Journal of Bone and Mineral Research, 16(10), 1787-1794. Retrieved on April 20, 2014 from <http://goo.gl/rxkJmh>

Shin, S.J., Lee, J.I., Baek, S.H. & Lim, S.S.

2002 *Tissue levels of matrix metalloproteinases in pulps and periapical lesions*. J Endod 28:313-315

4

Siqueira Jr, J. F., & Rôças, I. N.

2007 *Bacterial pathogenesis and mediators in apical periodontitis*. Brazilian dental journal, 18(4), 267-280. Retrieved on April 20, 2014 from <http://goo.gl/M0AybT>

22

Stashenko, P.

2002 *Interrelationship of dental pulp and apical periodontitis*. In: Hargreaves KM, Goodis HE, eds. Seltzer and Bender's dental pulp. Chicago: Quintessence Publishing Co, Inc, 2002:389-409. Retrieved on April 20, 2014 from <http://goo.gl/JyjkUG>

Stashenko, P., Yu, S. M. & Wang, C. Y.

2007 *Porphyromonasgingivalis Lipopolysaccharide Contains Multiple Lipid A Species That Functionally Interact with Both Toll-Like Receptors 2 and 4*. Journal of Endodontic. 2007:18(9):422-426

3

Tripton, D.A., Dabbous, M.K.

1998 *Autocrine transforming growth factor beta stimulation of extracellular matrix production by fibroblast from fibrotic human gingiva*. J Periodontol 1998;69;609-619. Retrieved on April 20, 2014 from <http://goo.gl/>

Oh6iEZ

Utomo, H.

2009 *Mekanisme imunoneuromodulasi Terapi "Assisted Drainage" pada reaksi tikus alergi yang terpapar Lipopolisakarida Porphyromonas gingivalis.* Tesis. 2009

20

Wahlgren, J.

2003 *Matrix Metalloproteinases in pulpitis, chronic apical periodontitis and odontogenic, Jaw cysts.* Dissertation. Retrieved on April 20, 2014 from <http://goo.gl/aPx3TR>

Wang, Q., McLoughlin, R.M., Cobb, B.A., Charell-Dennis, M. & Zaleski, K.J.

2006 *A bacterial carbohydrate links innate and adaptive responses through toll-like receptor 2.* J Exp Med 2006;203(13):2853-63. Retrieved on April 20, 2014 from <http://goo.gl/pIA3bz>



# The Role of Matrix Metalloproteinase-8 Enhance Periapical Bone Resorption in Chronic Apical Periodontitis

## ORIGINALITY REPORT

17%

SIMILARITY INDEX

13%

INTERNET SOURCES

12%

PUBLICATIONS

6%

STUDENT PAPERS

## PRIMARY SOURCES

- 1** Wuyi Kong, Michael T. Longaker, H. Peter Lorenz. "Cyclophilin C-associated Protein Is a Mediator for Fibronectin Fragment-induced Matrix Metalloproteinase-13 Expression", *Journal of Biological Chemistry*, 2004  
Publication 1%
- 2** Marlos Barbosa-Ribeiro, Rodrigo Arruda-Vasconcelos, Adriana de-Jesus-Soares, Alexandre Augusto Zaia et al. "Effectiveness of calcium hydroxide-based intracanal medication on infectious/inflammatory contents in teeth with post-treatment apical periodontitis", *Clinical Oral Investigations*, 2018  
Publication 1%
- 3** Xiao, S.. "Refinement of the Locus for Autosomal Dominant Hereditary Gingival Fibromatosis (GINGF) to a 3.8-cM Region on 2p21", *Genomics*, 20000915  
Publication 1%
- 4** Submitted to Egas Moniz Cooperativa de Ensino Superior CRL  
Student Paper 1%
- 5** John A. Yee, Lin Yan, Juan C. Dominguez, Elizabeth H. Allan, T. John Martin. "Plasminogen-dependent activation of latent transforming growth factor beta (TGF?) by growing cultures of osteoblast-like cells", *Journal of Cellular Physiology*, 1993 1%

---

6	<a href="http://perfendo.org">perfendo.org</a> Internet Source	1%
7	Salzman, N.H.. "Paneth cells, defensins, and the commensal microbiota: A hypothesis on intimate interplay at the intestinal mucosa", <i>Seminars in Immunology</i> , 200704 Publication	1%
8	<a href="http://www.nutrinfo.com">www.nutrinfo.com</a> Internet Source	1%
9	<a href="http://unair.ac.id">unair.ac.id</a> Internet Source	1%
10	Marko Määttä. "Tear fluid levels of MMP-8 are elevated in ocular rosacea—treatment effect of oral doxycycline", <i>Graefes Archive for Clinical and Experimental Ophthalmology</i> , 08/2006 Publication	1%
11	Rai, Balwant, Jasdeep Kaur, and Maria Catalina. "Bone mineral density, bone mineral content, gingival crevicular fluid (matrix metalloproteinases, cathepsin K, osteocalcin), and salivary and serum osteocalcin levels in human mandible and alveolar bone under conditions of simulated microgravity", <i>Journal of Oral Science</i> , 2010. Publication	1%
12	<a href="http://iaiest.com">iaiest.com</a> Internet Source	1%
13	Submitted to Hofstra University Student Paper	1%
14	<a href="http://scholarcommons.usf.edu">scholarcommons.usf.edu</a> Internet Source	1%
15	<a href="http://uad.portalgaruda.org">uad.portalgaruda.org</a> Internet Source	1%

---

		1%
16	<a href="http://crobm.iadrjournals.org">crobm.iadrjournals.org</a> Internet Source	1%
17	<a href="http://www.ashitabaplant.com">www.ashitabaplant.com</a> Internet Source	1%
18	Chinnathambi, Sathivel, and Jackie R. Bickenbach. "Human Skin and Gingival Keratinocytes Show Differential Regulation of Matrix Metalloproteinases When Combined With Fibroblasts in 3-Dimensional Cultures", <i>Journal of Periodontology</i> , 2005. Publication	1%
19	<a href="http://www.ektodermaldisplazi.com">www.ektodermaldisplazi.com</a> Internet Source	1%
20	Submitted to University of Bristol Student Paper	<1%
21	<a href="http://www.hytti.uku.fi">www.hytti.uku.fi</a> Internet Source	<1%
22	<a href="http://www.academicjournals.org">www.academicjournals.org</a> Internet Source	<1%
23	<a href="http://www.budubai.ae">www.budubai.ae</a> Internet Source	<1%
24	<a href="http://peterattiamd.com">peterattiamd.com</a> Internet Source	<1%
25	<a href="http://www.innspub.net">www.innspub.net</a> Internet Source	<1%
26	<a href="http://www.fkh.unair.ac.id">www.fkh.unair.ac.id</a> Internet Source	<1%
27	<a href="http://repository.nihon-u.ac.jp">repository.nihon-u.ac.jp</a> Internet Source	<1%



29

Iwai, Shinichi, Ahmad Aljada, Akira Higa, Takako Nakanishi-Ueda, Shohei Fukuda, Maki Kamegawa, Shigehiro Iwabuchi, Toshihiko Ueda, Sergio Caballero, Richard Browne, Aqeela Afzal, Maria Grant, Hajime Yasuhara, Ryohei Koide, Katsuji Oguchi, Paresh Dandona, and Donald Armstrong. "Activation of AP-1 and Increased Synthesis of MMP-9 in the Rabbit Retina Induced by Lipid Hydroperoxide", *Current Eye Research*, 2006.

Publication

&lt;1%

30

J. Camilleri. "Dynamic sealing ability of MTA root canal sealer : Dynamic sealing ability of MTA", *International Endodontic Journal*, 07/14/2010

Publication

&lt;1%

31

S Chen, H Lei, Y Luo, S Jiang, M Zhang, H Lv, Z Cai, X Huang. "Micro-CT analysis of chronic apical periodontitis induced by several specific pathogens", *International Endodontic Journal*, 2019

Publication

&lt;1%

Exclude quotes

On

Exclude matches

&lt; 5 words

Exclude bibliography

Off

# The Role of Matrix Metalloproteinase-8 Enhance Periapical Bone Resorption in Chronic Apical Periodontitis

---

## GRADEMARK REPORT

---

FINAL GRADE

**/100**

GENERAL COMMENTS

**Instructor**

---

PAGE 1

---

PAGE 2

---

PAGE 3

---

PAGE 4

---

PAGE 5

---

PAGE 6

---

PAGE 7

---

PAGE 8

---

PAGE 9

---

PAGE 10

---