

# Management of traumatic immature teeth in maxillary incisor by aesthetic approach

*by* Yusuf Bagus Pamungkas

---

**Submission date:** 09-Feb-2019 01:32PM (UTC+0800)

**Submission ID:** 1075370347

**File name:** TINI\_III-pages-301-305.pdf (398.91K)

**Word count:** 2768

**Character count:** 14308

# Management of traumatic immature teeth in maxillary incisor by aesthetic approach

Yusuf Bagus Pamungkas<sup>1</sup>, Dian Agustin Wahjuningrum<sup>2</sup>, Laksmiari Setyowati<sup>3</sup>

<sup>1</sup>Resident of Conservative

<sup>2,3</sup>Staff Department of Conservative

Faculty of Dentistry, Airlangga University

Surabaya-Indonesia

## ABSTRACT

**Background:** Traumatic in immature teeth can lead to injury of the pulp and peri apical. Traumatic injury may disturb maturity process and stopping closure apex. Open apex results hermetic seal which became difficult reach it. The closure of root apex is very essential for success of the endodontic treatment. On the other side, traumatic induce bleeding and decomposition products can penetrate the dentinal tubules and stain the surrounding dentin and enamel. That condition may lead teeth discoloration and make an aesthetic problem. Until now the apical barrier formation and healing still challenging in root canal treatment. **Purpose:** The aim of this case reports is to overview the closure of root apex in permanent incisor using MTA and to inform the result of internal bleaching treatment with walking bleach technique on the anterior permanent tooth due to trauma. **Case:** 21 years old female patient went to the Dental Hospital Faculty of Dentistry Airlangga University. The patient wanted to remove the discoloration on her anterior maxillary tooth. This tooth has traumatic history 17 years ago. On radiographic examination showed incomplete root formation with wide open apices and root canal at the same tooth. **Case management:** Apexification with MTA was performed followed by thermoplasticized gutta percha obturation and internal bleaching procedure with walking bleach technique. The final restoration is composite resin restoration. **Conclusion:** MTA can be a valid option for apexification rather than calcium hydroxide and intrinsic discoloration due to traumatic injury can be treated with walking bleach technique.

**Key words:** Apexification, MTA, trauma, discoloration, internal bleaching

Korespondensi (correspondence) : Yusuf Bagus Pamungkas, Resident of Conservative, Faculty of Dentistry, Airlangga University, Jl. Mayjend Prof. Dr. Moestopo 47 Surabaya, Indonesia.

## INTRODUCTION

Tooth Aesthetic is an important thing for patient, one of it is the tooth color. The discoloration especially on the anterior can raise an aesthetic problem which psychologically influences the patient's confidence.

One of the main causes of the discoloration is trauma. Traumatic injury happens to immature teeth. It may disturb maturity process and stopping closure apex. If it happens, apexification is needed.

Apexification is a procedure to trigger the formation of apical calcific barrier to close the opened apex on the immature teeth with non

vital pulp. Therefore, the filling material can fill the root canal. <sup>1</sup> One of the best apexification materials nowadays is mineral trioxide aggregate (MTA). The usage of MTA for apexification will shorten the treatment time and the result is more satisfying.<sup>2, 3</sup> One way to solve the traumatic teeth which have the discoloration is by bleaching. Bleaching is a way to restore the color to match the natural color closely through the chemical process in order to restore the patient's aesthetic.

To overcome the discoloration caused by pulp necrosis, bleaching intracoronal using walking bleach which happens in the pulp can be done. <sup>4</sup> this technique is chosen because it

needs less time, less cost, but gives more comfort and safety for the patient.<sup>5</sup>

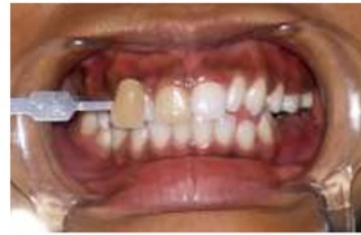The purpose of this case report is to view the closure of permanent incisor root apex using MTA and to inform the treatment result of bleaching internal treatment using walking bleach technique on the permanent anterior because of trauma.

## CASE REPORT

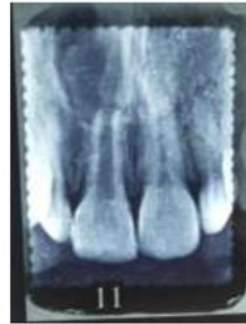21 years old female patient, a private company employee went to the Dental Hospital Faculty of Dentistry Airlangga University. The patient wanted to remove the discoloration on her anterior maxillary tooth. She felt unconfident every time she smiled. This tooth has traumatic history 17 years ago when she was in elementary school. Once she fell and hit the wall; she didn't feel hurt but one of her anterior a little bit broken. She wanted her tooth to be treated so that its color the same as its surrounding teeth. (Picture 1).

On the intraoral examination was seen blackish discoloration around the crown of tooth 11. Based on shade guide Vita 3D, tooth discoloration 5M 2 occurred on tooth 11. The occlusion examination shown normal occlusion with 2mm and overbite 2mm. The percussion and palpation were negative, there was no mobility, and the tissues around the tooth showed no abnormalities. According to vitality test, tooth 11 was non vital. There was no caries or fracture either on the crown or the root. On the dental periapical on tooth 11 was seen radiolucency and also unclosed the tip of apical (Picture 2). The clinical diagnosis for 11 tooth was discoloration which was caused by pulp necrosis and was accompanied by an open apex.

Dental care plan for 11 in this case was root canal treatment and apexification with MTA, after that internal bleaching treatment was performed using the walking bleach technique. For the final restoration was used composite resin restoration on the palate.



Picture 1. Clinical Features tooth 11 before the treatment.



Picture 2. Radiographic initial overview of tooth 11

## THE CASE MANAGEMENT

On the first visit, it was done subjective and objective examinations, intraoral clinical photos and radiographic photos to support the diagnosis and treatment plan. Then the patient was explained about the cause of the discoloration of the teeth, stage of treatments which would be carried out, the results which could be achieved, the possibility of rediscoloration and side effects which could occur, as well as the costs involved.

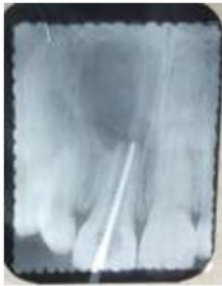After the patient understood and agreed on the treatment plan procedures, the patient was asked to sign a letter of medical consent (informed consent).

The tooth which would be bleached, was photographed to record the initial state of the tooth. In clinical photos were seen blackish discoloration around the crown of the tooth 11. Then it matched with the Vita 3D shade guide, and it was obtained that the initial color of tooth 11 was 5M2 and the color of adjacent teeth was 1M1.

The next step was the opening of the pulp chamber and disposal of the dental pulp chamber roof on tooth 11 using endo access bur to make the access cavity in the tooth. Then its



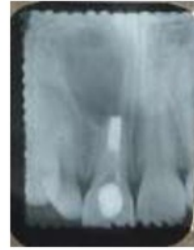
length was measured using an apex locator with file no 70. In the photo Diagnostic Wire Photo (DWP) was obtained the working length of tooth 11 = 20mm (Picture 3).



**Picture 3. The Overview of Diagnostic radiographic Wire Photo (DWP)**

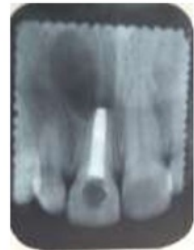The preparation of root canals on tooth 11 using k-file needle up to number 110 with a pull stroke technique. Each turn of the files was done the irrigation of 2.5% NaOCl and sterile aquades to remove necrotic tissue and dentin powder that was in the root canal using a syringe and irrigation needle 30G side vended. After the the root canal was dried with sterile paper points and dressing was done using Ca (OH) 2 with the brand Metapaste, then the cavity was given cotton and filled temporarily with Cavit.

At the second visit (1 week after the first visit), the check up was done. At the check up, patient didn't have any complaints, temporary filling was still good, no exudate and blood in the root canal, and percussion was negative. Then, dressing materials Ca (OH) 2 was cleaned using irrigation materials 2.5% NaOCl until clean and dried by sterile paper point. To prevent the filling of root canal in the tip of apical was out, then the closure of the tip of apical was done with Mineral Trioxide Aggregate provision (MTA) brand ProRoot MTA (Dentsply) with the consistency of wet sand at a ratio of 1: 1 (mixed with sterile aquades). Application of MTA into the channel with the help of the plugger, with the thickness of MTA  $\pm$  2mm on apical of tooth 11. Then it was closed with sterile cotton which was moistened with sterile aquades and placed in the orifice of filled temporarily with Cavit. After that photo radiographic applications MTA on tooth 11 was taken (Picture 4).



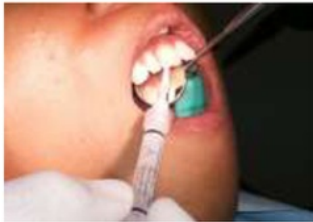**Picture 4. The overview of radiographic applications MTA on third apical of tooth 11**

On the third visit (2 weeks later), apical dental examination on tooth 11 to make sure the MTA had hardened. Then the remaining root canal was filled using gutta percha thermoplastis back-gill (VDW, Beefill 2 in 1, USA) with a resin sealer (Top Seal), then the cavity was given cotton and filled temporarily with Cavit. This was followed by radiographic photo to ensure that the root canal was filled perfectly and looks hermetic (Picture 5).



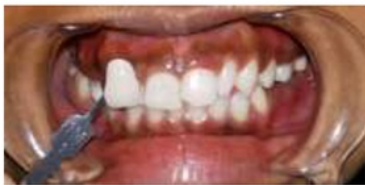**Picture 5. The radiographic overview of gutta-percha backfill obturation thermoplastis.**

On the fourth visit, the root canal obturation post control was done and there were no complaints. Then, it was followed by internal bleaching procedures with the walking bleach technique. the next treatment step was the reduction of gutta-percha on tooth 11 along 2mm under servical tooth then it was closed with a GIC at least 2mm above the gutta percha to prevent penetration of the bleaching material to the apical or out to the CEJ because it could lead to external resorption. After that entered the Opalescence Endo bleaching ingredient (Hydrogen Peroxide 35%), and then pressed toward ding = ding labial and closed cavity with GIC (Picture 6). The maximum bleaching effect was obtained approximately 24 hours after treatment, then the patient was instructed to return after 3-7 days to evaluate the results.



**Picture 6. application of bleaching materials Opalescence Endo**

After giving endo opalescence 35% hydrogen peroxide for 4 times (for 4 weeks), it was obtained the tooth color which matched with the teeth next to it; that was based on the Vita 3D shade guide color 1M1. Then the bleaching material was taken, the pulp chamber was cleaned and irrigated with saline then cavity on the palate was prepared for a permanent restoration. After that, the 35% phosphoric etching asthma (3M, ESPE) on the tooth cavity 11 for 15 seconds was given. Then it was rinsed, applied bonding material (XP Bond) and irradiated for 20 seconds. For the final restoration on tooth 11, composite resin restorations (3M Z350XT) was used because Then it was rinsed, applied bonding material (XP Bond) and irradiated for 20 seconds. For the final restoration on tooth 11, composite resin restorations (3M Z350XT) was used because after root canal treatment, the rest of tooth tissues was still quite a lot of , then resin composite irradiated for 20 seconds. Next, the finishing and polishing were done. On the next visit, after 2 months, post-treatment for control of internal bleaching was administered. On the subjective examination, was obtained the results that no complaints from the patient and she was very satisfied with the treatment results. While the objective examination was obtained that the color of tooth 11 did not change and matched the color of the 3D Vita shade guide 1M1. Composite filling was in good condition and gingiva around the tooth was normal (Picture 7).



**Picture 7. post-treatment of internal bleaching control (2 months)**

## DISCUSSION

Trauma or injury collision could cause discoloration on one or several teeth that could lead to the breaking down of the blood vessels in the tooth crown, bleeding as well as the lysis of erythrocytes. Iron product in hemoglobin joined with hydrogen sulfide which was a product of the bacteria to form iron sulfide, entered into the tubules and colored the dentin. When a tooth became necrotic, the discoloration would be more severe.<sup>6</sup>

Bleaching or tooth whitening was a way to return the tooth color change, until it was closed to the color of natural teeth through the chemical process. Bleaching could be done on vital or non-vital teeth which was discolored.

Discoloration of teeth due to trauma or necrosis could be belached with 95% success rate compared to the effect of the use of drugs or restoration.<sup>7</sup> Intrakorona Bleaching was done by walking technique bleach.<sup>4</sup> This techniques was chosen because visiting time was shorter, more efficient, more comfortable and safer for patient.<sup>5</sup>

Mechanism of peroxide bleach and non-peroxide was by entering through the intermediary of the enamel to the dentin tubules and oxidized the pigment in dentin, causing the color of the teeth become whiter. The process of teeth whitening was done based on the mechanism of the oxidation reaction. The stains found on enamel and dentine would be oxidized by the teeth whitening gel (hydrogen peroxide) which acted as a strong oxidator. This oxidator material had the ability to damage the color molecules, through its reaction with free oxygen which was released. This situation made the color became neutral and cause the bleaching effects.<sup>8</sup>

From the results of the vitality of the tooth 11 showed that non-vital tooth that need root canal treatment was carried out beforehand. In this case, it appeared that radiographic of the apical tio which was wide open so that it was necessary apexification used Mineral Trioxide Aggregate (MTA) to prevent overfilling of obturation material. Teeth with open apex could



be caused by trauma, caries or other pulp diseases. The absence of a natural constriction at the apical tip would make it difficult to control the obturation material, where the purpose of filling root canals on tooth with open apex was closing the channel which was big enough between the root canal system and periradicular tissues. this would provide a barrier so that the obturation material could be solidified.<sup>9</sup> After obturation, obturation materials was reduced to the depth of 2 mm to apical direction of the orifice then on it was given the base by using GIC as thick as 2 mm to prevent leakage of bleaching material to the periodontium. it also minimized the inflammation in the periodontium tissue and prevented the occurrence of cervical external resorption. <sup>5,10</sup>

In this case, opalescence 35% hydrogen peroxide endo was used because the gel was indicated for teeth which had discoloration, its easy application and its longer contact time with the tooth tissue which was longer so that the effects of bleaching teeth was better. In addition, the effectiveness of this material could be seen only in one visit because this material diffused into the enamel and dentin tubules due to its small molecular weight, ie 30g / mol.<sup>7,11,12</sup>

On the anterior teeth which had pulp necrosis due to intrinsic discoloration, walking bleach method using 35% hydrogen peroxide gel gave satisfactory results due to its easy application and shorter time of visit as well as safety and comfort for the patient. Buttke said that 2 of 3 patient with internal bleaching treatment, having stable color for nearly 16 years and without any internal or eksternal resorption.<sup>13</sup>

## CONCLUSION

Based on the above discussion it could be concluded that root canal treatment followed by apexification on the tooth with open apical and internal bleaching using walking bleach method in the case of intrinsic discoloration due to pulp necrosis could give good results for patient satisfaction in terms of aesthetic. Prognosis in this case was good because the patient was cooperative and the tooth condition was possible to be treated.

## 1 REFERENCES

1. Rafter M. Apexification: a review. *Dentl Traumatology* 2005; 21 : 1-8
2. Maroto M, Barberia E, Planells P, Vera V. Treatment of a non-vital immature incisor with mineral trioxide aggregate (MTA). *Dental Traumatology* 2003; 19: 165-9
3. El-Meligy OA, Avery DR. Comparison of apexification with mineral trioxide aggregate and calcium hydroxide. *Pediatric Dentistry* 2006; 28: 248-53
4. Greenwall L. *Bleaching techniques in restorative dentistry*. New York: MartinDunitz Ltd; 2002.
5. Retnowati E. Perawatan walking bleach pada gigi incisivus sentralis kiri maksila disklorasi intrinsik akibat nekrosis pulpa. *Maj Ked gigi Juni* 2009; 16(1): 91.
6. Abbott P, Heah SY. Internal bleaching of teeth: an analysis of 255 teeth. *Australia Dental journal* 2009; 54: 326-33.
7. Deliperi S. Clinical evaluation of non-vital tooth whitening and composite resin restorations: Five-year results. *The European J of Esthetic Dentistry* 2008; 3: 14-25
8. Tarigan R. *Perawatan pulpa gigi (Endodonti)*. Cetakan I. Jakarta: Widya Medika; 1994.
9. Fellippe WT, Fellippe MC, Rocha MJ. The effect of MTA on the apexification and periapical healing of teeth with incomplete root formation. *Int End J* 2006; 39: 2-9.
10. Plotino G, Buono L, Grande NM, Pameijer CH, Somma F. Non vital tooth bleaching: A review of the literature and clinical procedures. *JOE* 2008; 34Z(4): 394-407.
11. Dietschi D. Non vital bleaching: General considerations and report of two failure cases. *The European J of Esthetic Dentistry* 2006; 1 : 52-61.
12. Brosur produk Opalescence Endo, Ultradent product,inc.
13. Buttke TM. Internal bleaching of non vital teeth. *Int Journal of Endodontics* 2009; 32: 376-78.

# Management of traumatic immature teeth in maxillary incisor by aesthetic approach

## ORIGINALITY REPORT

12%

SIMILARITY INDEX

10%

INTERNET SOURCES

9%

PUBLICATIONS

5%

STUDENT PAPERS

## PRIMARY SOURCES

1	<b>bujod.in</b> Internet Source	2%
2	<b>banglajol.info</b> Internet Source	1%
3	<b>2medicalcare.com</b> Internet Source	1%
4	<b>www.jcpsp.pk</b> Internet Source	1%
5	<b>journal.unair.ac.id</b> Internet Source	1%
6	<b>www.simonedeliperi.it</b> Internet Source	1%
7	<b>TÜRK, Tamer, ELEKDAĞ-TÜRK, Selma, KOÇAK, Mustafa Murat, KOÇAK, Sibel and ÇAKMAK ÖZLÜ, Fethiye. "Comparison of the Shear Bond Strengths of ", AVES Yayıncılık, 2015.</b> Publication	1%

8	<a href="http://edoc.site">edoc.site</a> Internet Source	1%
9	Gupta, Saurabh K., and Payal Saxena. "Evaluation of patient satisfaction after non-vital bleaching in traumatized discolored intact anterior teeth", Dental Traumatology, 2014. Publication	1%
10	"Full Issue PDF", Operative Dentistry, 2018 Publication	<1%
11	<a href="http://amaliapradana.blogspot.com">amaliapradana.blogspot.com</a> Internet Source	<1%
12	<a href="http://etheses.whiterose.ac.uk">etheses.whiterose.ac.uk</a> Internet Source	<1%
13	<a href="http://documents.mx">documents.mx</a> Internet Source	<1%
14	<a href="http://www.ijarbs.com">www.ijarbs.com</a> Internet Source	<1%
15	<a href="http://docobook.com">docobook.com</a> Internet Source	<1%
16	<a href="http://www.i-scholar.in">www.i-scholar.in</a> Internet Source	<1%
17	Jale Tanalp. "Comparison of the fracture resistance of simulated immature permanent teeth using various canal filling materials and	<1%



fiber posts : Fracture resistance of immature teeth", Dental Traumatology, 12/2011

Publication

---

18

Siqueira, J.F.. "Bacterial Reduction in Infected Root Canals Treated With 2.5% NaOCl as an Irrigant and Calcium Hydroxide/Camphorated Paramonochlorophenol Paste as an Intracanal Dressing", Journal of Endodontics, 200706

Publication

---

<1%

---

Exclude quotes    On  
Exclude bibliography    Off

Exclude matches    < 5 words

# Management of traumatic immature teeth in maxillary incisor by aesthetic approach

---

GRADEMARK REPORT

---

FINAL GRADE

**/100**

GENERAL COMMENTS

**Instructor**

---

PAGE 1

---

PAGE 2

---

PAGE 3

---

PAGE 4

---

PAGE 5

---