

# Oral Phenazopyridine HCl for Ureter Orifice Identification

*by* Tarmono Tarmono

---

**Submission date:** 22-Apr-2019 03:04PM (UTC+0800)

**Submission ID:** 1116788863

**File name:** Oral\_Phenazopyridine\_HCl\_for\_Ureter\_Orifice\_Identification.pdf (5.61M)

**Word count:** 2739

**Character count:** 16208

## ORAL PHENAZOPYRIDINE HCL FOR URETER ORIFICE IDENTIFICATION AND RETROGRADE STENTING

<sup>1</sup>Gumilar, Ogi Bahaurini; <sup>2</sup>Soebadi, Doddy M; <sup>3</sup>Djojodimedjo, Tarmono; <sup>4</sup>Askandar, Brahmana; <sup>5</sup>Pudjirahardjo, Widodo J.

<sup>1</sup>Department of Urology, Faculty of Medicine/Airlangga University, Soetomo General Hospital, Surabaya.

<sup>2</sup>Department of Obstetry and Gynecology, Faculty of Medicine/Airlangga University, Soetomo General Hospital, Surabaya.

<sup>3</sup>Faculty of Public Health, Airlangga University, Surabaya.

### ABSTRACT

**Objectives:** To compare successful identification of the ureteral orifice in cervical cancer patients who received oral phenazopyridine and to analyze the correlation between hydronephrosis and success rate for retrograde stenting. **Material & Method:** This was a comparative experimental study, using oral phenazopyridine HCL prior to cystoscopy to identify ureteral orifices of cervical cancer patients and to perform retrograde stenting. Forty patients provided consent to enroll in this study. Mean age was  $49.2 \pm 5.16$  years. Thirty-four out of 40 samples was confirmed as squamous cell carcinoma type. **Results:** Chi-square test demonstrated no significant differentiation in finding ureteral orifice between treatment and control group on stage 3B ( $p = 0.408$ ). However, result shown conversely on stage 4A ( $p = 0.046$ ). There was no significant disparity in conducting retrograde stenting between treatment and control group on stage 2B and 3B ( $p = 0.221$  and  $p = 0.197$ ). There was no significant correlation between hydronephrosis grade and retrograde stenting on control group ( $p = 0.144$ ). **Conclusion:** Administration of oral phenazopyridine HCL in cervical cancer patients increased success for ureteral orifice identification and retrograde stenting, but not statistically significant. There is no correlation between hydronephrosis with successful retrograde stenting.

**Keywords:** Cervical cancer, hydronephrosis, phenazopyridine HCL, ureteral orifice, retrograde stenting.

### ABSTRAK

**Tujuan:** Membandingkan keberhasilan identifikasi muara ureter dan pemasangan retrograde stenting pada pasien kanker mulut rahim yang mendapat phenazopyridine hcl per oral dan menganalisis hubungan gradasi hidronefrosis dengan keberhasilan pemasangan retrograde stenting. **Bahan & cara:** Penelitian eksperimental jenis uji komparasi dengan mempelajari pemberian phenazopyridine HCL per oral pada saat sistoskopi untuk identifikasi muara ureter pada pasien keganasan mulut rahim, kemudian melakukan pemasangan DJ stent secara retrograde pada muara ureter yang teridentifikasi. 40 pasien bersedia mengikuti penelitian dengan rerata usia  $49.2 \pm 5.16$  tahun. 34 diantaranya dengan hasil PA squamous cell carcinoma. **Hasil:** Pada stadium 3B, menggunakan uji chi-square tidak didapatkan perbedaan yang signifikan dalam identifikasi muara ureter antara kelompok yang mendapat phenazopyridine dengan yang tidak ( $p = 0.408$ ), tetapi hasil sebaliknya ditemukan pada stadium 4A ( $p = 0.046$ ). Di stadium 2B dan 3B juga tidak didapatkan perbedaan yang signifikan dalam keberhasilan pemasangan retrograde stenting antara yang mendapat phenazopyridine dengan yang tidak ( $p = 0.221$  dan  $p = 0.197$ ). Serta tidak adanya hubungan antara gradasi hidronefrosis dengan keberhasilan pemasangan retrograde stenting pada kelompok yang tidak mendapat phenazopyridine ( $p = 0.144$ ). **Simpulan:** Pemberian phenazopyridine HCL per-oral pada pasien keganasan mulut rahim meningkatkan keberhasilan identifikasi muara ureter dan meningkatkan keberhasilan pemasangan retrograde stenting, namun secara statistik tidak signifikan. Tidak dijumpai adanya hubungan antara gradasi hidronefrosis dengan tingkat keberhasilan pemasangan retrograde stenting.

**Kata kunci:** Kanker mulut rahim, hidronefrosis, phenazopyridine HCL, muara ureter, retrograde stenting.

Correspondence: Gumilar, Ogi Bahaurini; c/o: Department of Urology, Faculty of Medicine/Airlangga University, Soetomo General Hospital Surabaya. Jl. Mayjen. Prof. Dr. Moestopo 6-8 Surabaya 60286. Office: (031) 5501318; Fax: (031) 5024971. Mobile phone: 081330791299. Email: urobaya.ogi@gmail.com.

## INTRODUCTION

Cervical cancer is the most frequent cancer among females in Indonesia.<sup>1</sup> About 3638 new cases were diagnosed at Soetomo General Hospital Surabaya in 2010.<sup>2</sup> 42.4% is in stage 3B that requires urinary diversion.<sup>3</sup> Not more than 59% of all cervical cancer cases associated with hydronephrosis was successful for retrograde stenting.<sup>4</sup>

Hydronephrosis in patients with cervical cancer may be secondary to direct tumor invasion, extrinsic compression or encasement by metastatic retroperitoneal or pelvic lymph nodes. Ureteral obstruction caused by malignancy on literatures was referred to as Malignant Ureteral Obstruction (MUO).<sup>5,6</sup>

Progressive obstructive uropathy may likely lead to clinical manifestations such as uremia, electrolyte imbalances and persistent urinary tract infections, if obstruction is not by passed.<sup>7</sup> Deterioration of kidney function will prevent adequate management of cervical cancer cases.

Urinary diversion managed by retrograde insertion of an indwelling ureteral stent, known as Double J (DJ) stent, is applied in Department of Urology, Soetomo General Hospital Surabaya.<sup>4</sup>

Complexities frequently occurred were in identification of ureteral orifice.

Therefore, this study used Phenazopyridine HCL 200 mg given orally once prior to cystoscopy to compare the success rate on identifying ureteral orifice and retrograde stenting in cervical cancer cases between treatment and control groups and to analyze the correlation between hydronephrosis grade with ureteral orifice identification success rate. Urine discoloration effect was required for diagnostic tool.

## OBJECTIVE

To compare successful identification of the ureteral orifice in cervical cancer patients who received oral phenazopyridine and to analyze the correlation between hydronephrosis and success rate for retrograde stenting.

## MATERIAL & METHOD

This was a comparative experimental study using Phenazopyridine HCL orally prior to cystoscopy to identify ureteral orifice on cervical cancer patients and to perform retrograde stenting.

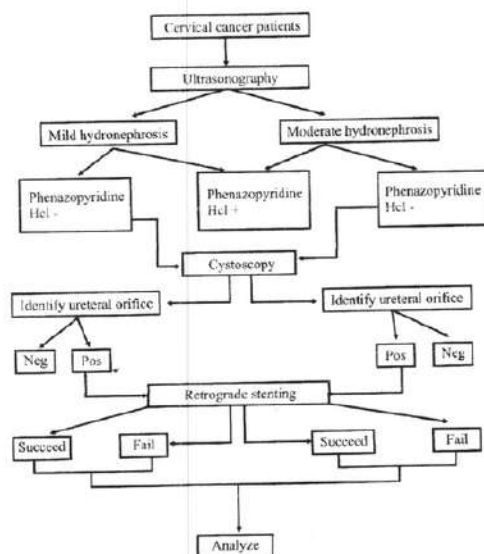


Figure 1. Research pathway.

All women who had histologically proven carcinoma of the cervix on stage 2B-4A, associated with mild or moderate hydronephrosis and agreed for retrograde stenting in the Soetomo General Hospital Surabaya between March and August 2013 were included in the study.

Forty subjects included in the study were classified as mild or moderate hydronephrosis, then each were randomly allocated into treatment and control groups. Samples underwent cystoscopy to identify ureteral orifice and upon successful identification DJ stents was inserted in retrograde fashion.

Four hours prior to cystoscopy, each of 20 samples took 200 mg of phenazopyridine HCL. Orange urine discoloration was found in all the samples but ureteral orifices were recognized in 13 samples.

Mean age of treatment group was  $47.50 \pm 3.22$  years, the youngest and the oldest were 41 and 52 years, respectively. Mean age of control group was  $50.90 \pm 7.10$  years, the youngest and the oldest were 40 and 64 years, respectively. P value was  $> 0.05$  showing insignificant age difference.

Mean creatinine serum pre operative on treatment group was  $2.02 \pm 2.24$  mg/dl, the lowest and the highest were 0.7 and 6.9 mg/dl, respectively. In control group was  $3.49 \pm 3.20$  mg/dl, the lowest and the highest were 0.5 and 9.2 mg/dl, respectively. P value was  $> 0.05$  presenting insignificant creatinine value difference.

There were 34 (85%) samples with squamous cell carcinoma, 4 with adenocarcinoma and 2 samples small cell carcinoma of the cervix. Of these 40 samples, treatment group consisted of 16 samples (80%) with squamous cell carcinoma and

**Table 1.** Research characteristics.

Characteristic	n	Min value	Max value	Mean	P value
Age (year)					0.062
Phenazopyridine (+)	20	41	52	47.50	
Phenazopyridine (-)	20	40	64	50.90	
Creatinine pre op (mg/dl)					0.102
Phenazopyridine (+)	20	0.7	6.9	2.02	
Phenazopyridine (-)	20	0.5	9.2	3.49	
Pathology result					0.047
Squamous cell ca					
Phenazopyridine (+)	16	-	-	-	
Phenazopyridine (-)	18	-	-	-	
Adenocarcinoma					
Phenazopyridine (+)	4	-	-	-	
Phenazopyridine (-)	0	-	-	-	
Small cell ca					
Phenazopyridine (+)	0	-	-	-	
Phenazopyridine (-)	2	-	-	-	
Stage (pathology = SCC)					0.037
II b					
Ureteral orifice (+)	6	-	-	-	
Ureteral orifice (-)	0	-	-	-	
III b					
Ureteral orifice (+)	10	-	-	-	
Ureteral orifice (-)	14	-	-	-	
IV a					
Ureteral orifice (+)	2	-	-	-	
Ureteral orifice (-)	2	-	-	-	



4 with adenocarcinoma. While control group consisted of 18 samples (90%) with squamous cell carcinoma and 2 with small cell carcinoma. P value was 0.047 confirming significant divergence between treatment and control group.

## RESULTS

Of these 34 samples with squamous cell carcinoma, there were 6 samples with stage 2B, 24 with stage 3B and 4 with stage 4A. Success rates in recognizing ureteral orifices were 100%, 41.7%, 50%, respectively. P value was 0.037 statistically

showing correlation between cervical carcinoma stage and ureteral orifice finding (table 2).

P value was 0.408 stage 3B. This confirmed insignificant disparity between treatment and control group. However, P value was 0.046 in stage 4A and this confirmed statistically significant disparity in finding ureteral orifice.

Of 34 samples, 18 were successful in ureteral orifice identification and proceeded for retrograde stenting, this was expressed in table 3. Of these patients, 33.3% were in stage 2B that received phenazopyridine, 60% in stage 3B and 50% in stage 4A. Successful insertion rates in retrograde stenting

**Table 2.** Crosstab among stage, phenazopyridine, and ureteral orifice.

Stage			Ureteral orifice	
			Identifiable	Unidentifiable
2 B	Group 1	Count	2	
		% within phenazopyridine hcl	100.0%	
		% within ureteral orifice	33.3%	
	Group 2	Count	4	
		% within phenazopyridine hcl	100.0%	
		% within ureteral orifice	66.7%	
	Total	Count	6	
		% within phenazopyridine hcl	100.0%	
		% within ureteral orifice	100.0%	
3 B	Group 1	Count	6	6
		% within phenazopyridine hcl	50.0%	50.0%
		% within ureteral orifice	60.0%	42.9%
	Group 2	Count	4	8
		% within phenazopyridine hcl	33.3%	66.7.3%
		% within ureteral orifice	40.0%	57.10%
	Total	Count	10	14
		% within phenazopyridine hcl	41.7%	58.3%
		% within ureteral orifice	100.0%	100.0%
4 A	Group 1	Count	2	0
		% within phenazopyridine hcl	100.0%	.0%
		% within ureteral orifice	100.0%	.0%
	Group 2	Count	0	2
		% within phenazopyridine hcl	.0%	100.0%
		% within ureteral orifice	.0%	100.0%
	Total	Count	2	2
		% within phenazopyridine hcl	50.0%	50.0%
		% within ureteral orifice	100.0%	100.0%

Group 1: Received phenazopyridine HCL.

Group 2: Did not receive phenazopyridine HCL.

Non Significant:  $X^2 = 0.408$ ;  $p < 0.05$  (stage 3B).

Significant:  $X^2 = 0.046$ ;  $p < 0.05$  (stage 4A).

**Table 3.** Crosstab among stage, phenazopyridine, and retrograde stenting.

Stage			Retrograde stenting	
			Succeed	Fail
2 B	Group 1	Count	2	0
		% within phenazopyridine hcl	100.0%	.0%
	Group 2	Count	50.0%	.0%
		% within phenazopyridine hcl	50.0%	50.0%
	Total	Count	4	2
		% within phenazopyridine hcl	66.7%	33.3%
3 B	Group 1	Count	4	2
		% within phenazopyridine hcl	66.7%	33.3%
	Group 2	Count	80.0%	40.0%
		% within phenazopyridine hcl	25.0%	75.0%
	Total	Count	5	4
		% within phenazopyridine hcl	50.0%	50.0%
4 A	Group 1	Count	1	1
		% within phenazopyridine hcl	50.0%	50.0%
	Total	Count	1	1
		% within phenazopyridine hcl	50.0%	50.0%
		Count	1	1
		% within retrograde stenting	100.0%	100.0%

Group 1: Received phenazopyridine HCL. Group 2: Did not receive phenazopyridine HCL.  
Non Significant:  $X^2 = 0.221$ ;  $p < 0.05$  (stadium 2B). Non Significant:  $X^2 = 0.197$ ;  $p < 0.05$  (stadium 3B).

**Table 4.** Crosstab among phenazopyridine, hydronephrosis, and retrograde stenting.

Phenazopyridine HCL		Retrograde stenting	
		Succeed	Fail
Group 1 Mild hydronephrosis	Count	7	3
	% within hydronephrosis	70.0%	30.0%
	% within Retrograde stenting	100.0%	100.0%
	Total	7	3
Group 2 Mild hydronephrosis	Count	7	3
	% within hydronephrosis	70.0%	30.0%
	% within Retrograde stenting	100.0%	100.0%
	Total	7	3
Moderate hydronephrosis	Count	3	1
	% within hydronephrosis	75.0%	25.0%
	% within Retrograde stenting	100.0%	20.0%
	Total	3	1
Total	Count	0	4
	% within hydronephrosis	.0%	100.0%
	% within Retrograde stenting	.0%	80.0%
	Total	3	5
	Count	3	5
	% within Retrograde stenting	37.5%	62.5%
	Count	100.0%	100.0%
	% within Retrograde stenting	100.0%	100.0%

Group 2: Did not receive phenazopyridine (CC = 0.144;  $p < 0.05$ ).

were 66.7%, 50% and 50%, increasing in stage respectively.

There were 7 (38.9%) samples who underwent retrograde stenting successfully on treatment group, while 3 (16.7%) samples underwent retrograde stenting successfully on control group.

P value was 0.221 in stage 2B. This confirmed insignificant disparity between treatment and control group. P value was 0.197 in stage 3B and this also confirmed statistically insignificant difference in retrograde stenting.

Table 4 showed 10 samples (100%) with mild hydronephrosis and 7 (70%) out of 10 underwent retrograde stenting successfully in treatment group. There were 4 samples with mild hydronephrosis where 3 (75%) out of 4 experienced retrograde stenting successfully and 4 with moderate hydronephrosis where all of these 4 failed in stenting on control group.

P value was 0.144 confirming no statistically correlation between hydronephrosis gradation and retrograde stenting on control group.

Side effects were not discovered after 200 mg of phenazopyridine giving prior to cystoscopy. Urine was stained orange to red in all treated subjects (100%).

## DISCUSSION

Failure in recognizing ureteral orifice were caused by change in appearance and site of due to extravesical tumor, abdominal lymphnode enlargement and tumor infiltration into bladder associated with fragile and blocked ureteral orifice. Suarsana et al studied the same experience.<sup>4</sup>

There are 2 types of cervical carcinoma based on microscopic appearance of the cancer, squamous cell carcinoma accounts for 80-90% of all cervical cancers, with adenocarcinoma making up to 10-20%. Early stage squamous cell carcinoma may not present symptoms, later stage cancers can cause abnormal vaginal bleeding, increased vaginal discharge, pelvic pain or pain during sexual intercourse.<sup>10</sup> Small cell carcinoma is an uncommon variant of cervical carcinoma which, like lung small cell, is usually systemic in spread and has a much worse 5 year survival. All patients need urgent chemotherapy plus minus radiotherapy to the pelvis and para-aortic regions to improve both local and systemic control. Definitive surgery is not recommended and urgent referral is advised.<sup>11</sup> Cystoscopy is seldom productive in evaluating stage I and II cervical cancer patients. However, this exam

is helpful to define the integrity/invasion of the bladder.<sup>12</sup>

Common causes of retrograde stenting failure were distal ureteral stenosis, kinking, false route of guide wire, therefore losing track and misdirection to achieve DJ stent placement in the affected kidney despite successful insertion of guide wire. Distal compression contributed in this difficulty as well.

Kouba et al, and Chitale et al reported that the incidence of stent failure is significantly higher in case of extrinsic compression, particularly when accompanied by persistent hydronephrosis or recurrent episodes of pain. Retrograde insertion of ureteral stents ultimately fails in 16 to 58% of patients with obstruction due to malignancy. Mechanisms of stent occlusion have not been fully delineated but it is suspected that failure is related to the impairment of ureteral smooth muscle by extrinsic ureteral compression. This results in ureteral peristalsis dysfunction, which is necessary for urine propulsion even with a stent in place. Obstruction by malignancy of the distal ureter at the pelvic brim also predicts a high retrograde failure rate compared to obstruction at the renal pelvis or proximal ureter.<sup>7,13</sup>

Those with complications in identification of ureteral orifice and failure in retrograde stenting underwent urinary diversion by antegrade stenting, ureterocutaneostomy and percutaneous nephrostomy to bypass ureteral obstruction.

Obstructive uropathy secondary to involvement of the lower (pelvic) ureter by cervical malignancy can be a presenting clinical feature, or may develop in the later stages of the disease. The ureter is involved either by an extrinsic compression or mural infiltration or both. Radiotherapy to a primary tumor can lead to lower ureteric stricturing and upper tract obstruction as a result of ischemic fibrosis of the ureter. Such patients often present with either renal failure at primary presentation or indeed have a degree of renal insufficiency and unilateral/bilateral hydronephrosis detected during the course of their routine followup.<sup>11</sup>

Side effects were not present in all treatment groups during post operative observation. Single administration of very low therapeutic dose of phenazopyridine to achieve urine discoloration effect could be considered in this setting.

## CONCLUSION

Oral administration of phenazopyridine HCL in cervical cancer patients increase success for

1  
ureteral orifice identification and retrograde stenting, but not statistically significant. There is no correlation between hydronephrosis with a success retrograde stenting.

## REFERENCES

1. Aziz MF. Gynecological cancer in Indonesia. *Journal Gynecol Onco*. 2009; 20(1): 8-10.
2. Sundar S, Horne A, Kehoe S. Cervical Cancer. *BMJ Clinical Evidence*. 2008; 3: 818.
3. Data pasien kanker mulut rahim Poli Onkologi Ginekologi RSUD Dr. Soetomo Surabaya; 2010.
4. 1  
arsana IW, Socbadi DM. Profil penderita Malignant Ureteral Obstruction akibat kanker mulut rahim yang dirawat di RSUD Dr. Soetomo Surabaya 3  
ahun 2007 - 2009; 2012. p. 18-19.
5. Russo P. Urological emergencies in the cancer patient. *Seminars in Oncology*. 2000; 27: 284.
6. 2  
clntyre JE, Eifel PJ, Levenback C. Ureteral stricture as a late complication of radiotherapy for stage 1b carcinoma of the uterine cervix. *Cancer*. 1995; 75: 836.
7. Kouba E, Wallen EM, Pruthi RS. Management of ureteral obstruction due to advanced malignancy: Optimizing therapeutic and palliative outcomes. *The Journal of Urology*. 2008; 180: 444-50.
8. College of American Pathologists. Cervical cancer. Cervical squamous cell carcinoma, 2011. (accessed September 29, 2013) Available from: <http://www.cap.org/apps/docs/reference/myBiopsy/cervicalsquamo1.pdf>
9. 1  
at J, Damjanov I. Tumors of the female genital organs. In: Damjanov I and Fan F, eds, 2<sup>nd</sup> ed. *Cancer Grading Manual*. Berlin Heidelberg: Springer-Verlag; 2013. p. 109-18.
10. Rohan TE. The epidemiology of adenocarcinoma of the cervix. In: Rohan TE and Shah KV, eds. *Cervical Cancer: From Etiology to Prevention*. Dordrecht: Kluwer academic publishers; 2004. p. 217-29.
11. 1  
C Cancer Agency. Invasive - Squamous cell carcinoma and adenocarcinoma, 2013. (accessed September 29, 2013) Available from: <http://www.bccancer.bc.ca/HPI/CancerManagementGuidelines/Gynecology/UterineCervix1of2/Management/Invasive.htm>
12. De Oliveira CF, Mota F. Cervical cancer - pre therapeutic investigations and clinical staging 'versus' surgical staging. *CME Journal of Gynecologic Oncology*. 2001; 6: 246-56.
13. Chitale SV, Scott-Barrett S, Ho ETS, Burgess NA. The management of ureteric obstruction secondary to malignant pelvic disease. *Clinical Radiology*. 2002; 57: 1118-21.



# Oral Phenazopyridine HCl for Ureter Orifice Identification

## ORIGINALITY REPORT

9%

SIMILARITY INDEX

8%

INTERNET SOURCES

4%

PUBLICATIONS

0%

STUDENT PAPERS

## PRIMARY SOURCES

1

[juri.urologi.or.id](http://juri.urologi.or.id)

Internet Source

8%

2

John B. Liao, Cynthia E. Fisher, Margaret M. Madeleine. "Gynecologic cancers and solid organ transplantation", American Journal of Transplantation, 2019

Publication

1%

3

Paul Russo. "URETERAL OBSTRUCTION AND STENTS: STILL A DIFFICULT PROBLEM FOR PATIENTS AND UROLOGISTS ALIKE", The Journal of Urology, 2005

Publication

<1%

Exclude quotes On

Exclude bibliography On

Exclude matches Off