

# THE EFFECT OF DEXAMETHASONE ON SPERMATOGONIUM AND SERTOLI CELL OF IPSILATERAL TESTIS IN UNILATERAL TESTICULAR TORSION WISTAR RAT

<sup>1</sup>Ferdyan Rachmat Efendi, <sup>3</sup>Budiono, <sup>2</sup>I Ketut Suidiana, <sup>1</sup>Johan Renaldo, <sup>1</sup>Tarmono Djodimedjo.

<sup>1</sup>Department of Urology, Faculty of Medicine/Universitas Airlangga, Soetomo General Hospital, Surabaya.

<sup>2</sup>Department of Pathology Anatomy, Faculty of Medicine/Universitas Airlangga, Soetomo General Hospital, Surabaya.

<sup>3</sup>Department of Community Health Sciences, Faculty of Medicine/Universitas Airlangga, Soetomo General Hospital, Surabaya.

## ABSTRACT

**Objective:** To investigate the effect of dexamethasone on spermatogonium and sertoli cell of ipsilateral testis in unilateral testicular torsion strain wistar rat. **Material & Method:** Experimental study with post-test only control group design. The present study was conducted on 30 Wistar male rats aged 10 – 12 weeks grouped into 5 groups. Group I was the normal/sham operation group (KN), group II was left testicular torsion for 4 hours group and followed by manual detorsion (K1), group III was left testicular torsion for 10 hours group and followed by manual detorsion (K2), group IV was left testicular torsion for 4 hours group and given dexamethasone 10 mg/kg body weight subcutaneously 30 minutes before manual detorsion (D1), and group V was left testicular torsion for 10 hours group and given dexamethasone 10 mg/kg body weight subcutaneously 30 minutes before manual detorsion. All rats had left orchidectomy 4 hours after detorsion. The number of spermatogonium and sertoli cells were counted in histological seminiferous tubular testis that have obtained Haematoxylin Eosin staining. Data were analyzed by ANNOVA followed by Post Hoc Tukey for spermatogonium and Kruskal Wallis followed by Mann Whitney test for sertoli cell. Differences were considered significant at  $p < 0.05$ . **Results:** There was significant difference in the mean number of spermatogonium between K1 & D1 group. Otherwise, there was no significant difference in the mean number of spermatogonium between K2 & D2. There was significant difference in the mean number of Sertoli cells between K1 & D1 group, likewise that between K2 & D2 group. **Conclusion:** These results suggest that dexamethasone has protective effect in spermatogonium and sertoli cell in testicular torsion for 4 hours.

**Keywords:** Dexamethasone, spermatogonium, sertoli cells, testicular torsion.

## ABSTRAK

**Tujuan:** Untuk membuktikan pengaruh pemberian deksametason terhadap jumlah sel spermatogonium dan sel sertoli pada tikus dengan torsio testis. **Bahan & Cara:** Penelitian ini merupakan penelitian eksperimental dengan desain post-test only control group. Pada penelitian ini sebanyak 29 ekor tikus secara random dibagi menjadi 5 kelompok. Kelompok I adalah normal atau sham (KN), kelompok II adalah hewan coba torsio testis 4 jam kemudian dilakukan detorsi manual (K1), kelompok III adalah hewan coba torsio testis 10 jam kemudian dilakukan detorsi manual (K2), kelompok IV adalah hewan coba torsio testis 4 jam yang mendapat deksametason 10 mg/kgBB/subkutan 30 menit sebelum dilakukan detorsi manual (D1), kelompok V adalah hewan coba torsio testis 10 jam yang mendapat deksametason 10 mg/kgBB/subkutan 30 menit sebelum dilakukan detorsi manual (D2). Dilakukan orkidektomi testis ipsilateral pada semua tikus 4 jam setelah detorsi testis. Jumlah spermatogonium dan sel sertoli dihitung berdasarkan rerata jumlah penampang tubulus seminiferus yang diamati pada 10 penampang sayatan testis ipsilateral dengan pewarnaan Haematoxylin Eosin. Data dianalisa menggunakan tes Annova diikuti dengan Post Hoc Tukey untuk spermatogonium, dan Kruskal Wallis diikuti dengan tes Mann Whitney untuk sertoli sel. Perbedaan dianggap signifikan pada  $p < 0.05$ . **Hasil:** Terdapat perbedaan yang bermakna jumlah spermatogonium antara K1 dan D1 ( $p < 0.05$ ). Sebaliknya tidak terdapat perbedaan jumlah spermatogonium antara K2 dan D2 ( $p > 0.05$ ). Sedangkan pada sel sertoli terdapat perbedaan yang bermakna jumlah sel sertoli antara K1 dan D1 maupun K2 dan D2 ( $p < 0.05$ ). **Simpulan:** Pemberian deksametason memberikan efek proteksi terhadap spermatogonium dan sel sertoli pada torsio testis 4 jam.

**Kata Kunci:** Deksametason, spermatogonium, sel sertoli, torsio testis.

Correspondence: Ferdyan Rachmat Efendi, c/o: Department of Urology, Faculty of Medicine/Universitas Airlangga, Soetomo General Hospital. Jl. Mayjend. Prof. Dr. Moestopo 6-8, Surabaya 60286. Phone: +62 31 5501318; Fax: +62 31 5024971. Mobile phone: 081336665706. Email: ferdy.efendi@gmail.com.

## INTRODUCTION

Testicular torsion is one of the urological emergencies with a high incidence rate. About 1 in 4000 men are reported getting testicular torsion annually.<sup>1,3</sup> Based on data from the Emergency Installation Soetomo Hospital, Surabaya on January 2011 to December 2015, about 30% are under 15 years old, and 70% are between 15-25 years old.<sup>4</sup> A total of 16 patients (80%) came more than 6 hours after the onset of testicular torsion, whereas only 4 patients (20%) came before 6 hours after the incident.<sup>4</sup> Testicular torsion could cause decrease of blood flow into the testis which is the site of the spermatogenesis process. Several studies have shown that testicular torsion could lead germinal cell damage in the seminiferous tubular epithelium.<sup>5-9</sup> Testicular torsion also causes blood flow could not reach sertoli cells causing spermatogenic cells underwent nutrient insufficient. Thus, testicular torsion may cause disturbance in the spermatogenesis process.<sup>10</sup>

Early diagnosis and early appropriate management needed to prevent subfertile or infertile conditions. Exarcebation of testicular torsion determines the occurrence of testis damage. Ischemic periods longer than 4-6 hours result in permanent tissue damage.<sup>3,11</sup> Manual detorsion is one of the most commonly performed action on torsion testicular. Its action aimed to restore blood supply to the testis that leading reperfusion to ischemic testis.<sup>11</sup> Although manual detorsion expected to be advantageous but it action paradoxically produces a detrimental effect. Manual detorsion could leading ischemic reperfusion injury that could generate oxidative stress by overproduction of reactive oxygen species (ROS).<sup>12</sup> Stress oxidative could resulting destruction of lipid membrane including spermatogonium and sertoli cells.<sup>5,12-17</sup>

Dexamethasone is one of the drugs of the glucocorticoid class that reported could prevent tissue damage due to ischemic reperfusion injury. There were several mechanism to prevent tissue damage due to ischemic reperfusion injury, such as inhibiting inflammatory mediators, neutrophil adhesion, and formation of free radicals.<sup>18-20</sup> Yazawa et al, reported that dexamethasone could inhibit germinal cell apoptosis after 12 hours manual detorsion in testicular torsion.<sup>20</sup> Study about effect of dexamethasone to spermatogonium and sertoli cell has not been widely reported.

## OBJECTIVE

To investigate the effect of dexamethasone on spermatogonium and sertoli cell of ipsilateral testis in unilateral testicular torsion strain wistar rat.

## MATERIAL & METHOD

The present study was experimental study with post test only control group design. 10-12 week-old Wistar male rats (150–200 g) were maintained under controlled room temperature with food and water ad libitum. 30 Wistar male rats aged 10 – 12 weeks were grouped into 5 groups. Group I was the normal/sham operation group (KN), group II was left testicular torsion for 4 hours group and followed by manual detorsion (K1), group III was left testicular torsion for 4 hours group and followed by manual detorsion (K2), group IV was left testicular torsion for 4 hours group and given dexamethasone 10 mg/kg body weight subcutaneously 30 minutes before manual detorsion (D1), and group V was left testicular torsion for 10 hours group and given dexamethasone 10 mg/kg body weight subcutaneously 30 minutes before manual detorsion.

The rats were fasted for 12 hours prior to surgery. Surgical procedures were performed under ketamine anesthesia (75 mg/kgBW/intraperitoneal (ip)) and sterile condition. After the induction of anesthesia, left scrotal incision was performed until funiculus spermaticus appear. The testicle was rotated 3 x 360° in an anticlockwise direction and maintained in this twisted position by fixing the testicle to the dartos tunica in scrotum with cat gut 3.0 suture. The scrotum was closed with cut gut 3.0 and rats were fasted for 12 hours.

Suturing in scrotum was reopened until funiculus spermaticus appear. The testicle was rotated 3 x 360° in an anticlockwise direction, then the scrotum was closed with cut gut 3.0.

Orchidectomy was performed after 4 hours testicular manual detorsion. Surgical procedures were performed under ketamine anesthesia (75 mg/kgBW/intraperitoneal) and sterile condition. After the induction of anesthesia, left scrotal incision was performed until funiculus spermaticus appear. Funiculus spermaticus was clamped on two adjacent places and it was cutted between them. After that, the proximal site was tied with silk 3.0 and the clamp was removed. Testis was taken and immediately fixed with buffer formalin pH 7.4. Scrotum incision was closed with cut gut 3.0

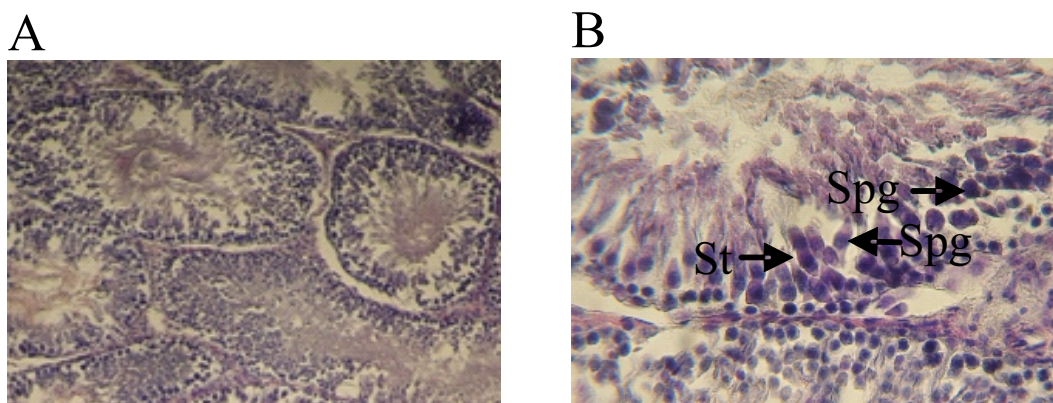
The testis tissue was fixed in 4% formalin buffer solution and then blocked using paraffin by standard technique. Then testis tissue was cutted with size 5µm then it was stained by haematoxylin and eosin (HE) staining. Histological tissue was investigated using a microscope with 400x magnification. Spermatogonium is located just above the basal lamina. Spermatogonium has an oval-shaped nucleus with dark or pale color. However, there is also a spermatogonium having a round nucleus containing solid chromatin mass associated with the nuclear membrane. While sertoli cells are slim and long shapes with irregular boundaries and extend from the basement membrane to the seminiferous tubular lumen. The core of sertoli cells generally has a more elongated shape, and contains a small amount of smooth chromatin. The prominent nucleolus thus distinguishes it from the spermatogenic cells lined up between and around the sertoli cells.

Spermatogonium and Sertoli cell number was counted according to the average number of cross sections of the seminiferous tubules was observed from the 10 ipsilateral testis slices. Histologic examination performed by the experts at the Faculty of Medicine, Airlangga University.

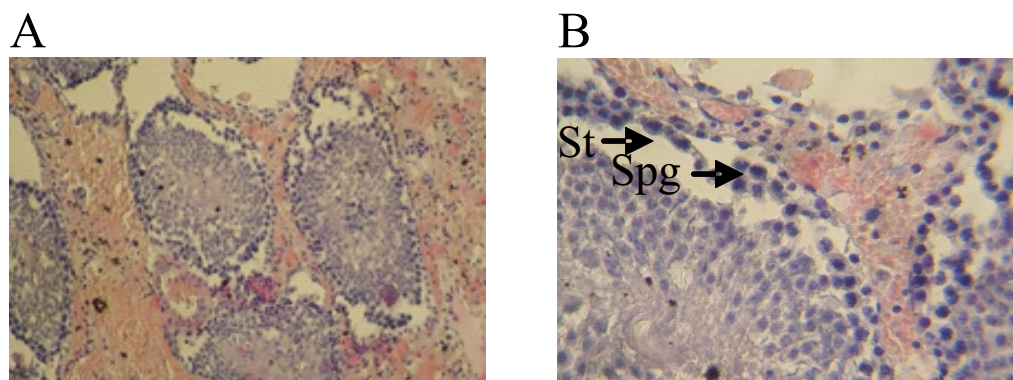
Data was analyzed using SPSS 20 for windows. Spermatogonium data were analyzed by Anova test and followed by Post Hoc Tukey HSD test. While sertoli cells were analyzed by using Kruskal-Wallis test and followed by Post Hoc Mann-Whitney U test. Data was considered significant if p value <0.05.

## RESULTS

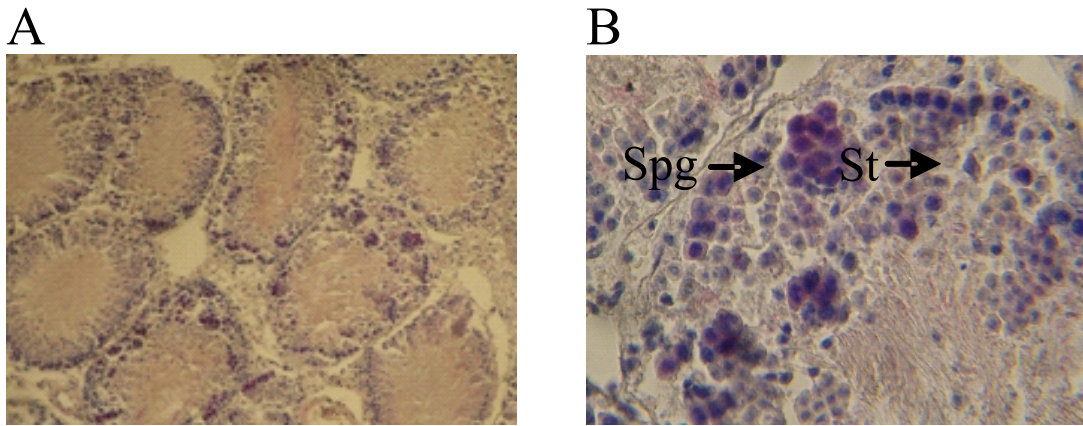
In the present study, the histological morphologies have showed in this figure below.



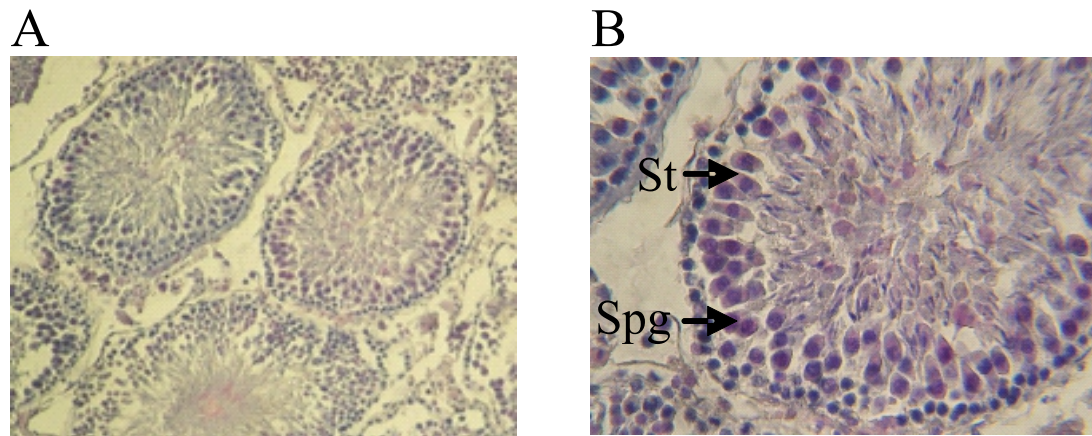
**Figure 1.** Microscopic features of the cross section of the seminiferous tubules in sham operation group (KN). A. (H.E staining at 100 x magnification) B. (H.E staining at 400 x magnification). St: sertoli cell; Spg: spermatogonium.



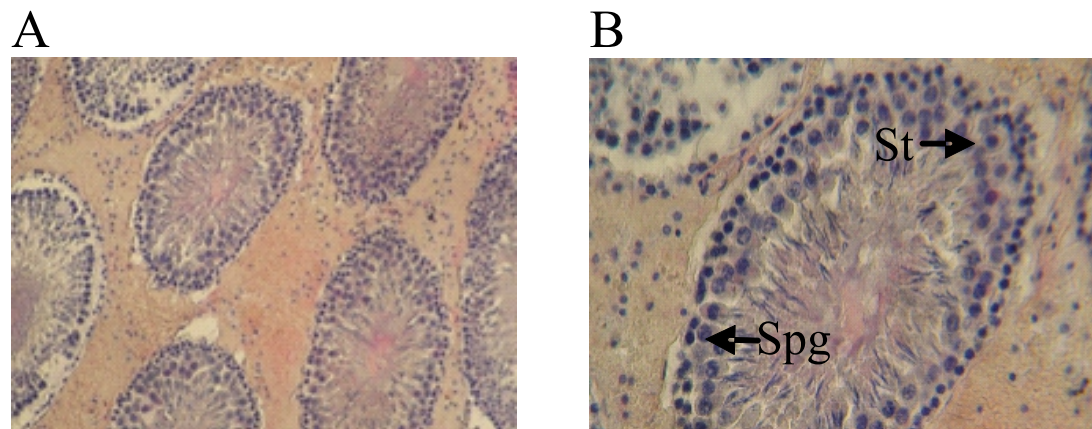
**Figure 2.** Microscopic features of the cross section of the seminiferous tubules in testicular torsion for 4 hours group and followed by testicular manual detorsion (K1). A. (H.E staining at 100 x magnification) B. (H.E staining at 400 x magnification) St: sertoli cell; Spg: spermatogonium.



**Figure 3.** Microscopic features of the cross section of the seminiferous tubules in testicular torsion for 10 hours group and followed by testicular manual detorsion (K2). St: sertoli cell; Spg: spermatogonium.



**Figure 4.** Microscopic features of the cross section of the seminiferous tubules in testicular torsion for 4 hours group and given dexamethasone 10 mg/kg body weight/SC 30 minutes before manual detorsion (D1). St: sertoli cell; Spg: spermatogonium.



**Figure 5.** Microscopic features of the cross section of the seminiferous tubules in testicular torsion unilateral for 10 hours group and given dexamethasone 10 mg/kg body weight/SC 30 minutes before manual detorsion (D2). St: sertoli cell; Spg: spermatogonium.

Based on the data in tables 1 and 2, it could be seen that in KN group was the largest spermatogonium number than all groups and it was statistically significant with p value <0.05. The number of spermatogonium in the KN group was greater than K1 or K2 with p value <0.05. The present study has shown that testicular torsion for either 4 hours or 10 hours could lead decreasing spermatogonium number. The duration of testicular torsion seems to determine the number of spermatogonium. It could be seen in tables 1 and 2 that the number of spermatogonium in K1 greater than K2 with p value <0.05.

Administration of dexamethasone prior to testicular manual detorsion on D1 had a significant effect on spermatogonium number compared with the K1. Based on data in table 1 and 2, it was found that the number of spermatogonium in D1 was greater than K1 with p<0.05. However, unequal results were found in K2. Based on statistical data (table 2), administering dexamethasone prior to testicular manual detorsion is not able to prevent decreasing of spermatogonium as seen as D2 with

p>0.05. From the data, we found that the number of spermatogonium in group D1 has a significant difference compared with group D2, that is the number of spermatogonium group D1 is greater than group D2 with p value <0.05 (table 1 and 2). In the present study, it could be seen that administering of dexamethasone prior to testicular manual detorsion could give protective effect to spermatogonium number. This protective effect is influenced by the duration of testicular torsion. The present study suggests that administration of dexamethasone gave a protective effect only in groups undergoing testicular torsion for 4 hours prior to testicular manual detorsion was performed.

Based on the data in table 3 and 4 it can be seen that there is a significant difference in the number of sertoli cells in the KN group compared with the K1 group and in the K2 group with a value of p <0.05. In the present study was found that the number of sertoli cells in the KN was greater than K1 or K2 with p value <0.05. The present study suggests that the testicular torsion causes decreasing in the number of sertoli cells. Based on the data that found

**Table 1.** The effect of dexamethason on spermatogonium number.

Groups	n	The number of spermatogonium	p
KN	5	72.78 ± 6.73	0.00*
K1	6	43.00 ± 4.44	
K2	6	33.83 ± 2.47	
D1	6	58.33 ± 3.13	
D2	6	36.05 ± 5.78	

\*p<0.05

**Table 3.** The Effect of dexamethason on sertoli cells number.

Groups	n	Median	Min-Max	p
KN	5	9.20	7.80 – 14.10	0.00*
K1	6	2.50	2.20 – 5.90	
K2	6	3.65	2.00 – 5.30	
D1	6	8.55	5.90 – 11.20	
D2	6	7.10	4.90 – 9.40	

\*p value <0.05

**Table 2.** Comparison of the spermatogonium number in each group by Tukey HSD Post Hoc.

Comparison between groups	Mean ± SD	VS	Mean ± SD	p
KN vs K1	72.78 ± 6.73	VS	43.00 ± 4.44	0.00*
KN vs K2	72.78 ± 6.73	VS	33.83 ± 2.47	0.00*
KN vs D1	72.78 ± 6.73	VS	58.33 ± 3.13	0.00*
KN vs D2	72.78 ± 6.73	VS	36.05 ± 5.78	0.00*
K1 vs K2	43.00 ± 4.44	VS	33.83 ± 2.47	0.02*
K1 vs D1	43.00 ± 4.44	VS	58.33 ± 3.13	0.00*
K2 vs D2	33.83 ± 2.47	VS	36.05 ± 5.78	0.92
D1 vs D2	58.33 ± 3.13	VS	36.05 ± 5.78	0.00*

\*p<0.05

**Table 4.** Comparison of the spermatogonium number in each group by Mann-Whitney U post hoc test.

Comparison between group	Median (Min-Max)	Median (Min-Max)	p
KN vs K1	9.20 (7.80 – 14.10)	2.50 (2.20 – 5.90)	0.006*
KN vs K2	9.20 (7.80 – 14.10)	3.65 (2.00 – 5.30)	0.006*
KN vs D1	9.20 (7.80 – 14.10)	8.55 (5.90 – 11.20)	0.23
KN vs D2	9.20 (7.80 – 14.10)	7.10 (4.90 – 9.40)	0.10
K1 vs K2	2.50 (2.20 – 5.90)	3.65 (2.00 – 5.30)	1.00
K1 vs D1	2.50 (2.20 – 5.90)	8.55 (5.90 – 11.20)	0.005*
K2 vs D2	3.65 (2.00 – 5.30)	7.10 (4.90 – 9.40)	0.006*
D1 vs D2	8.55 (5.90 – 11.20)	7.10 (4.90 – 9.40)	0.30

\*p value <0.05

in K1 and K2, there is a decrease in the number of sertoli cells. In addition there is no significant different in the number of sertoli cells either K1 or K2. Duration of testicular torsion both 4 hours and 10 hours resulted in a similar decrease in the number of sertoli cell. In the present study administering of dexamethason in testicular torsion could influence the number of sertoli cell. It could be seen on tables 3 and 4 that there is significant different in the number of sertoli cell between K1 and D1. The number of sertoli cell in D1 greater than K1 with p value <0.05. Similar results were also shown in groups K2 and D2 where there is a significant difference between K2 and D2 with p value <0.05. The number of sertoli cell in D2 greater than K2. Moreover, between D1 and D2 have shown that there was no significantly difference with p value >0.05.

## DISCUSSION

Testicular torsion is the torsion of the spermatic cord structures and subsequent loss of the blood supply to the ipsilateral testicle. Finally it conditions causing testicle underwent ischemic periods. If this ischemic condition is not treated immediately, testicle could be damaged and necrosis.<sup>3,11</sup> During ischemia, ATP production decreases due to the limited amount of oxygen. In this condition there is an increase in intracellular Ca<sup>2+</sup> which triggers the conversion of xantin dehydrogenase to xanthine oxidase which is an enzyme generating superoxide radical. In addition, ischemia activates complement system and chemotactic factor causing migration of polymorphonuclear leukocytes which will eventually generate superoxide radicals. This condition leading oxidative stress that may cause further damage to the testicular tissue.<sup>5,8,14-16</sup> In the present study, it could be

seen that the testicular torsion lead decreasing the number of spermatogonium and sertoli cells significantly. Duration of testicular torsion determine the number of spermatogonium and sertoli cells. The longer the time of the occurrence of testicular torsion there is a significant decrease in both the number of spermatogonium and sertoli cells. Testicular torsion lead decreasing of testosterone level so that it may lead increases apoptosis in germinal cell.<sup>2</sup> Therefore, early diagnosis and definitive management of testicular are important to avoid testicular damaged.

Testicular manual detorsion is standard treatment in testicular torsion. Its action performed to restore the blood flow to the testes so that the adverse effects of testicular torsion can be reduced. However, paradoxical effects often result from this action. This action could trigger ischemic reperfusion injury that could generate oxidative stress resulting in more severe tissue damaged. In the present study the administration of dexamethasone could provide protective effect of both spermatogonium and sertoli cells against ischemic reperfusion injury due to testicular manual detorsion. Yazawa et al, reported that dexamethason may suppress germ cell apoptosis induced by testicular ischemia.<sup>20</sup> In the present study the possible effects of dexamethasone can inhibit the occurrence of cell damage through anti-inflammatory mechanisms that can inhibit neutrophils that trigger oxidative stress. After administration of dexamethasone there will be an inhibition of the inflammatory reaction that occurs after ischemia which causes a decrease of TNF- $\alpha$  proinflammatory cytokines. The bond between TNF- $\alpha$  and TNF- $\alpha$ R in spermatogonium surface will also decrease, thereby decreasing the activity of Fas associated protein death domain (FADD)-caspase-DNAase protein and

apoptosis of spermatogonium. In addition, inhibition of the inflammatory reaction that occurs during ischemia and ischemic reperfusion injury will suppress the production of ROS. The decrease ROS will cause the ratio between the scavenger and ROS increases. It could neutralize ROS that could damage the cell membrane of spermatogonium and sertoli cells.<sup>20</sup> In the present study we also found that the duration of testicular both 4 hours and 10 hours have almost the equal effect. In the ischemia condition, sertoli cells could survive likely caused by induction of the hormone testosterone that works in paracrine system. In a previous study, it was found that testosterone levels in rats undergoing testicular torsion for 4 hours were not significantly different from without torsion group. Testosterone levels will decrease significantly in rats that have testicular torsion for 24 hours.<sup>2</sup> This explain that in the testicular torsion for 4 hours and 10 hours still found the testosterone levels are close to normal. Therefore, administration of dexamethasone can provide protection in sertoli cells that have testicular torsion.

## CONCLUSION

In the present study suggested that administration of dexamethasone may provide protection effect for spermatogonium and sertoli cells in testicular torsion for 4 hours. While in the testicular torsion for 10 hours, administration of dexamethasone only provide protection effect to sertoli cells.

## REFERENCES

1. Feher A, Bajory Z. A review of main controversial aspects of acute testicular torsion. *J Acute Dis.* 2016; 5(1): 1–8.
2. Hardjowijoto S. The effects of unilateral testicular torsion upon immunity modulation and apoptosis of germinal cells in the contralateral testis-An experimental study in rats. *Folia Medica Indonesiana.* 2005; 41(1): 9–17.
3. Ringdahl E, Teague L. Testicular Torsion. *Am Fam Physician.* 2006; 74: 1739–43.
4. Nurhadi P, Soetoyo. Profil Akut Skrotum di Rumah Sakit Umum Dr. Soetomo Surabaya Periode Januari 2011-Desember 2015. *Retrospective Study;* 2015.
5. Shimizu S, Martin DT, Dimitriadis F, Satoh K, Saito M. The effect of ischemic preconditioning and postconditioning on testicular torsion-detorsion injury. *Glob J Biochem.* 2011; 3: 1.
6. Elshaari F, Elfagih RI, Sheriff D, Barassi I. Cytology & Histology Testicular Torsion-Detorsion- Histological and Biochemical Changes in Rat Testis. *J Cytol Histol.* 2012; 3(1): 1–6.
7. Krarup T. The Testes After Torsion. *Br J Urol.* 1978; 50: 43–6.
8. Lysiak JJ, Turner SD, Nguyen QAT, Singbartl K, Ley K, Turner TT. Essential Role of Neutrophils in Germ Cell-Specific Apoptosis Following Ischemia /Reperfusion Injury of the Mouse Testis. *Biol Reprod.* 2001; 725: 718–25.
9. Turner TT, Tung KSK, Tomomasa H, Wilson LW, Al TET. Acute Testicular Ischemia Results in Germ Cell-Specific Apoptosis in the Rat. *Biol Reprod.* 1997; 1274: 1267–74.
10. Viguera RM, Reyes G, Rojas P, Hernández R. Testicular torsion and its effects on the spermatogenic cycle in the contralateral testis of the rat. *Lab Anim.* 2004; 38: 313–20.
11. Sharp VJ, Arlen AM. Testicular Torsion: Diagnosis, Evaluation, and Management. *Am Fam Physician.* 2013; 88: 835–40.
12. Filho DW, Torres MA, Crezcynski-pasa B, Boveris A. Spermatic cord torsion, reactive oxygen and nitrogen species and ischemia–reperfusion injury. *Mol Aspects Med.* 2004; 25: 199–210.
13. Aktöz T, Kanter M, Aktas C. Protective effects of quercetin on testicular torsion/ detorsion-induced ischaemia-reperfusion injury in rats. *Andrologia;* 2010. p. 376–83.
14. Dokmeci D, Inan M, Basaran UN, Yalcin O, Aydogdu N, Turan FN, et al. Protective effect of L-carnitine on testicular ischaemia-reperfusion injury in rats. *Cell Biochem Funct.* 2007; 25(8): 611–8.
15. Turrens JF. Superoxide Production by the Mitochondrial Respiratory Chain. *Biosci Rep.* 1997; 17(1): 3–8.
16. Akondi BR, Challa SR, Akula A. Protective Effects of Rutin and Naringin in Testicular Ischemia - Reperfusion Induced Oxidative Stress in Rats. *J Reprod Infertil.* 2011; 12(2): 209–14.
17. Turner TT, Brown K. Spermatic Cord Torsion: Loss of Spermatogenesis Despite Return of Blood Flow. *Biol Reprod.* 1993; 407: 401–7.
18. Mogilner J, Elenberg Y, Lurie M, Shiloni E, Coran A, Sukhotnik I. Effect of dexamethasone on germ cell apoptosis in the contralateral testis after testicular ischemia - reperfusion injury in the rat. *Fertil Steril.* 2006; 85: 1111–7.
19. Fouad A, El-Bidawy M, Uddin A, Yacoubi M. A preliminary study of dexamethasone against ischemia/reperfusion liver injury in rats. *Int J Pharmacol.* 2009; 5(2): 155–61.
20. Yazawa H, Sasagawa I, Suzuki Y, Nakada T. Glucocorticoid hormone can suppress apoptosis of rat testicular germ cells induced by testicular ischemia. *Fertil Steril.* 2001; 75(5): 980–5.