

ORIGINAL ARTICLE

Post Oral Administration of Epigallocatechin Gallate from *Camelia sinensis* Extract Enhances Vascular Endothelial Growth Factor and Fibroblast Growth Factor Expression during Orthodontic Tooth Movement in Wistar Rats

Fidiyah Inayati¹, Ida Bagus Narmada^{1*}, I Gusti Aju Wahyu Ardani¹, Alexander Patera Nugraha¹,
Dwi Rahmawati¹

¹Orthodontics Department, Faculty of Dental Medicine, Airlangga University, Surabaya, Indonesia

Abstract:

Background: East Java green tea leaf (*Camelia sinensis*) possessed active compound such as Epigallocatechin Gallate (EGCG) is well known for enhancing the bone remodelling through enhancement of Vascular Endothelial Growth Factor (VEGF) and Fibroblast Growth Factors (FGF-2). Remodelling of alveolar bone is very important to obtain optimal Orthodontic Tooth Movement (OTM) to align the tooth. **Aim:** To investigate the expression of VEGF and FGF-2 expression during OTM in Wistar rat after administration of EGCG from *C. sinensis* Extract (EGCG-CSE) Wistar rats. **Material and Methods:** This study was true experimental study with post-test only control group design. Twenty eight Wistar rats were randomly selected and divided into four groups accordingly; K- group which did not get both EGCG-CSE administration and OTM; K+ group with OTM for 14 days, but no EGCG-CSE administration; 1 (T1) with 4 days of OTM and 7 days of EGCG-CSE administration; treatment group 2 (T2) with both 14 days OTM and EGCG-CSE administration. Ten g force/mm² of NiTi close coil spring was installed between the upper left molars and central incisor to move the molar mesially that induce OTM. All OTM animal model were terminated in the 14th days. Maxillary was isolated for immunohistochemistry investigation. Tukey Honest Significant Difference (HSD) was done after Analysis of Variance (ANOVA) test to investigate the significant difference between groups (p<0.05). **Results:** The highest positive VEGF expression was found in the T2 in both area.

Meanwhile, the highest positive FGF-2 expression was found in the K-group in both area. There were significant different of VEGF and FGF-2 expression in both area between groups except T1 and T2. **Conclusion:** Post administration of EGCG-CSE can stimulate the VEGF and FGF-2 expression during OTM in Wistar rats.

Keywords: Epigallocatechin Gallate, Fibroblast Growth Factor-2 Expression, Green Tea, Tooth Movement Techniques, Vascular Endothelial Growth Factor expression.

Introduction:

Periodontal tissue remodeling is the main key that should be considered during Orthodontic Tooth Movement (OTM) to achieve optimal orthodontic treatment result. Bone remodeling is the process of bone resorption that occur in compression area and bone formation in tensile area. OTM can be optimally controlled by the force magnitude and the biological response of periodontal tissue [1]. The force that applied in OTM can lead to macro and micro environment change around Periodontal Ligament (PDL) due to blood flow changes. Thus, that condition can stimulate the secretion of cytokines, chemokines, growth factors, prostaglandin which are important factor for bone remodeling. Bone remodeling is a crucial process to maintain bone homeostasis [2,3].

Growth Factors (GFs) such as Vascular Endothelial Growth Factor (VEGF) or Fibroblast Growth Factor (FGF-2) play pivotal role during bone remodeling. VEGF is the main mediator of angiogenesis and it serves a variety of biological functions, such as stimulate vascular permeability and promote monocyte chemotaxis. VEGF is also involved in bone and periodontal tissue remodeling [4]. Previous study mentioned that FGF-2 is important for angiogenesis by enhance the migration in various types of endothelial cells. Furthermore, FGF-2 stimulate endothelial cell proliferation and remodelling of blood vessels due to injury. Lack of FGF-2 can lead defects in endothelial cell integrity [5].

The active and effective antioxidant compound possessed green tea (*C. sinensis*) such as Epigallocatechin gallate (EGCG-CS) has beneficial for health in medicine field. EGCG is very useful and promising active compound for bone remodelling during OTM [6-7]. The aim of this study was to investigate the post administration of EGCG-CS in VEGF and FGF-2 expressions during OTM in Wistar rats.

Material and Methods:

This study was approved with reference number 0074/HRECC.FODM/III/2019. The study design of this study was true experimental study with post-test only control group design. Blind simple random sampling was done to select the sample. Green tea leaf (*C. sinensis*) was brought from Perkebunan Nusantara XII Company, Wonosari, Lawang, Malang, East Jawa Indonesia. Green Tea (*C. Sinensis*) extract (CSE) was obtained from Faculty of Pharmaceutical, Widya Mandala Catholic University, Surabaya, Indonesia. Isolation of CSE was done by means of maceration method. The analysis of CSE was conducted using High Performance Liquid Chromatography

(HPLC) system (Agilent 1260, Agilent Technologies, German) [2,6].

Twenty eight healthy Wistar rats 16-20 weeks-old with weight 200-250g divided into 4 groups (Fig. 1A) accordingly; NiTi close coil spring with 6 mm length (American Orthodontics Corporation, USA) installed from maxillary molars to incisive to induce OTM with 10gf/mm² (Fig.1B) [8-9]. One hundred fifty mg/kg body weight (b w) dose of EGCG-CSE was administered perorally. Rodent anesthesia (60 mg/kg bw of ketamine and xylazine 3 mg/kg bw (Sigma-Aldrich, USA) was used to sacrificed all samples and premaxillae was isolated. Premaxillae was decalcified with 5% EDTA (OneMed, Indonesia) for 1-month. The sample was then undergo the tissue processing and embedded in paraffin according to previous method [9].

Immunohistochemical (IHC) staining was investigated by means of a 3,3'-diaminobenzidine stain kit (DAB) (Sigma Aldrich, US) with counter staining Hematoxylin Eosin (Sigma Aldrich, US). Monoclonal antibodies anti-FGF-2 (sc-365106) and anti-VEGF (sc-80442) was used in this study (Santa Cruz Biotechnology™, US). The positive number of VEGF and FGF expression in fibroblast at periodontal tissue was done by 3 observer in 5 different visual fields by means of Nikon H600L light microscope (Japan) at 400x magnification with a 300 megapixels Fi2 DS digital camera and image processing software Nikon Image System (Nikon, Japan). The data were analysed by Statistical Package for the Social Sciences 20.0 software (SPSS for Windows, SPSS, Chicago, USA). Descriptive statistics are given as Mean ± Standard Deviation (SD). One-way Analysis of Variance (ANOVA), and Tukey Honest Significant Difference (HSD) (p<0.05) was done based on Shapiro-Wilk and

Levene's test ($p > 0.05$) to compare the VEGF and FGF expression between groups.

Results:

Based on the data analysis showed that all data were homogen and distributed normally ($p > 0.05$). The positive expression of VEGF in fibroblast in both tensile and compression area can be seen in figs. 2A and 2B. T2 group in the compression and tensile area has the greatest number expression of VEGF. Meanwhile, the lowest number expression of VEGF found in K- both compression and tensile area. There were significant different of VEGF

expression in both compression and tensile area between groups except T1 and T2 (figs. 2C and 2D). In figs. 3A and 3B showed the FGF-2 positive expression in both tensile and compression area. The K-group in both compression and tensile area has the greatest number of FGF-2 expression. Meanwhile, the lowest number expression of FGF-2 found in K+ both compression and tensile area. There were significant different of FGF-2 expression in both compression and tensile area between groups except T1 and T2 (figs. 3C and 3D).

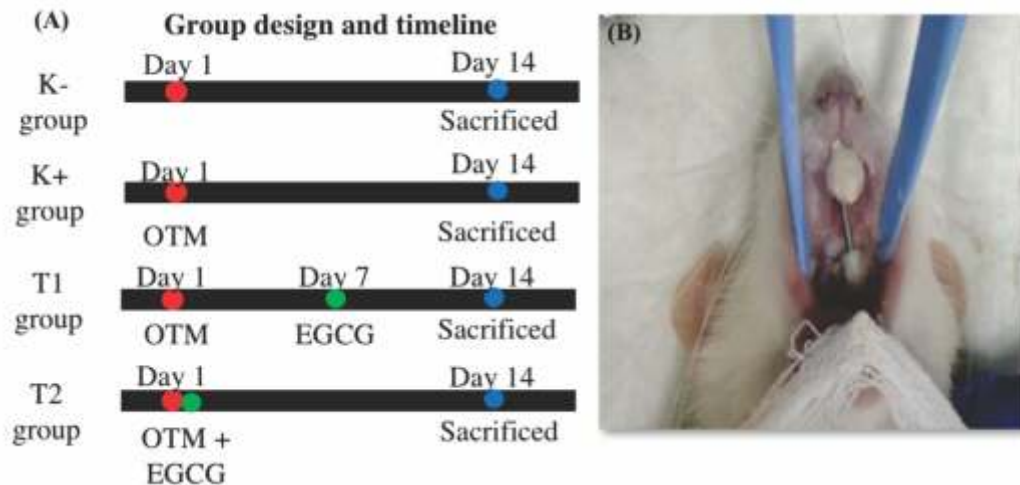


Fig. 1A: The Scheme of Study

Fig.1B: The Orthodontic Tooth Movement in Animal Model

Table 1: Mean of Standart Deviation, the Result of Normality Test and T-Test in Each Marker between Groups

Marker	Group				
	Mean ± Standart Deviation				
	K-	K+	T1	T2	P
VEGF in tensile area	1.9 ± 0.2	4.1 ± 0.7	5.6 ± 0.6	5.8 ± 0.4	0.001
VEGF in compression area	8.2 ± 0.1	6.3 ± 0.5	7.6 ± 0.2	8.9 ± 0.3	0.001
FGF-2 in tensile area	9.1 ± 1.1	2.7 ± 0.8	6.7 ± 5.9	7.7 ± 0.3	0.001
FGF-2 in compression area	10.9 ± 0.4	8.4 ± 0.3	9.3 ± 0.6	9.8 ± 0.5	0.001

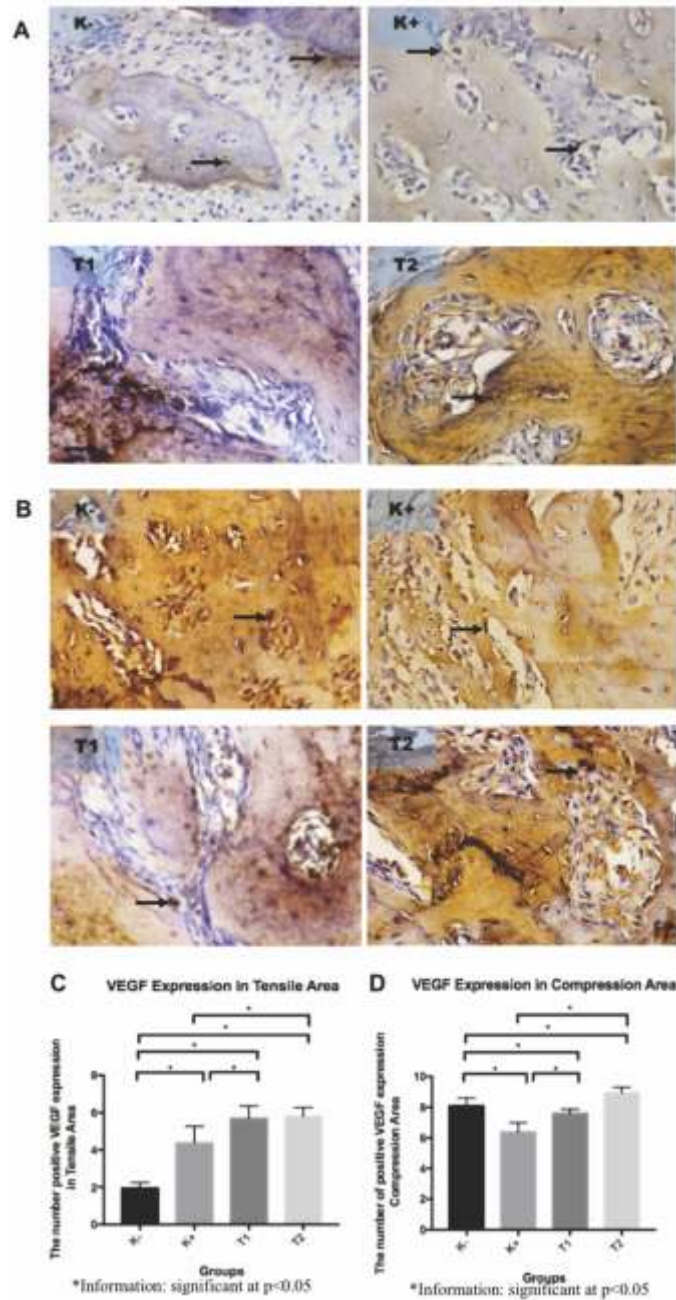


Fig. 2: Immunohistochemical Analysis showed Positive VEGF Expression (Brown Color) of Fibroblast at the Alveolar Bone (Black Arrow) with 400x Magnification Using Light Microscope.

(A) Positive VEGF expression at tensile area between groups. (B) Positive expression of VEGF at compression area can be seen in each group (C) Expression of VEGF at tensile area of each group was positively expressed. (D) Expression of VEGF at compression area can be observed in each group. There was significant difference of positive VEGF expression in both tensile and compression areas compared to each group ($p < 0.05$).

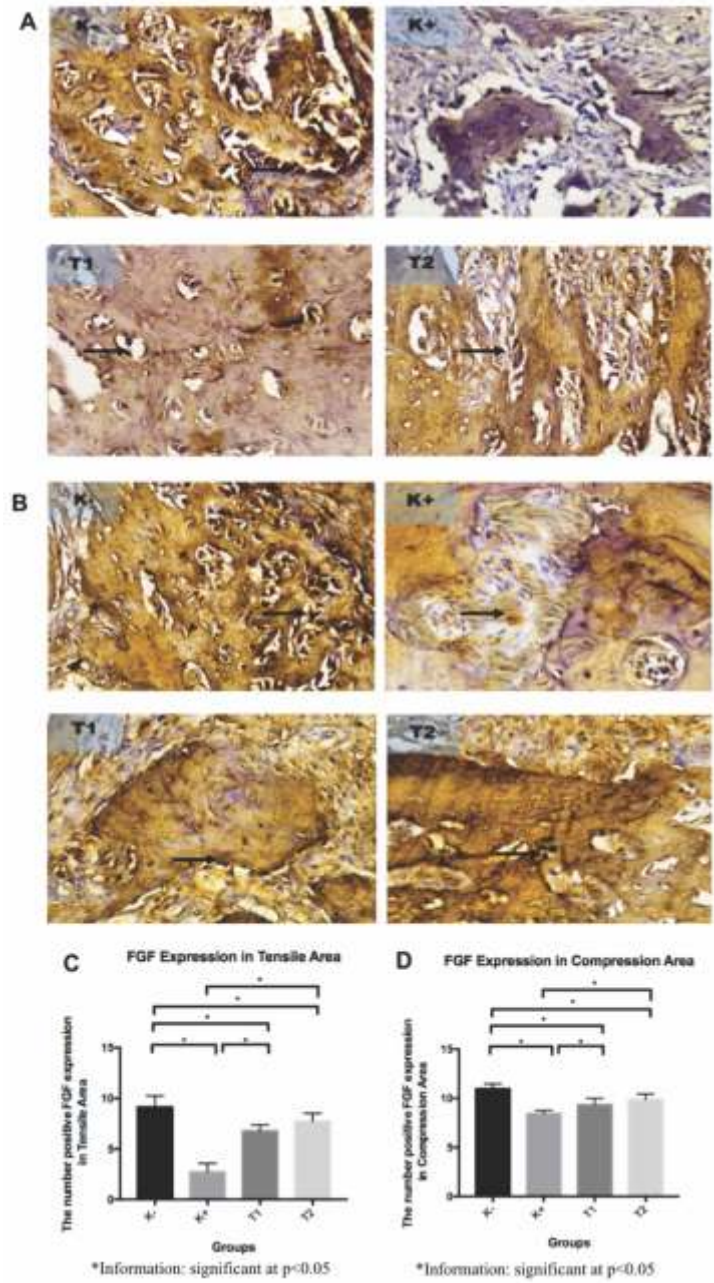


Fig. 3: Immunohistochemical Analysis showed Positive Fgf Expression (Brown Color) of Fibroblast at the Alveolar Bone (Black Arrow) with 400x Magnification Using Light Microscope. (A) Positive FGF expression at tensile area between groups. (B) Positive expression of FGF at compression area can be seen in each group (C) Expression of FGF at tensile area of each group was positively expressed. (D) Expression of FGF at compression area can be observed in each group. There was significant difference of positive FGF expression in both tensile and compression areas compared to each group (p<0.05).

Discussion:

In this present study, the expressions of VEGF and FGF-2 in the tensile and compressive area in both treatment group was increased significantly compared to the control groups, both positive and negative. The bioactive compound of green tea is EGCG that very useful for acceleration of alveolar remodelling [10]. EGCG was investigated for its benefits as beverages for daily consumption. EGCG is well known for its benefits in bone regeneration [11]. EGCG is a promising therapeutic strategy for bone regeneration and improve bone quality in obese and osteoporosis. EGCG can enhance bone formation through osteoblastogenesis stimulated by VEGF has an important role in enhancement of Prostaglandin F₂alpha (PGF₂). PGF₂ is also known can increase VEGF synthesis through Protein Kinase C (PKC) by independent stimulation of p44 / p42 Mitogen-Activated Protein Kinase (MAPK) in osteoblast. Previous study reported that EGCG increased PGF₂ regulation to synthesize VEGF by stimulation through enhancement of SAPK / JNK activation, but not p44 / p42 MAP kinase or p38 MAP kinase of osteoblasts [12-13].

Bone vascularization was regulated by VEGF which is angiogenic factor [14]. During the bone remodeling, angiogenesis takes an important role. Expression of VEGF was observed during differentiation of osteoblast [15]. Interestingly, VEGF also known as one of main cytokine that released by bone matrix during bone remodeling. Enhancement of VEGF expression may help to maintain the nutrition and oxygen supply through blood vessel [16-17].

Neovascularization is a crucial step of bone remodelling. Neovascularization carry the nutrient

and oxygen to stimulate the metabolic bone callus remodelling and migration of hematopoietic stem cells [18,19]. The purpose of bone remodelling is maintain its size, shape and structural integrity. Bones are rich in vascularization. Blood vessels in bone regulate the hematopoiesis synthesis. Abnormal function of bone blood vessel function related to the bone diseases [5,10-13].

Green tea (*C. sinensis*) contained of abundant flavonoid, one of them is catechin [8]. Previous study mentioned that bone resorption can be inhibited by catechin administration [10]. Osteoblast as a bone cells have a important role in bone remodeling. ALP secretion by osteoblast can be stimulated by catechin administration that can lead to calcium deposition and decreased of bone resorption related inflammatory cytokines [19-20]. Nevertheless, until now, the study of catechin still limited. Previous study mentioned that VEGF may secreted and produced by osteoblast. VEGF secretion by osteoblasts plays an important role in regulating bone metabolism. The mechanisms underlying VEGF synthesis in osteoblasts have not been fully explained. EGCG did not effect VEGF serum levels, but significantly increases PGF₂ which stimulates VEGF synthesis in osteoblast. PGF₂ stimulates VEGF synthesis through three MAP kinases, SAPK/JNK in osteoblast induced by EGCG [13].

Growth factors related to angiogenesis such as the VEGF or FGF-2 is well know as angiogenesis regulator. FGF-2 has been reported to be involved in angiogenesis. Previous research showed that the migration response of endothelial cells caused by FGF-2-stimulation. FGF-2. Lack of FGF-2 showed changes in various phenotypes, early embryonic death, minor blood vessel defects.

FGF-2 acts in a specific stage of body development. FGF-2 stimulate endothelial cell proliferation and blood vessels remodelling in response to injury [21].

In our study, the post oral administration of EGCG-CSE can increase FGF-2 expression which elucidate that there is an emphasis bone remodeling in both area during the OTM. OTM can trigger inflammation in the periodontal tissue [1, 2]. In this study, VEGF and FGF-2 expression between both treatment groups (T1 and T2) showed insignificant differences. In the T1 group during OTM stillin the Lag Phase. This stage is characterized by very little or even no tooth movement. The post oral administration of EGCG GTME which has the effect of osteoblastogenesis would be very synergistic because this phase occurs when osteoclasts have been recruited and osteoblasts are activated for microenvironment in the periodontal ligaments and bone remodelling [2].

In the T2 group during OTM is at the initial phase of the tooth movement. At this stage it is characterized

by the sudden displacement of the teeth in the socket. The initial phase occurs within 24 hours to 48 hours post OTM force was applied. OTM initial phase can induce the acute inflammatory response characterized by vasodilation of blood vessel and leukocyte migration to the capillaries. The cytokines were secreted by inflammatory cells. After this phase proliferative chronic inflammation phase will takes place. Cytokines released by mononocluer cells as chemical mediators that interact with bone cells directly or indirectly. Bone resorption was induced by PGE2 and increases the rate of orthodontic tooth movement thus it caused an insignificant difference between VEGF and FGF-2 expression between treatment groups [22-24].

Conclusion:

Based on the result we can conclude that post administration EGCG-CSE increased expression of VEGF and FGF-2 in the alveolar bone during OTM compared to those without the extract administration in Wistar rats based on its molecular investigation.

References

1. Narmada IB, Rubianto M, Putra ST. The role of low-intensity biostimulation laser therapy in transforming growth factor 1, bone alkaline phosphatase and osteocalcin expression during orthodontic tooth movement in *Cavia porcellus*. *Eur J Dent* 2019;13:102-107.
2. Nugraha AP, Narmada IB, Sitasari PI, Inayati F, Wira R, Triwardhani A, et al. High mobility group box 1 and heat shock protein-70 expression post (-)-epigallocatechin-3-gallate in East Java green tea methanolic extract administration during orthodontic tooth movement in wistar rats. *Pesqui Bras Odontopediatria Clín Integr* 2020; 20:e5347.
3. Nugraha AP, Narmada IB, Ernawati DS, Dinaryanti A, Hendrianto E, Riawan W, et al. Bone alkaline phosphatase and osteocalcin expression of rat's Gingival mesenchymal stem cells cultured in plateletrich fibrin for bone remodeling (in vitro study). *Eur J Dent* 2018; 12 (4): 566-573.
4. Nareswari RAAR, Narmada IB, Djaharu'ddin I, Rahmawati D, Putranti NAR, Nugraha AP. Effect of vitamin D administration on vascular endothelial growth factor expression and angiogenesis number in orthodontic tooth movement of pregnant Wistar rats. *J Postgrad Med Inst* 2019; 33(3): 182-188.

5. Puspasari A, Harijanti K, Soebadi B, Hendarti HT, Radithia D, Ernawati DS. Effects of topical application of propolis extract on fibroblast growth factor-2 and fibroblast expression in the traumatic ulcers of diabetic *Rattus norvegicus*. *J Oral Maxillofac Pathol*. 2018;22(1):54-58.
6. Sitasari PI, Narmada IB, Hamid T, Triwardhani A, Nugraha AP, Rahmawati D. East Java green tea methanolic extract can enhance RUNX2 and Osterix expression during orthodontic tooth movement in vivo. *J Pharm Pharmacogn Res* 2020; 8(4): 290-298.
7. Katsumata Y, Kanzaki H, Honda Y, Tanaka T, Yamaguchi Y, Itohiya K, et al. Single local injection of epigallocatechin gallate-modified gelatin attenuates bone resorption and orthodontic tooth movement in mice. *Polymers (Basel)* 2018;10(12):1384.
8. Megat Badarul Hisham PB, Narmada IB, Alida A, Rahmawati D, Nugraha AP, Putranti NA. Effects of Vitamin D in Alveolar Bone Remodeling on Osteoblast Numbers and Bone Alkaline Phosphatase Expression in Pregnant Rats During Orthodontic Tooth Movement. *J Orofac Sci* 2019;11:79-83.
9. Narmada IB, Husodo KRD, Ardani IGA, Rahmawati D, Nugraha AP, Iskandar RPD. Effect of Vitamin D during Orthodontic Tooth Movement on Receptor Activator of Nuclear Factor Kappa- Ligand Expression and Osteoclast Number in Pregnant Wistar Rat (*Rattus norvegicus*). *J Krishna Instit Med Sci Univ* 2019; 8(1):37-42.
10. Chen ST, Kang L, Wang CZ, Huang PJ, Haung HT, et al. (-)-Epigallocatechin-3-Gallate Decreases Osteoclastogenesis via Modulation of RANKL and Osteoprotegerin. *Molecules* 2019;24(1):156.
11. Shen CL, Yeh JK, Cao JJ, Chyu MC, Wang JS. Green tea and bone health: Evidence from laboratory studies. *Pharmacol Res* 2011; 64(2):155–161.
12. Shen CL, Han J, Wang S, Chung E, Chyu MC, Cao JJ. Green tea supplementation benefits body composition and improves bone properties in obese female rats fed with high-fat diet and caloric restricted diet. *Nutr Res* 2015;35(12):1095-105.
13. Shen CL, Brenda JS, Jiliang L, Jay JC, Xiao S, Maria FN, et al. Effect of long-term green tea polyphenol supplementation on bone architecture, turnover, and mechanical properties in middle-aged ovariectomized rats. *Calcif Tissue Int* 2019;104(3):285-300.
14. Chim SM, Tickner J, Chow ST, Kuek V, Guo B, Zhang G, et al. Angiogenic factors in bone local environment. *Cytokine Growth Factor Rev*. 2013; 24(3):297-310.
15. Hankenson KD, Dishowitz M, Gray C, Schenker M. Angiogenesis in bone regeneration. *Injury* 2011; 42(6):556–561.
16. Filipowska J, Tomaszewski KA, Nied wiedzki Ł, Walocha JA, Nied wiedzki T. The role of vasculature in bone development, regeneration and proper systemic functioning. *Angiogenesis* 2017;20(3):291-302.
17. Saran U, Piperni G, Chatterjee S. Role of angiogenesis in bone repair. *Arch Biochem Biophys* 2014; 561:109-17.
18. Lafage-Proust MH, Roche B, Langer M, Cleret D, Vanden BA, Olivier T, et al. Assessment of bone vascularization and its role in bone remodeling. *Bonekey Rep* 2015;4:662.
19. Rahmawati D, Roestamadji RI, Yuliati A, Bramantoro T. Osteogenic ability of combined hematopoietic stem cell, hydroxyapatite graft and platelet rich fibrin on rats (*Rattus norvegicus*). *J Krishna Instit Med Sci Univ* 2017; 6(4):88-95.
20. Crotti TN, Dharmapatri AASSK, Alias E, Haynes DR. Osteoimmunology: major and costimulatory pathway expression associated with chronic inflammatory induced bone loss. *J Immunol Res* 2015; 281287:1-13.
21. Seo HR, Jeong HE, Jo HJ, Choi SC, Park CY, Kim JH, et al. Intrinsic FGF2 and FGF5 promotes angiogenesis of human aortic endothelial cells in 3D microfluidic angiogenesis system. *Sci Rep* 2016; 6(28832):1-11.
22. Patil AK, Shetty AS, Setty S, Thakur S. Understanding the advances in biology of orthodontic tooth movement for improved ortho-perio interdisciplinary approach. *J Indian Soc Periodontol* 2013;17(3):309-318.
23. Asiry MA. Biological aspects of orthodontic tooth movement: A review of literature. *Saudi J Biol Sci* 2018; 25(6):1027-1032.
24. Krishnan V, Davidovitch Z. Cellular, molecular, and tissue-level reactions to orthodontic force. *Am J Orthod Dentofac Orthop* 2006; 129(4):1-32.

*Author for Correspondence: Prof. Dr. Ida Bagus Narmada, DDS, Orthodontics Department, Faculty of Dental Medicine, Airlangga University, Mayjend Prof. Dr. Moestopo 47, 60132-Surabaya, East Indonesia
Email: ida-b-n@fkg.unair.ac.id Phone: +62315030255