


LAMPIRAN



Lampiran 1.

Klasifikasi Tumor Susunan Saraf Pusat berdasarkan WHO tahun 2007

TUMOURS OF NEUROEPITHELIAL TISSUE

Astrocytic tumours

Piloicytic astrocytoma	9421/1*
Piloxyoid astrocytoma	9425/2*
Subependymal giant cell astrocytoma	9384/1
Pleomorphic xanthoastrocytoma	9424/3
Diffuse astrocytoma	9400/3
Fibrillary astrocytoma	9420/3
Gemistocytic astrocytoma	9411/3
Protoplasmic astrocytoma	9410/3
Anaplastic astrocytoma	9401/3
Glioblastoma	9440/3
Giant cell glioblastoma	9441/3
Gliosarcoma	9442/3
Gliomatosis cerebri	9381/2

Oligodendroglial tumours

Oligodendroglioma	9450/3
Anaplastic oligodendroglioma	9451/3

Oligoastrocytic tumours

Oligoastrocytoma	9382/3
Anaplastic oligoastrocytoma	9382/3

Ependymal tumours

Subependymoma	9383/1
Myxopapillary ependymoma	9394/1
Ependymoma	9391/3
Cellular	9391/3
Papillary	9393/3
Clear cell	9391/3
Tanyctic	9391/3
Anaplastic ependymoma	9392/3

Choroid plexus tumours

Choroid plexus papilloma	9390/0
Atypical choroid plexus papilloma	9390/1*
Choroid plexus carcinoma	9390/3

Other neuroepithelial tumours

Astroblastoma	9490/3
Chordoid glioma of the third ventricle	9444/1
Angiocentric glioma	9427/1*

Neuronal and mixed neuronal-gliai tumours

Dysplastic gangliocytoma of cerebellum (Lhermitte-Duclos)	9493/0
Desmoplastic infantile astrocytoma/ganglioglioma	9412/1
Dysembryoplastic neuroepithelial tumour	9413/0
Gangliocytoma	9492/0
Ganglioglioma	9505/1
Anaplastic ganglioglioma	9505/3
Central neurocytoma	9506/1
Extra-ventricular neurocytoma	9506/1*
Cerebellar liponeurocytoma	9508/1*
Papillary glioneuronal tumour	9509/1*
Rosette-forming glioneuronal tumour of the fourth ventricle	9509/1*
Paraganglioma	8680/1

Tumours of the pineal region

Pineocytoma	9361/1
Pineal parenchymal tumour of intermediate differentiation	9362/3
Pineoblastoma	9362/3
Papillary tumour of the pineal region	9395/3*

Embryonal tumours

Medulloblastoma	9470/3
Desmoplastic nodular medulloblastoma	9471/3
Medulloblastoma with extensive nodularity	9471/3*
Anaplastic medulloblastoma	9474/3*
Large cell medulloblastoma	9474/3
CNS primitive neuroectodermal tumour	9473/3
CNS Neuroblastoma	9500/3
CNS Ganglioneuroblastoma	9490/3
Medulloblastoma	9501/3
Ependymoblastoma	9392/3
Atypical teratoid / rhabdoid tumour	9508/3

TUMOURS OF CRANIAL AND PARASPINAL NERVES

Schwannoma (neurileioma, neurinoma)	9560/0
Cellular	9560/0
Plexiform	9560/0
Melanotic	9560/0

Neurofibroma	9540/0
Plexiform	9550/0

* Microscopic code of the International Classification of Diseases for Oncology (ICD-O) (3rd ed) (944) and the Systematic Nomenclature of Neoplasms (2nd revised edn, Geneva, in collaboration with the World Health Organization) are used for the classification of neoplasms.

* The italicized numbers are provisional codes proposed for the 4th edition of ICD-O, which they are expected to be incorporated into the next ICD-O edition. They currently remain subject to change.

Perineuroma	
Perineuroma, NOS	9571/0
Malignant perineuroma	9571/3
Malignant peripheral nerve sheath tumour (MPNST)	
Epithelioid MPNST	9540/3
MPNST with mesenchymal differentiation	9540/3
Melanotic MPNST	9540/3
MPNST with glandular differentiation	9540/3

TUMOURS OF THE MENINGES

Tumours of meningotheial cells

Meningioma	9590/0
Meningothelial	9591/0
Fibrous (fibroblastic)	9592/0
Transitional (mixed)	9597/0
Psammomatous	9593/0
Angiomatous	9594/0
Microcystic	9590/0
Secretory	9590/0
Lymphoplasmacyte-rich	9590/0
Metaplastic	9590/0
Chordoid	9598/1
Clear cell	9598/1
Atypical	9599/1
Papillary	9598/1
Rhabdoid	9598/3
Anaplastic (malignant)	9590/3

Mesenchymal tumours

Lipoma	8850/0
Angiolipoma	8861/0
Hibernoma	8880/0
Liposarcoma	8850/3
Solitary fibrous tumour	8815/0
Fibrosarcoma	8810/3
Malignant fibrous histiocytoma	8890/3
Leiomyoma	8890/0
Leiomyosarcoma	8890/3
Rhabdomyoma	8900/0
Rhabdomyosarcoma	8900/3
Chondroma	9220/0
Chondrosarcoma	9220/3
Osteoma	9180/0
Osteosarcoma	9180/3
Osteochondroma	9210/0
Haemangioma	9120/0
Epithelioid haemangioendothelioma	9133/1

Haemangiopericytoma	9150/1
Anaplastic haemangiopericytoma	9150/3
Angiosarcoma	9120/3
Kaposi sarcoma	9140/3
Ewing sarcoma - PNET	9364/3

Primary melanocytic lesions

Diffuse melanocytosis	9728/0
Melanocytoma	9728/1
Malignant melanoma	8720/3
Meningeal melanomatosis	9728/3

Other neoplasms related to the meninges

Haemangioblastoma	9161/1
-------------------	--------

LYMPHOMAS AND HAEMATOPOIETIC NEOPLASMS

Malignant lymphomas	9590/3
Plasmacytoma	9731/3
Granulocytic sarcoma	9990/3

GERM CELL TUMOURS

Germioma	9064/3
Embryonal carcinoma	9070/3
Yolk sac tumour	9071/3
Choriocarcinoma	9100/3
Teratoma	9080/1
Mature	9080/0
Immature	9080/3
Teratoma with malignant transformation	9084/3
Mixed germ cell tumour	9085/3

TUMOURS OF THE SELLAR REGION

Craniopharyngioma	9350/1
Adamantinomatous	9351/1
Papillary	9352/1
Granular cell tumour	9582/0
Pituitoma	9432/1
Soluble cell oncocyoma of the adenohypophysis	8291/0

METASTATIC TUMOURS

Lampiran 2. Grading Tumor Susunan Saraf Pusat berdasarkan WHO

	I	II	III	IV
Astrocytic tumours				
Subependymal giant cell astrocytoma	*			
Piloicytic astrocytoma	*			
Pilocytic astrocytoma		*		
Diffuse astrocytoma		*		
Pleomorphic xanthoastrocytoma		*		
Anaplastic astrocytoma			*	
Glioblastoma				*
Giant cell glioblastoma				*
Gliosarcoma				*
Oligodendroglial tumours				
Oligodendroglioma		*		
Anaplastic oligodendroglioma			*	
Oligoastrocytic tumours				
Oligoastrocytoma		*		
Anaplastic oligoastrocytoma			*	
Ependymal tumours				
Subependymoma	*			
Myxopapillary ependymoma	*			
Ependymoma		*		
Anaplastic ependymoma			*	
Choroid plexus tumours				
Choroid plexus papilloma	*			
Atypical choroid plexus papilloma		*		
Choroid plexus carcinoma			*	
Other neuroepithelial tumours				
Angiocentric glioma	*			
Choroid glioma of the third ventricle		*		
Neuronal and mixed neuronal-gliial tumours				
Gangliocytoma	*			
Ganglioglioma	*			
Anaplastic ganglioglioma			*	
Desmoplastic infantile astrocytoma and ganglioglioma	*			
Dysamorphic astrocytoma	*			
Dysamorphic astrocytoma with neuronal features	*			
Other tumours				
Central neurocytoma		*		
Extraventricular neurocytoma		*		
Conocytic liponeurocytoma		*		
Paraganglioma of the spinal cord	*			
Papillary glioneuronal tumour	*			
Radial glioneuronal tumour of the fourth ventricle	*			
Pineal tumours				
Pilocytoma	*			
Pineal parenchymal tumour of intermediate differentiation		*	*	
Pineoblastoma				*
Papillary tumour of the pineal region	*	*	*	*
Embryonal tumours				
Medulloepithelioma				*
CNS primitive neuroectodermal tumour (PNET)				*
Atypical teratoid / rhabdoid tumour				*
Tumours of the cranial and peripheral nerves				
Schwannoma	*			
Neurofibroma	*			
Plexinoma	*	*	*	*
Malignant peripheral nerve sheath tumour (MPNST)			*	*
Meningeal tumours				
Meningioma	*			
Atypical meningioma		*		
Anaplastic (malignant) meningioma			*	
Haemangiopericytoma		*		
Anaplastic haemangiopericytoma			*	
Hemangioblastoma	*			
Tumours of the sellar region				
Craniopharyngioma	*			
Granular cell tumour of the neurohypophysis	*			
Pituitary tumour	*			
Spiral cell oncocytoma of the adenohypophysis	*			

Lampiran 3. Rekapitulasi Data Sampel

No.	Nama	Sex	Umar (th)	No. RM	Lokasi Tumor	MR Spektroskopi							Histopatologi	
						Ch	Cr	NAA	Lip-Lac	Ck-Cr	Ch-NAA	NAA:Cr	Type Jaringan	Grade WHO
1	T	P	10	12211383	lobus temporo-parietal D	32752	3520	3552	2224	9.30	9.22	1.01	choroid plexus carcinoma	III
2	TH	P	11	12229504	fossa posterior	5392	1616	5232	3984	3.34	1.03	3.24	metuloblastoma, large cell/anaplastic type	IV
3	GM	L	9	12218182	cerebellum	32752	3904	5008	2608	8.39	6.54	1.28	metuloblastoma, classic	IV
4	WCS	L	10	12229994	fossa posterior	27168	12000	19040	8960	2.26	1.43	1.59	Pilocytic Astrocytoma	I
5	RBA	L	2	12252611	lobus temporooccipital S	2880	5120	4208	32752	0.56	0.68	0.82	intracerebral haemorrhage	
6	NUN	P	9	12244888	ventrikel IV	25488	7840	7856	6880	3.25	3.24	1.00	anaplastic ependymoma	III
7	ADAJ	L	4	12247628	ventrikel lateralis D	14928	11744	12608	7024	1.27	1.18	1.07	pilomyxoid astrocytoma	II
8	MRA	L	8	12260023	cerebellum	18912	1440	2192	2016	13.13	8.63	1.52	Metuloblastoma, NOS	IV
9	AS	L	8	12257252	cerebellum	32752	10944	5344	12112	2.99	6.13	0.49	Metuloblastoma, NOS	IV
10	NK	L	12	12263202	suprasella	13680	7104	9328	5232	1.93	1.47	1.31	Pilocytic Astrocytoma	I
11	RJ	P	10	12280414	lobus parietooccipital S	29584	13808	17952	1744	2.14	1.65	1.30	CNS PNET	IV
12	DAR	P	3	12284506	periventrikel	32752	4448	5536	14112	7.36	5.92	1.24	Atypical Teratoid Rhabdoid Tumor	IV
13	DYS	L	9	12280063	ventrikel IV	14768	4624	1632	2448	3.19	9.05	0.35	Metuloblastoma	IV
14	AKP	P	5	12300019	fossa posterior	32752	7408	3488	480	4.42	9.39	0.47	Metuloblastoma, NOS	IV
15	DPAN	P	10	12321380	ventrikel IV	27696	11008	6528	7872	2.52	4.24	0.59	Metuloblastoma, NOS	IV
16	SRAG	L	3	12325621	ventrikel IV	32752	12544	8528	3968	2.61	3.84	0.68	Metuloblastoma, Large Cell	IV
17	NMS	P	4	12151930	basal ganglia	11968	2448	1472	1568	4.89	8.13	0.60	Yolk Sac Tumor	
18	FTM	L	2	12333948	CPA	32752	5536	6560	2784	5.92	4.99	1.18	Metuloblastoma, NOS	IV
19	RRS	L	5	12336421	fossa posterior	32752	4096	6144	8016	8.00	5.33	1.50	Pilocytic Astrocytoma	I

No.	Nama	Sex	Umur (th)	No. RM	Lokasi Tumor	MR Spektroskopi								Histopatologi	
						Ch	Cr	NAA	Lip-Lac	Cr:Cr	Ch:NAA	NAA:Cr	Tipe Jaringan	Grade WHO	
20	NF	L	4	12327318	fossa posterior	32256	21664	26384	8992	1.49	1.22	1.22	Ependymoma	II	
21	BNN	P	11	12281959	temporoparietalis D	23088	6688	5136	8960	3.45	4.50	0.77	Clear cell ependymoma	II	
22	AIT	L	10	12355528	cerebellum	32288	4400	8368	3440	7.34	3.86	1.90	Pilocytic Astrocytoma	I	
23	MWT	P	9	12348150	lobus occipitoparietal	10560	8240	6496	11120	1.28	1.63	0.79	CNS PNET	IV	
24	SK	P	9	12363843	cerebellum	12368	6272	8720	5792	1.97	1.42	1.39	Pilocytic Astrocytoma	I	
25	RF	L	12	12406857	cerebellum	23904	4288	5888	3424	5.57	4.06	1.37	Medulloblastoma, classic	IV	
26	WPP	L	15	12402794	fossa cranii media kiri	9712	6272	7744	2944	1.55	1.25	1.23	Retinoblastoma, poorly diff		
27	AMS	L	13	12412756	subfalxine cerebri	32752	7776	4048	1952	4.21	8.09	0.52	Meningioma, transitional type	I	
28	AAIL	L	5	12431290	cerebellum D	3600	1168	1072	240	3.08	3.36	0.92	Medulloblastoma Nodular	IV	
29	FAPS	L	8	12429576	lobus temporoparietalis S	7520	3488	2720	6480	2.16	2.76	0.78	Glioblastoma	IV	
30	ABA	L	16	12442257	suprasella	8720	6368	8736	11840	1.37	1.00	1.37	Immature (malignant) teratoma	III	
31	IR	L	18	12447519	Thalamus, hipotalamus	17344	6224	3312	2000	2.79	5.24	0.53	Pilocytic Astrocytoma	I	
32	NHA	P	4	12449648	chiasma opticum	17600	4272	2992	3168	4.12	5.88	0.70	Pilocytic Astrocytoma	I	
33	MRM	L	7	12456221	pineal	2576	5680	4160	4560	0.45	0.62	0.73	Yolk sac Tumor		

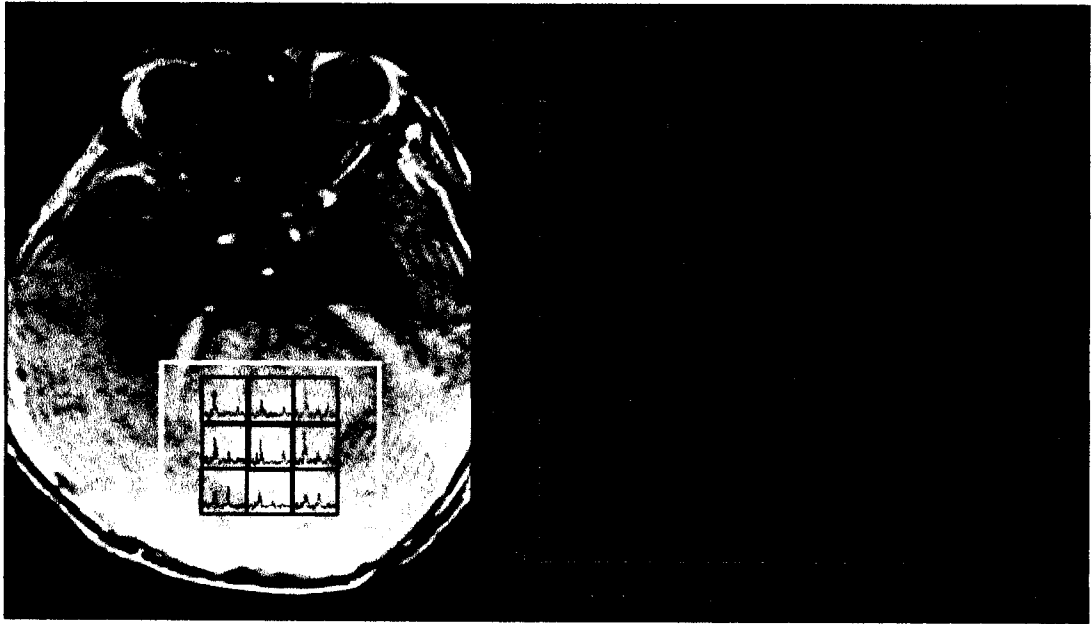
Lampiran 4. Contoh kasus Meduloblastoma

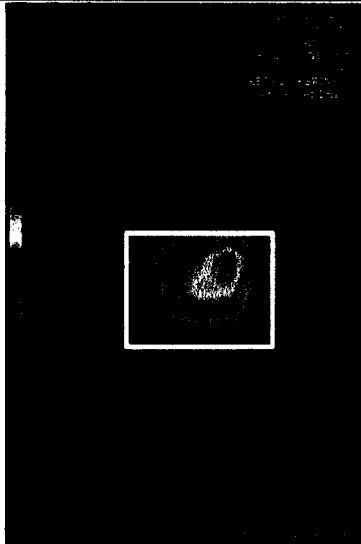

Anak perempuan, 8 tahun

MRI: massa solid intaaxial di vermis cerebelli yang mendesak ventrikel IV dan pons ke anterior

MRS: tampak peningkatan Ch/Cr, Ch/NAA, penurunan NAA/Cr, tampak puncak laktat

Histopatologi: Meduloblastoma, NOS (WHO *grade IV*)






Lampiran 5. Contoh kasus Pilocystic astrocytoma

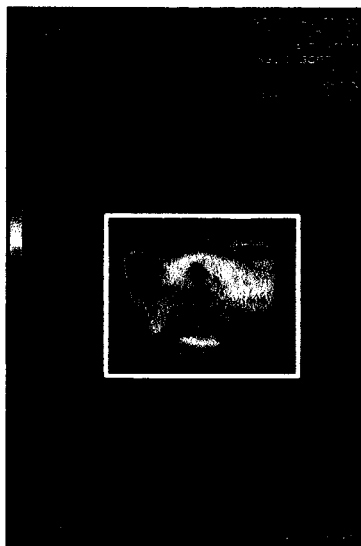


Laki-laki, 10 tahun

MRI: *Strong enhancing intra axial solid cystic lesion* pada vermis cerebelli yang menekan ventrikel III, IV, meluas sampai pada pons, medula oblongata dan pedunculi cerebri

MRS: tampak peningkatan Ch/Cr, Ch/NAA, penurunan NAA/Cr

Histopatologi: *pilocytic astrocytoma* (WHO grade I)






Lampiran 6. Contoh kasus CNS PNET



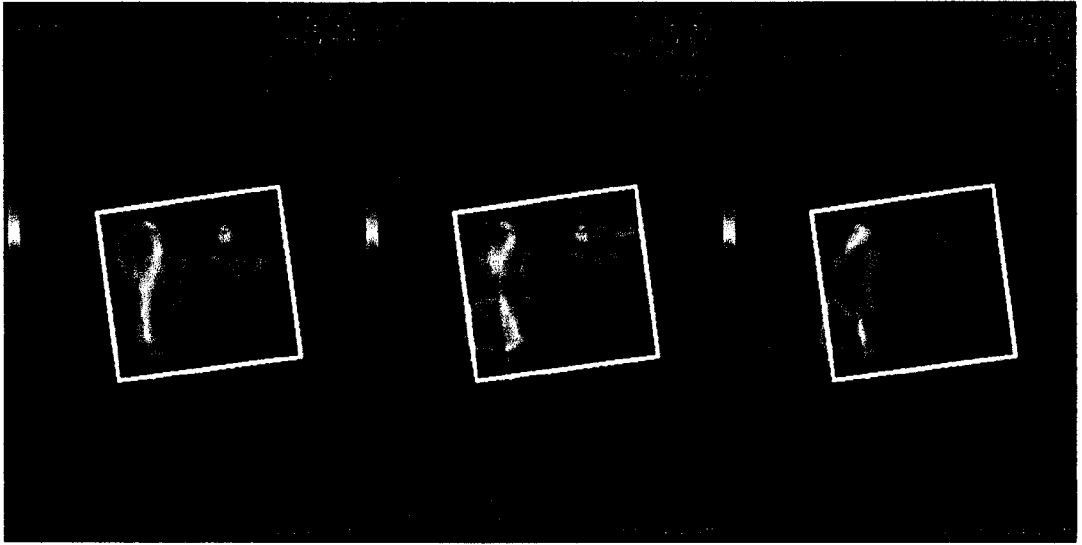
Perempuan, 10 tahun

MRI: *heterogenous enhancing solid cystic mass* di perietooccipital kiri; mengenai pineal body, thalamus dan subcortical parietooccipital kiri; mendesak ventrikel lateralis kiri, III menyebabkan *communicating hydrocephalus* serta *midline shift*

MRS: tampak peningkatan Ch/Cr, Ch/NAA, penurunan NAA/Cr

Histopatologi: CNS PNET





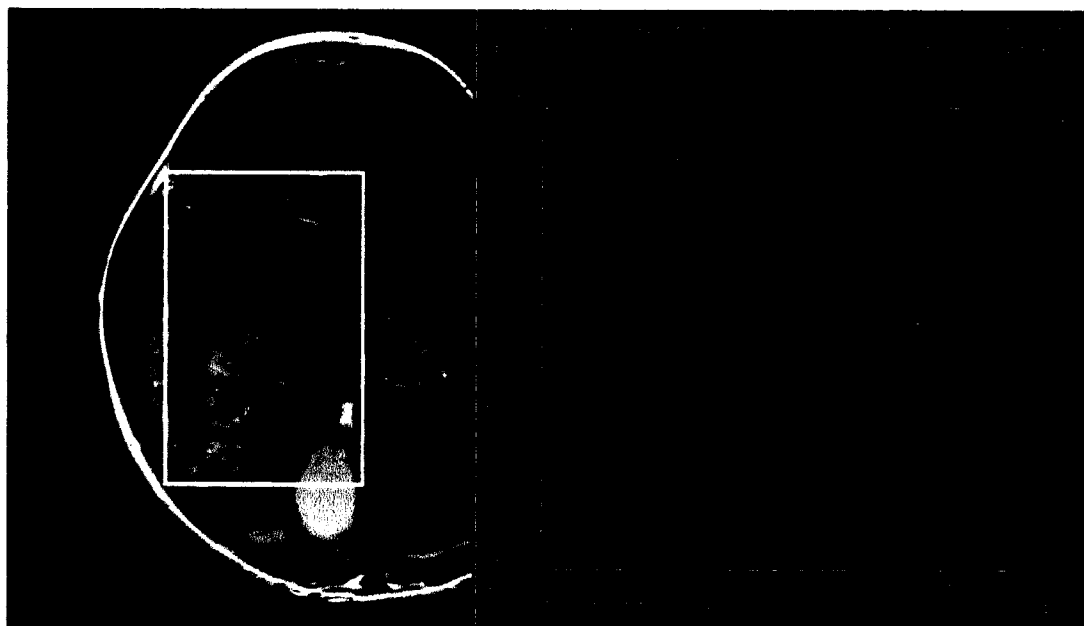
Lampiran 7. Contoh kasus Atypical Teratoid Rhabdoid tumor

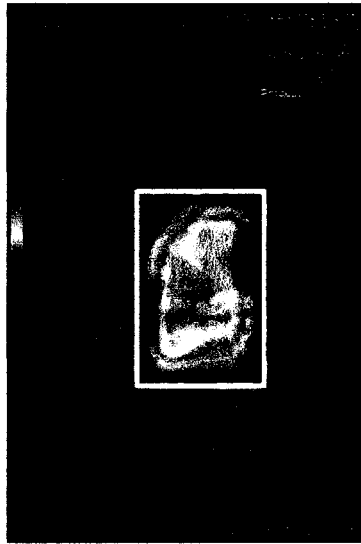
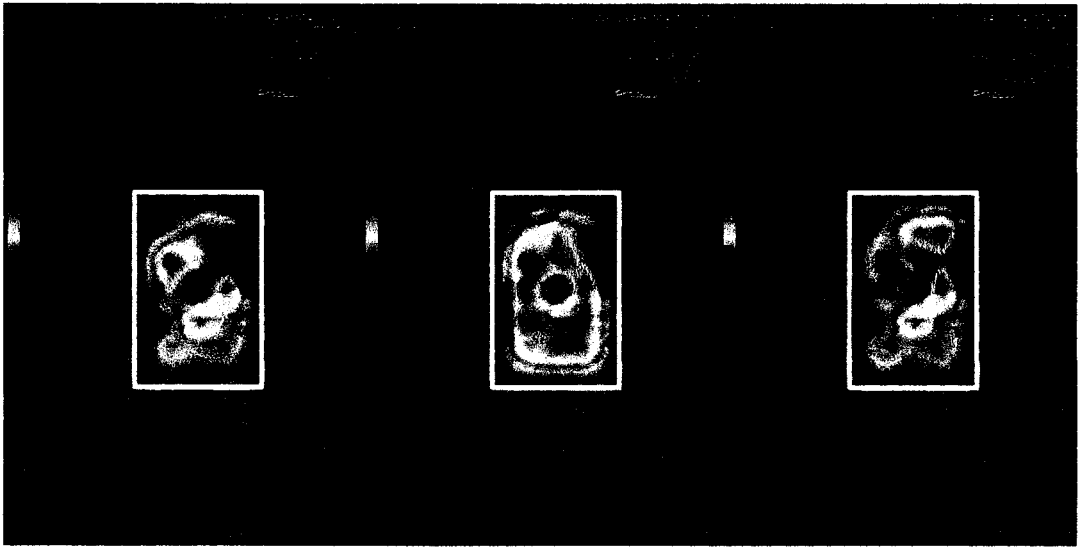
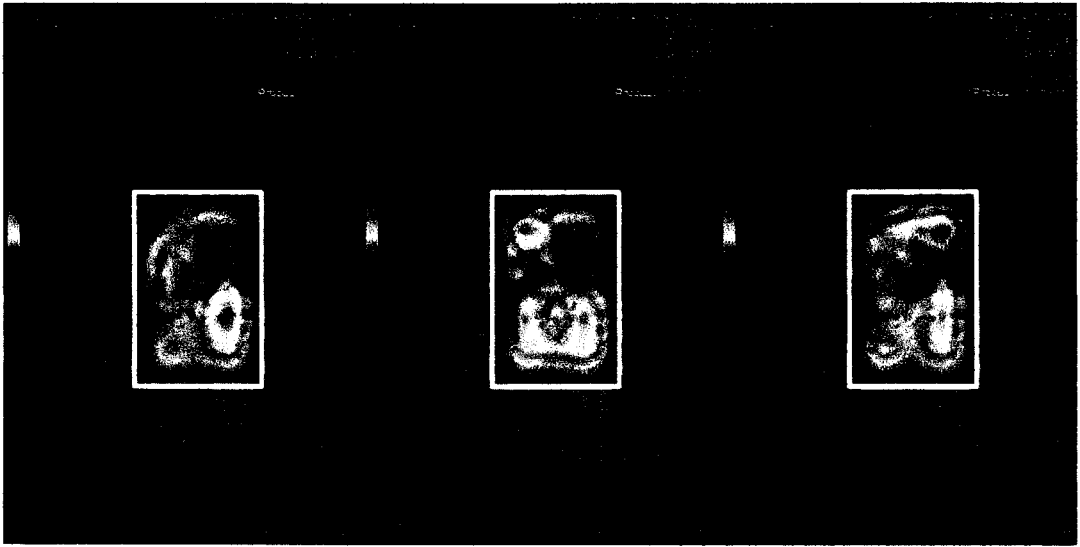Perempuan, 3 tahun

MRI: *heterogenous enhancing solid cystic mass di periventrikel disertai intratumoral hemorrhage* DD PNET, *choroid plexus carcinoma, central neurocytoma*

MRS: tampak peningkatan Ch/Cr, Ch/NAA, penurunan NAA/Cr, peningkatan lip-lac

Histopatologi: *Atypical Teratoid Rhabdoid Tumor*






Lampiran 8. Contoh kasus Meningioma




Laki-laki, 13 tahun

MRI: massa ekstraaksial di *subfalcine* cerebri anterior yang mendesak corpus callosum, cornu anterior ventrikel lateralis ke inferior dan lobus frontalis kanan kiri ke lateral disertai *non communicating hydrocephalus* DD 1. *Lymphoma maligna*, 2. neuroblastoma (PNET) 3. Meningioma


MRS: tampak peningkatan Ch/Cr, Ch/NAA, penurunan NAA/Cr

Histopatologi: meningioma, *transitional type* (WHO grade I)





Lampiran 9. Sertifikat Kelaikan Etik



**KOMITE ETIK PENELITIAN KESEHATAN
RSUD Dr. SOETOMO SURABAYA**

**KETERANGAN KELAIKAN ETIK
(" ETHICAL CLEARANCE ")**

176 / Panke.KKE/ III/ 2016

KOMITE ETIK RSUD Dr. SOETOMO SURABAYA TELAH MEMPELAJARI SECARA SEKSAMA RANCANGAN PENELITIAN YANG DIUSULKAN, MAKA DENGAN INI MENYATAKAN BAHWA PENELITIAN DENGAN JUDUL :

" Korelasi MR Spektroskopi dengan Hasil Histopatologi pada Tumor Intrakranial Anak "

PENELITI UTAMA: Erika Soebekti, dr

**PENELITI LAIN : 1. Dr. Anggraini Dwi Sensusiati, dr., Sp. Rad (K)
2. dr. Sudjarmiko, Sp. B - KBD**

UNIT/ LEMBAGA/ TEMPAT PENELITIAN : RSUD Dr. Soetomo Surabaya

DINYATAKAN LAIK ETIK

