



Source details

Dermatology Reports

Open Access ⓘ

Scopus coverage years: from 2010 to Present

Publisher: PagePress

ISSN: 2036-7392 E-ISSN: 2036-7406

Subject area: Medicine: Dermatology

Source type: Journal

CiteScore 2021

0.9 ⓘ

SJR 2021

0.208 ⓘ

SNIP 2021

0.281 ⓘ

[View all documents >](#)

[Set document alert](#)

[Save to source list](#)

[CiteScore](#) [CiteScore rank & trend](#) [Scopus content coverage](#)

i Improved CiteScore methodology ⓘ

CiteScore 2021 counts the citations received in 2018-2021 to articles, reviews, conference papers, book chapters and data papers published in 2018-2021, and divides this by the number of publications published in 2018-2021. [Learn more >](#)

CiteScore 2021 ▾

$$0.9 = \frac{111 \text{ Citations 2018 - 2021}}{128 \text{ Documents 2018 - 2021}}$$

Calculated on 05 May, 2022

CiteScoreTracker 2022 ⓘ

$$0.9 = \frac{146 \text{ Citations to date}}{157 \text{ Documents to date}}$$

Last updated on 05 October, 2022 • Updated monthly

CiteScore rank 2021 ⓘ

Category	Rank	Percentile
Medicine		
Dermatology	#91/126	28th

[View CiteScore methodology >](#) [CiteScore FAQ >](#) [Add CiteScore to your site ↗](#)

About Scopus

[What is Scopus](#)

[Content coverage](#)

[Scopus blog](#)

[Scopus API](#)

[Privacy matters](#)

Language

[日本語版を表示する](#)

[查看简体中文版本](#)

[查看繁體中文版本](#)

[Просмотр версии на русском языке](#)

Customer Service

[Help](#)

[Tutorials](#)

[Contact us](#)

ELSEVIER

[Terms and conditions ↗](#) [Privacy policy ↗](#)

Copyright © Elsevier B.V. ↗. All rights reserved. Scopus® is a registered trademark of Elsevier B.V.

We use cookies to help provide and enhance our service and tailor content. By continuing, you agree to the use of cookies ↗.





SJR

Scimago Journal & Country Rank

Enter Journal Title, ISSN or Publisher Name

Home

Journal Rankings

Country Rankings

Viz Tools

Help

About Us



Advances in Civil Eng. Papers

Maximize the Impact, Reach & Visibility of Your Next Paper Publishing With Us

Hindawi

Dermatology Reports

COUNTRY

Italy



Universities and research institutions in Italy

SUBJECT AREA AND CATEGORY

Medicine
Dermatology

PUBLISHER

PagePress
Publications

H-INDEX

12

PUBLICATION TYPE

Journals

ISSN

20367392, 20367406

COVERAGE

2010-2021

INFORMATION

[Homepage](#)

[How to publish in this journal](#)

luigi.naldi@gised.it

Journal Cover Letter Templates

Open

SCOPE



clinics of all skin-related diseases are welcome. Dermatology Reports publishes original articles, reviews, brief reports and case reports.

Join the conversation about this journal

WA Blaster Anti Block dan Aman

WA Blaster Versi Paling Aman di Indonesia. Jaminan 99% Anti Ba Block.

Web Sender ID

Quartiles

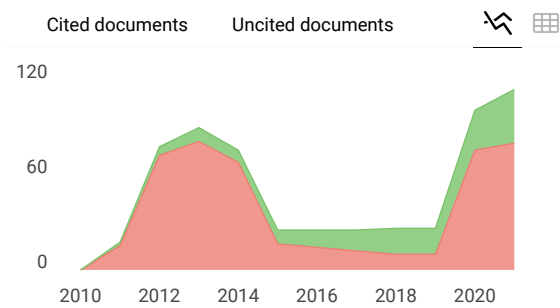
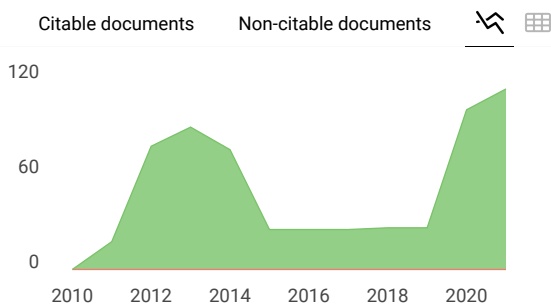
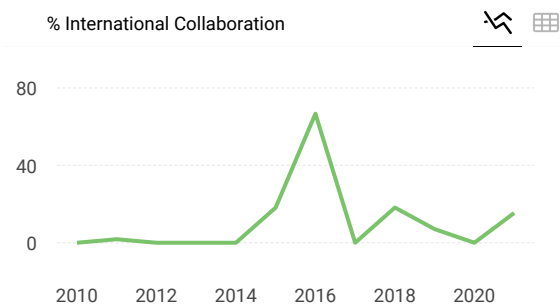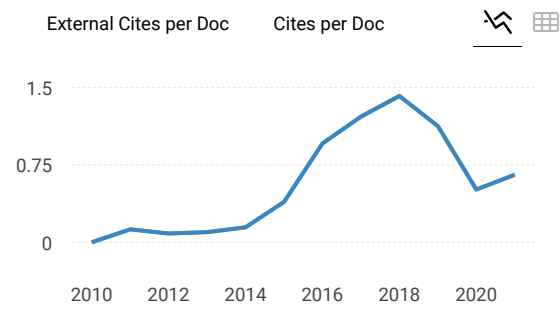
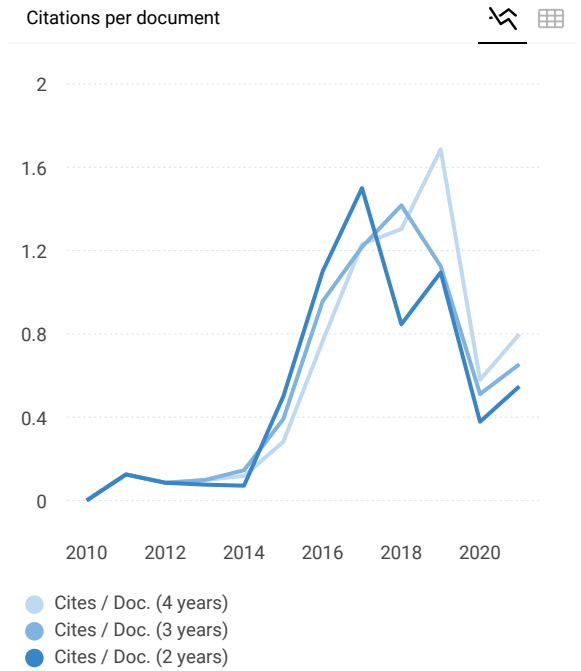
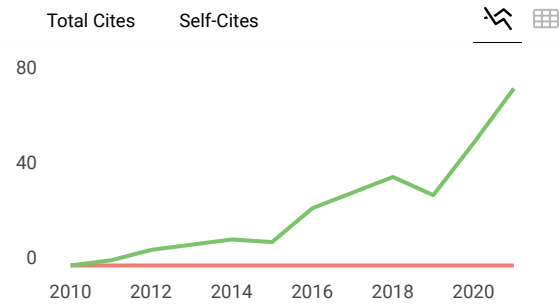
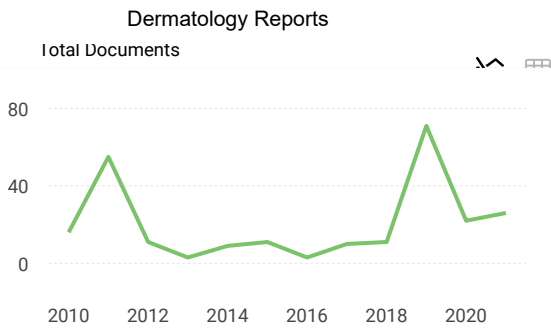
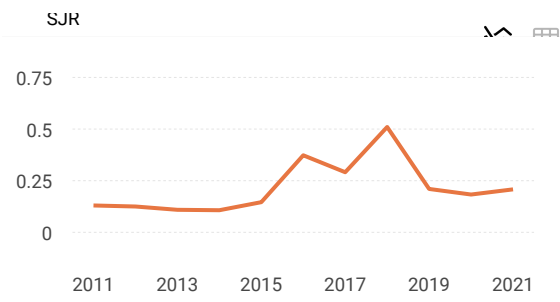
WA Blaster Anti Block dan Aman

WA Blaster Versi Paling Aman di Indonesia. Jaminan 99% Anti Ba Block.

Web Sender ID

FIND SIMILAR JOURNALS ?

<p>1 Indian Journal of Dermatology, Venereology IND</p> <p>75% similarity</p>	<p>2 International Journal of Dermatology GBR</p> <p>72% similarity</p>	<p>3 Dermatology Research and Practice EGY</p> <p>69% similarity</p>	<p>4 Dermatologi GBR</p> <p>6 s</p>
---	---	--	---



Dermatology Reports

Q3

Dermatology

best quartile

SJR 2021

0.21

powered by scimagojr.com

← Show this widget in your own website

Just copy the code below and paste within your html code:

```
<a href="https://www.scimaç
```



Explore, visually communicate and make



WA Blaster Anti Block dan Aman

WA Blaster Versi Paling Aman di Indonesia. Jaminan 99% Anti Ba Block.

Web Sender ID

Metrics based on Scopus® data as of April 2022

S **Samer Dhafer** 2 years ago

I'm proud to accept my article for publication in this highly esteemed journal..thanks to the editorial board. The process of evaluation and reviewing the manuscript was run in due time and the publication fee was reasonably affordable.

reply



Melanie Ortiz 2 years ago

SCImago Team

Dear Samer, thanks for your participation! Best Regards, SCImago Team

Leave a comment

Name

Email

(will not be published)



Submit

The users of Scimago Journal & Country Rank have the possibility to dialogue through comments linked to a specific journal. The purpose is to have a forum in which general doubts about the processes of publication in the journal, experiences and other issues derived from the publication of papers are resolved. For topics on particular articles, maintain the dialogue through the usual channels with your editor.

Developed by:



Powered by:



Follow us on @ScimagoJR

Scimago Lab, Copyright 2007-2022. Data Source: Scopus®

EST MODUS IN REBUS
Horatio (Satire 1,1,106)

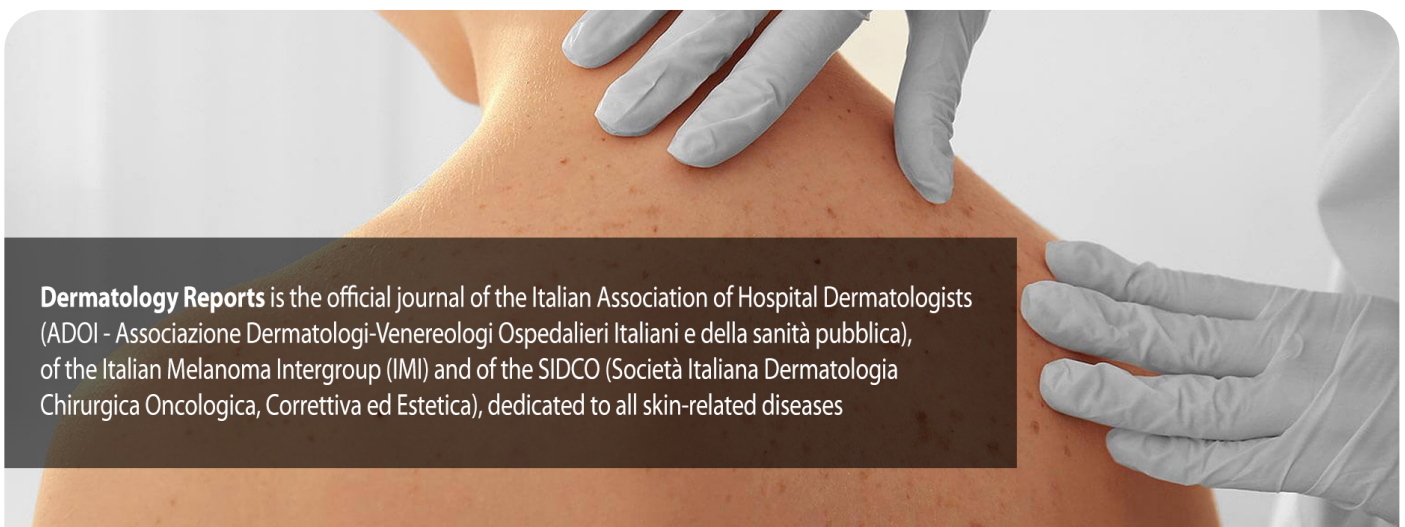Edit Cookie Consent



Dermatology Reports



[ABOUT THE JOURNAL](#) [EDITORIAL BOARD](#) [CURRENT ISSUE](#) [ARCHIVES](#) [EARLY ACCESS](#)



CASE OF THE MONTH / August 2022

En coup de sabre morphea: An uncommon condition in Africa

The term *en coup de sabre morphea* refers to a lesion of linear morphea typically located in the frontoparietal scalp and/or the paramedian forehead, often...

 <https://doi.org/10.4081/dr.2022.9537>



eISSN 2036-7406

EDITOR-IN-CHIEF

Luigi Naldi
Italy

DERMATOPATHOLOGY



Dermatology Reports
Volume 11, No s1, 2019 - Special Issue
for the 23rd Regional Conference of Dermatology (RCD)
Surabaya, Indonesia - 8-11 August, 2018



PERDOSKI - INDONESIAN SOCIETY OF DERMATOLOGY AND VENEREOLOGY (INSDV)



IKATAN DOKTER INDONESIA (IDI)/INDONESIAN MEDICAL ASSOCIATION



DR. SOETOMO GENERAL HOSPITAL, UNIVERSITAS AIRLANGGA, INDONESIA



Special Issue for the 23rd Regional Conference of Dermatology (RCD) 2018 incorporating with the 16th Annual Scientific Meeting of the Indonesian Society of Dermatology and Venereology

Table of Contents

ORIGINAL ARTICLES

<p>The role of protein-53 amyloid in determining the aggressiveness of basal cell carcinoma regulated by interleukin-6, myeloid cell leukemia-1 and basic fibroblast growth factor</p> <p>Prasetyadi Mawardi, Handono Kalim, Kusworini Handono Kalim, Loeki Enggar Fitri, Karyono Mintarjo, Ambar Mudigdo, Oyong Oyong, Brian Wasita.....1</p>	<p>Distribution of <i>Mycobacterium leprae</i> genotypes from Surabaya and Bandung Clinical Isolates by Multiple Locus Variable Number of Tandem Repeat Analysis</p> <p>Cita Rosita Sigit Prakoeswa, Bayu Bijaksana Rumondor, Lina Damayanti, Muljaningsih Sasmojo, Dinar Adriaty, Medhi Denisa Alinda, Ratna Wahyuni, M. Yulianto Listiawan, Indropo Agusni, Shinzo Izumi.....14</p>
<p>The efficacy of skin care products containing glutathione in delivering skin lightening in Indonesian women</p> <p>Kristiana Etnawati, Dwi Retno Adiwarni, Devi Artami Susetiati, Yusuke Sauchi, Hitomi Ito.....4</p>	<p>Potential for serodiagnosis of Indonesian leprosy patients by detecting antibodies against LID-1</p> <p>Nanny Herwanto, Sawitri, Cita Rosita Sigit Prakoeswa, Shinzo Izumi, Malcolm S. Duthie, Indropo Agusni19</p>
<p>Effect of country of origin image, product knowledge, brand familiarity to purchase intention Korean cosmetics with information seeking as a mediator variable: Indonesian women's perspective</p> <p>Emalia Diah Augusta, Dien Mardhiyah, Tika Widiastuti.....7</p>	<p>The role of beluntas (<i>pluchea indica</i> less.) leaf extract in preventing the occurrence of fibroblasts hyperproliferation: An <i>in vitro</i> preliminary study</p> <p>Sakti Charlia Maharani, Indah Julianto, Suci Widhiati22</p>
<p>Autologous non-cultured epidermal cell suspension combined with platelet rich fibrin for the treatment of stable vitiligo: A case series</p> <p>Adniana Nareswari, Dendy Zulfikar, Indah Julianto, Suci Widhiati11</p>	<p>Development of "Deskab" as an instrument to detect scabies for non-medical personnel in Indonesia</p> <p>Sandra Widaty, Roro Inge Ade Krisanti, Rahadi Rihatmadja, Eliza Miranda, Melani Marissa, Matahari Arsy, Danny Surya, Mufqi Priyanto, Sri Linuwih Menaldi.....25</p>

***Mycobacterium leprae* deoxyribonucleic acid positivity on skin lesion of untreated leprosy patients and its route to the skin surface**

Endi Novianto, Patricsia Manalu, Benny Effendi Wiryadi, Sri Linuwih Menaldi28

Immunoglobulin AMG Anti Natural Disaccharide Octyl - Leprosy IDRI Diagnostic (NDO-LID) Serologic Test for Leprosy Diagnosis: A Pilot Study

Bayu Bijaksana Rumondor, Anisha Callista Prakoeswa, Meva Nareza Trianita, Iswahyudi, Nanny Herwanto, M. Yulianto Listiawan, Indropo Agusni, Shinzo Izumi, Malcolm Duthie, Cita Rosita Sigit Prakoeswa31

Comparison amount of microphthalmia-associated transcription factor in vitiligo before and after narrowband-ultraviolet B therapy

M. Yulianto Listiawan, Linda Astari, Putri Hendria Wardhani35

Comparison between fractional Co2 laser-triamcinolone injection combination therapy and triamcinolone injection monotherapy for keloid

M. Yulianto Listiawan, Dwi Murtiastutik, Willy Sandhika, Brama Rachmantyo, Putri Hendria Wardhani38

Why are they hard to treat? A preliminary survey to predict important factors causing persistent scabies among students of religion-affiliated boarding schools in Indonesia

Rahadi Rihatmadja, Eliza Miranda, Melani Marissa Wicaksono, Sandra Widaty41

The relationship between skin phototype, gender, and stress level with the incidence of acne vulgaris among adolescents in Surakarta

Ardian Hendra Rezi Pamungkas, Flora Ramona Sigit Prakoeswa44

The efficacy and safety of fractional erbium yag laser combined with topical amniotic membrane stem cell (AMSC) metabolite product for facial rejuvenation: A controlled, split-face study

Ni Putu Susari Widianingsih, Trisniartami Setyaningrum, Cita Rosita S. Prakoeswa48

Sleep problems in 0-36 months old Indonesian children with atopic dermatitis

Irwanto, Hapsari W. Ningtiar, Taufiq Hidayat, Azwin M. Putera, Zahrah Hikmah, Anang Endaryanto53

A comparative study of Chicago Sky Blue and Parker™ ink blue black potassium hydroxide in the diagnosis of dermatophytes

Netty Sukmawati, Rahmadewi, Evy Ervianti56

Detection of *ureaplasma urealyticum* by polymerase chain reaction examination in nonspecific genital infection patients

Rahmadewi, Dian PH59

Profile of patients with tinea capitis

Siti Amira Venitarani, Samsriyaningsih Handayani, Evy Ervianti62

The effect of combination narrowband ultraviolet B phototherapy and vitamin D3 supplementation to increase serum 25-(OH)D levels in adult vitiligo patients

Reiva Farah Dwiwana, Fatima Aulia Khairani, Pufana Meidelia, Unwati Sugiri, Reti Hindritiani, Hendra Gunawan, Oki Suwarsa65

Is leukotriene B4 one of the keloid marker? A fibroblast keloid study

Yuli Kurniawati, Oki Suwarsa, Achadiyani, Sudigdo Adi68

Predictor factor of inguinal lymph node metastasis in men with penile cancer at Sanglah General Hospital, Denpasar, Bali

I. Wayan Yudiana, Gede Wirya Kusuma Duarsa, Anak Agung Gde Oka, Kadek Budi Santosa, Pande Wisnu Tirtayasa, Harmaya AK, Wahjoe Djatisoesanto71

Reading the history of venereal diseases in the city: Venereal disease from Surabaya, 19th-20th century

Moordiati75

A simpler diagnostic method using blood collection on filter paper to determine anti-natural octyl disaccharide-leprosy infectious disease research institute diagnostic in household contacts of leprosy patients

Meva Nareza Trianita, Bayu Bijaksana Rumondor, Anisha Callista Prakoeswa, Iswahyudi, Dinar Adriaty, Bagus Haryo Kusumaputra, Muhamad Yulianto Listiawan, Indropo Agusni, Shinzo Izumi, Malcolm Duthie78

The efficacy of vitamin D3 supplementation in increasing 25-hydroxyvitamin D levels in childhood vitiligo patients receiving 308-nm-excimer light phototherapy

Reiva Farah Dwiayana, Pramita K.C. Nugrahaini, D.P. Larasati, Inne Arline Diana, Reti Hindritiani, Hendra Gunawan, Oki Suwarsa81

Nongonococcal cervicitis: The most common cause of fluor albus in female sex workers

Afif Nurul Hidayati, Astindari, Maylita Sari, Dwi Murtiastutik, Sunarko Martodihardjo, Jusuf Barakbah84

Is insulin topical gel better than simvastatin topical gel in full thickness wound?

Timotius Hansen Arista, Agus Santoso Budi, Mirnasari Amirsyah, Nanda Febry Setyawati87

Causative drugs and HLA-B polymorphism in drug-induced Stevens-Johnson syndrome - toxic epidermal necrolysis: A study in five hospitals in Jakarta

Anesia Tania, Evita Halim Effendi, Inge Ade Krisanti, Yulia Ariani90

Hematological, hepatic, and renal adverse effects of high dose methotrexate injection (50 mg weekly) in severe psoriasis cases

Adissa Tiara Yulinvia, Prasta Bayu Putra, Niken Trisnowati, Sunardi Radiono93

The relationship between human leukocyte antigen-cw6 allele and psoriasis vulgaris

Sri Lestari KS, Eryati Darwin, Tjut Nurul Alam Jacob, Djong Hon Tjong96

Polymerase chain reaction chlamydia trachomatis examination in nonspecific genital infection patients

Dian Pertiwi Habibie, Dwi Murtiastutik, Rahmadewi100

Ph value of infant's skin is higher on diaper area compared to nondiaper area

Nadia Wirantari, Linda Astari, Iskandar Zulkarnain103

The Correlation of Ig M Anti PGL-1 Antibody between Blood Veins and Dried Capillary Blood on Filter Papers in Household Contact of Leprosy Patient

Anisha Calista Prakoeswa, Bayu Bijaksana Rumondor, Meva Nareza Trianita, Iswahyudi, Fatma Rosida, Linda Astari, M. Yulianto Listiawan, Indropo Agusni, Shinzo Izumi, Medhi Denisa Alinda106

Staphylococcus aureus colonization on antecubital non-exacerbated atopic dermatitis patient compared to healthy children

Nur Khamidah, Evy Ervianti, Hari Sukanto109

Cutaneous adverse drug reaction in Human Immunodeficiency virus patient associated with antiviral therapy: A retrospective study

Vidyani Adiningtyas, Cita Rosita Sigit Prakoeswa, Erwin Astha Triyono112

Neisseria gonorrhoeae resistance test against cefixime in gonorrhea patients in Surabaya

Amalia Rositawati, Sawitri, Afif Nurul Hidayati115

Urinary leukotriene e4 level profile in various degrees of severity in atopic dermatitis patients in dermatovenereology outpatient clinic Dr. Soetomo General Hospital, Surabaya: A descriptive study

Meita Ardini Pratamasari, M. Marsoedi Hoetomo, Afif Nurul Hidayati119

Genotyping of Human Papilloma Virus (HPV) in female condyloma acuminata patient in Dr. Soetomo Hospital, Surabaya

Afria Arista, Dwi Murtiastutik, Trisniartami Setyaningrum, Gondo Mastutik122

Profile of antiretroviral and its outcome on patients with HIV-AIDS in Wamena Public Hospital

Erwin Astha Triyono, Stefania Rany Seran, Didik Hasmono124

Urinary melatonin levels in children with atopic dermatitis and healthy controls

Dwi Ratna Adisty, Iskandar Zulkarnain, Diah Mira Indramaya129

CASE REPORTS

Importance of dermoscopy in diagnosis of tinea capitis: An evidence-based case report

Aninda Marina, Marsha Bianti, Sandra Widaty,
Eliza Miranda131

Fractional laser and laser assisted corticosteroid delivery for hypertrophic scars in thermal burns

Ni Putu Susari Widianingsih,
Cita Rosita S. Prakoeswa134

Mini punch graft for chronic leg ulcers, case series

Angela Mistralina Lukito,
Dinda Saraswati Murniastuti, Hajar Imtihani,
Niken Trisnowati,
Yohanes Widodo Wirohadidjojo.....136

The application of liposomal azelaic acid, 4-n butyl resorcinol and retinol serum enhanced by microneedling for treatment of malar pattern melasma: A case series

Arie Kusumawardani, Anggana Rafika Paramitasari,
Susanti Rosmala Dewi,
Ance Imelda Betaubun139

Hair removal treatment using 1,064 nm long-pulsed Nd:YAG laser in auricular post reconstruction of microtia patient: Two case reports

Kartika Ruchiatan, Erika Dewi Essary,
Reti Hindritiani, RM Rendy Ariezal Effendi,
Rani Septrina, Hendra Gunawan,
Oki Suwarsa.....142

Slow responder against methotrexate 50 mg intramuscular in severe psoriatic patients: A case series

Niken Kusumaningrum, Danar Wicaksono,
Dwi Retno Adi Winarni, Yohanes Widodo
Wirohadidjojo, Sunardi Radiono.....145

Subcutaneous phaeohyphomycosis: A rare case

Zahrudin Ahmad, Diah Mira Indramaya,
Yuri Widia, Sylvia Anggraeni, Linda Astari,
Evy Ervianti, Sunarso Suyoso149

Xeroderma pigmentosum with ocular involvement and squamous cell carcinoma: A case report

Bernadya Yogatri Anjuwita Saputri,
Iskandar Zulkarnain.....153

Scabies incognito

Nanny Herwanto, Hasnikmah Mappamasing,
Septiana Widiyanti, Trisiswati Indranarum,
Afif Nurul Hidayati, Sawitri, Evy Ervianti,
Dwi Murtiastutik, Sunarko Martodihardjo.....157

Decompression and gutter splint techniques to prevent recurrence in ingrowing toenails

Eva Krishna Sutedja, Vina Feriza,
Rachel Marsella Rahardjo, Dina Fatmasari,
Reti Hindritiani, Hendra Gunawan,
Oki Suwarsa.....160

Crusted scabies in systemic lupus erythematosus: More than a mite contagious case

Eva Lydiawati, Indropo Agusni, Dwi Murtiastutik,
Evy Ervianti, Sawitri, Trisiswati Indranarum,
Septiana Widyantari,
Hasnikmah Mappamasing163

***Aspergillus fumigatus* as an agent of cutaneous aspergillosis in immunocompetent patient: A rare case**

Trisniartami Setyaningrum,
Karina Dyahtantri Pratiwi166

A split-face of dermaroller and intradermal injection with the autologous platelet rich fibrin lysate in the treatment of exogenous ochronosis: A case series

Moerbono Mochtar, Sri Esa Ilona, Dendi Zulfikar,
Ammarilis Murastami, Suci Widhiati169

Dermoscopic evaluation of tinea capitis: A case report

Ade Fernandes, Yuri Widia, Sylvia Anggraeni,
Linda Astari, Evy Ervianti, Sunarso Suyoso.....173

Establishing the diagnosis neurofibromatosis type 1: A rare case

Dyatiara Devy, Damayanti176

A rare case report: Acquired vulva lymphangioma in a young female post tubercular lymphadenitis

Marissa Astari, Afif Nurul Hidayati178

Diffuse lepromatous leprosy caused by dual infection of mycobacterium leprae and mycobacterium lepromatosis: A case report

Ridha Ramadina Widiatma, Hari Sukanto180

Crusted scabies in patients with long-term use of oral corticosteroid with different underlying diseases – case series

Cut Shelma Maharani, Densy Violina Harnanti, Hasnikmah Mappamasing, Septiana Widyantari, Sawitri, Evy Ervianty, Dwi Murtiastutik, Sunarko Martodihardjo, M. Yulianto Listiawan183

Successful treatment of severe psoriasis vulgaris in child with methotrexate injection

Agatha Anindhita, Sawitri186

Serial case reports: Pregnancy with Lucio's phenomenon of leprosy in dr. Soetomo hospital, Surabaya

Nareswari I. Cininta, M.I.A. Akbar, Rozi A. Aryananda, Khanisyah E. Gumilar, Manggala Pascawardhana, Budi Wicaksono, Ernawati, Agus Sulistyono, Aditiawarman, Hermanto T. Joewono, M.N. Abdullah, Erry G. Dachlan189

Dermatology Reports



[ABOUT THE JOURNAL](#) [EDITORIAL BOARD](#) [CURRENT ISSUE](#) [ARCHIVES](#) [EARLY ACCESS](#)

[HOME](#) / [Editorial Board](#)

Editorial Board

Editor-in-Chief

Luigi Naldi (Vicenza, Italy)
luigi.naldi@gised.it

Associate Editors

Cesare Massone (Genova, Italy)
cesare.massone@gmail.com

Francesca Sampogna (Roma, Italy)
fg.sampogna@gmail.com

SIDCO Deputy Editors

Giulio Gualdi (Chieti, Italy)
giulioqualdi@libero.it

Section Editors

Case Reports

Paolo Sena (Bergamo, Italy)

Bruno Sassolas (Brest, France)

Dermatopathology

Gerardo Ferrara (Macerata, Italy)

Jean Kanitakis (Lyon, France)

Clinical Reviews

Carlo Cota (Ancona, Italy)

Ignacio García Doval (Vigo, Spain)

Procedural Dermatology and Dermatosurgery

Pier Luca Bencini (Milano, Italy)

Davide Melandri (Cesena, Italy)

Massimo Gattoni (Vercelli, Italy)

Imaging in dermatology

Enzo Errichetti (Udine, Italy)

Epidemiology/Clinical Research

Damiano Abeni (Roma, Italy)

Dennis Linder (Venezia, Italy)

Pediatric Dermatology

May El Hachem (Roma, Italy)

Andrea Sechi (Vicenza, Italy)

Cutaneous appendages

Vincenzo Bettoli (Ferrara, Italy)

Elena Pezzolo (Vicenza, Italy)

Melanoma and Dermato-Oncology

Ignazio Stanganelli (Meldola/FC, Italy)

Fabrizio Fantini (Lecco, Italy)

Psychodermatology

Anna Burroni (Genova, Italy)

Patient corner

Eugenia Caggese (Bergamo, Italy)

Giuseppe Formato (Campobasso, Italy)
Visnja Zaborski Breton (Ottawa, Canada)

Nursing

Daniela Ferrari (Vicenza, Italy)

Statistical advisor

Simone Cazzaniga (Bergamo, Italy)

Editorial Advisory Board

Lucia Brambilla (Milano, Italy)
Antonio Cristaudo (Roma, Italy)
Giuseppe Cianchini (Roma, Italy)
Anna Di Landro (Bergamo, Italy)
Ornella De Pità (Roma, Italy)
Luca Fania (Roma, Italy)
Michele Fimiani (Siena, Italy)
Giovanni Ghigliotti (Genova, Italy)
Giovanna Malara (Reggio Calabria, Italy)
Aldo Morrone (Roma, Italy)
Michele Pellegrino (Grosseto, Italy)
Francesca Romano (Napoli, Italy)
Michela Venturi (Cesena, Italy)
Vito Ingordo (Taranto, Italy)

ADOI Board of Directors

Francesco Cusano *President* (Benevento, Italy)
Cesare Massone *Vice-president* (Genova, Italy)
Leonardo Bianchi (Perugia, Italy)
Luca Fanà (Roma, Italy)
Giovanna Galdo (Avellino, Italy)
Paolo Iacovelli (Roma, Italy)
Davide Melandri (Cesena, Italy)
Michele Pellegrino (Grosseto, Italy)
Riccardo Sirna (Grosseto, Italy)

IMI Board of Directors

Ignazio Stanganelli (president) (Meldola/FC, Italy)

Daniela Massi (Firenze, Italy)

Pietro Quaglino (Torino, Italy)

Corrado Caracò (Napoli, Italy)

Virginia Ferraresi (Roma, Italy)

Antonio M. Grimaldi (Napoli, Italy)

Roberto Patuzzo (Milano, Italy)

Giuseppe Palmieri (Sassari, Italy)

Mario Mandalà (Bergamo, Italy)

Paola Queirolo (Milan, Italy)

Stefania Stucci (Bari, Italy)

SIDCO Board of Directors

Marco Dal Canton (President)

Gian Marco Vezzoni (Incoming President),

Marco Simonacci (Past President)

Maurizio Lombardo (Treasurer)

Fabrizio Fantini (Advisor, SIDCO ADOI Contact Person)

Andrea Paradisi (Advisor)

Paolo Sbano (Advisor)

Malvina Zanchi (Secretary)

FOR AUTHORS

SUBMIT YOUR PAPER

[Guide for Authors](#)

[Benefits for Authors](#)

[How to write a scientific paper](#)

[How to write a Review article](#)

[Article Processing Charge](#)

[Crediti ECM \(Italian Authors\)](#)

Comparison between fractional CO₂ laser-triamcinolone injection combination therapy and triamcinolone injection monotherapy for keloid

M. Yulianto Listiawan,¹
Dwi Murtiastutik,¹ Willy Sandhika,²
Brama Rachmantyo,¹
Putri Hendria Wardhani¹

¹Department of Dermatology and Venereology; ²Department of Anatomic Pathology, Faculty of Medicine, Airlangga University, Dr. Soetomo General Hospital, Surabaya, Indonesia

Abstract

The histopathologic view of keloid shows dense fibroblasts and bundles of collagen throughout dermis. Treatment that completely cure keloid still not exist, although there are many treatment options. The monotherapy fractional CO₂ laser shows good results, but is still as an adjuvant therapy. Fractional CO₂ laser affects fibroblast and its functions in producing collagen. The combination therapy will combine the selective photothermolysis effect of CO₂ lasers with antimitotic and antiinflammatory effects of corticosteroids. This study was an open trial with parallel design that compared fractional CO₂ laser-intralesional triamcinolone acetonide combination therapy (treatment group) and intralesional triamcinolone acetonide (control group) in keloid patients with collagen density as evaluation parameter. The dose of triamcinolone was 10 mg/ml of 0.05-0.1 ml/cm² of keloid. Fractional CO₂ laser energy setting was 10-20 mJ. The decrease of collagen density in control and treatment group was significant ($p=0.008$ and $p=0.001$), although the decrease difference between control and treatment group was not significant ($p=0.328$). The collagen density that decrease in a shorter time shows that fractional CO₂ laser could be a good combination therapy.

Introduction

Keloid is benign hyperplasia of the fibrous tissue of the skin. Keloid is scar tissue that grows beyond the border of the initial injury. Symptoms that can occur are pain and itching. The histopathologic view shows dense fibroblasts and bundles of col-

lagen appearing throughout the thickness of the dermis. Fibroblast apoptotic rate in the keloid is lower than in the normal skin.^{1,2} The excessive collagen is due to an imbalance between the formation and degradation of extracellular matrix.³⁻⁵ Keloid more affects African, Asian and Latin American ethnicities. Vulnerability genetically increases the risk of keloid 15% greater than in the population.⁴ Prevalence of keloid patients treated in Dermatovenereology Departement Dr. Soetomo Hospital Surabaya is 1.4% (83 patients) by 2013, 1.6% (80 patients) by 2014, and 1.5% (74 patients) by 2015. The number of patients is a combination of the number of new and old patients. Keloid can result in a physical and psychological problem. Physical problems may be itchy, rigid skin, scar contractures, and pain symptoms. Psychological problems include confidence disorders, impaired daily activities, anxiety, and depression.^{3,6} There is no single treatment modality that is considered superior for the treatment of keloids. Treatment that cure the keloid completely still do not exist, although there are many treatment options available.^{4,6}

First-line keloid therapy is intralesional corticosteroid injection, but give more results in small and early-stage keloid.⁷ Second-line therapy, surgical excision, needs to be considered if the keloid does not improve after first-line therapy for 12 months. Surgical therapy is not recommended as a single therapy because the high rate of keloid recurrence (50-100%), can even form a larger keloid of early keloids. Second-line therapy that can be used in addition to surgical excision is laser.^{1,3}

Intralesional triamcinolone acetonide injection therapy showed 50% -100% efficacy. The recurrence rate of this therapy reaches 33% in 1 year and 50% in 5 years.⁶ The Carbondioxide (CO₂) laser is an ablative laser, a continuous ablation effectively treating the keloid, but a long wound healing time of 4-8 weeks. The recurrence rate reached 92.3%. Continuous CO₂ laser followed by intralesional triamcinolone acetonide injection has better effectiveness than CO₂ laser therapy or triamcinolone acetonide monotherapy. The rate of keloid recurrence that received combination therapy is reduced to 15.4%.⁷ Fractional CO₂ lasers begin to be used for keloid because it has a shorter healing period. The monotherapy fractional CO₂ laser shows good results, without recurrence after one year. The study was a case series with 8 patients with hypertrophic scars and keloids. Fractional CO₂ lasers are still an adjuvant therapy because no studies have demonstrated the superiority of CO₂ lasers over intralesional triam-

Correspondence: Putri Hendria Wardhani, Department of Dermatology and Venereology, Faculty of Medicine, Airlangga University, Dr. Soetomo General Hospital, Surabaya, Indonesia.
Tel: +62315501609
E-mail: putri_h_w@yahoo.com

Key words: CO₂, keloid, laser, therapy, triamcinolone

Contributions: All the authors contributed equally.

Conflict of interest: The authors declare no potential conflict of interest.

Received for publication: 1 February 2119.
Accepted for publication: 11 February 2119.

This work is licensed under a Creative Commons Attribution-NonCommercial 4.0 International License (CC BY-NC 4.0).

©Copyright M.Y. Listiawan et al., 2019
Licensee PAGEPress, Italy
Dermatology Reports 2019; 11(s1):8032
doi:10.4081/dr.2019.8032

nolone acetonide injection.⁸

The combination therapy of fractional CO₂ laser with intralesional triamcinolone acetonid injection for the treatment of keloid has never been studied in Dr. Soetomo Hospital Surabaya. Fractional CO₂ laser is an ablative laser emitted in the form of laser light columns forming a microscopic treatment zone (MTZ). The MTZ is partially ablated area and the other part is still intact, allowing for a faster healing time compared to continuous CO₂ lasers.^{7,9} Fractional CO₂ laser affects fibroblast and its functions in producing collagen.¹⁰ The combination therapy will combine the selective photothermolysis effect of CO₂ lasers with the antimitotic and antiinflammatory effects of corticosteroids. Keloid to be studied excluding keloid in the face area. This research is expected to know the effectiveness of combination therapy of CO₂ fractional and injection of triamcinolone acetonid to keloid patient with collagen density parameter.

Materials and Methods

This study was an open trial with parallel design methods that compared combination therapy fractional CO₂ laser with intralesional triamcinolone acetonide (treatment group) and monotherapy intralesional triamcinolone acetonide (control group) in patients with keloids. The sample of the

study were all keloid patients who met the inclusion criteria, who underwent treatment at Skin Surgery Division Dermatoneurology Clinic of Dr. Soetomo Hospital Surabaya. The number of samples in the treatment group were 13 patients and in the control group were 13 patients. Data collection performed by filling the data collection sheet. Data were analyzed by using MANOVA (Multivariate Analysis of Variance) test.

The Inclusion criteria are keloid patients, including new and old keloid, age 15 - 64 years. Patients have not been treated with triamcinolone acetonide injections, if they have undergone such therapy it should be longer than 4 weeks after the last therapy. Patients with keloids who relapse after previous keloid therapy. The general condition of the patient is good. Willing to follow the research and sign the informed consent.

The exclusion criteria are patients with keloids on the face. Keloid size is more than 1% of skin surface area. Patients with systemic disease requiring immunosuppression therapy. (e.g. systemic lupus erythematosus and pemphigus). Patients with skin infections, diabetes mellitus, pregnancy, and breastfeeding. Patients who had been on CO₂ laser therapy for keloid in the last 6 months.

Biopsy was taken from the lesion area by using punch biopsy - 4 mm, before the biopsy was performed local anesthesia first, then the punch instrument was rotated while pressed to a sufficient depth. The tissue is lifted and released from the underlying skin tissue. Bleeding on the open wound was stopped. Biopsy performed 2 times, before and after therapy. The location of the initial biopsy in the middle of a keloid lesion. Final biopsy is taken in the same lesion, but in different locations. Collagen density is a proportion of collagen fiber in a one visual field of Masson's trichromestaining keloid slide with 400 times magnification.

Intralesional triamcinolone acetonide are performed according to the standard, using a 1 cc syringe and 25-gauge needle. The dose used is 10 mg/ml of 0.05-0.1 ml/cm² of keloid. Direct injection is done to the keloid mass with the needle pointing downward. Pressure to injection sites after injection is necessary to prevent drug fluids escaping from the lesions. Administration in 1 therapy did not exceed 30 mg. Therapy was done 2 times with a 3-week break.

Fractional CO₂ laser therapy is a CO₂ ablation laser therapy in fractional mode with 10-20 mJ energy. Less energy for older and soft lesions, larger for new and hard lesions. 2.5% lidocaine anesthetic cream and 2.5% prilocaine were applied and 1 hour occlusive before laser therapy, then removed shortly before laser was done. The

patient's eyes are covered with eye protector, doctors wear handschoen, masks, and protective goggles. Keloid is disinfected with 70% alcohol. The hand piece is directed perpendicular to the lesion, then the foot pedal is stepped on to fire the laser. The lesions were cooled with a cool, sterile 0.9% NaCl gauze. Treatment was performed in the treatment group 1 times before intralesional triamcinolone injection.

Results

This study involved more female patients than male patients, but the sex of the patients between the control group and the treatment was homogeneous ($p=0.694$). The largest number of patients by age is in the 15-24 age group. Results of age data processing of keloid patients obtained the youngest age is 18 years old and the oldest is 58 years. The age group of patients between the controls did not differ from treatment group with $p = 0.537$.

The shortest length of illness keloid in the study subjects was for 6 months and included in the group of 0.5-1 years of illness. Most research subjects suffer from keloid more than 4 years. The longest illness is 15 years. The homogeneity test showed that the length of keloid pain between the control group and the treatment group was not homogeneous. A total of 17 patients (65.4%) had already been on treatment for keloids, but only 9 of 26 patients (34.6%) were on standard treatment of triamcinolone acetonide injections.

The collagen density in the control and treatment group decreased significantly ($p=0.008$ & $p=0.001$, respectively), The average collagen density in the control group decreased from $85.15 \pm 4.40\%$ /visual field at the time before treatment to $79.46 \pm 7.98\%$ /visual field at 3 weeks after

the last treatment, while the mean collagen density at the treatment group decreased from $87.69 \pm 7.00\%$ /visual field at the time before therapy to $79.31 \pm 7.58\%$ /visual field at 3 weeks after the last treatment.

The decrease difference of collagen density between the control group and the treatment group was not significant (Table 1). The mean degradation of collagen density from pretreatment to post-treatment in the control group was $-5.69 \pm 6.41\%$ /visual field, whereas the mean decrease of collagen density from pretreatment to post-treatment in the treatment group was $-8.38 \pm 7.31\%$ /visual field. The mean difference of collagen density degradation between the two groups was -2.69 with $p=0.328$.

Discussion

This study is an open controlled clinical trial that aimed to compare the effectivity of CO₂ fractional laser and triamcinolone acetonide injections combination therapy with standard therapy of triamcinolone acetonide monotherapy. After 6 months sampling, 26 study participants fulfilled the inclusion criteria. Study participants who have been injected with triamcinolone acetonide should be longer than 4 weeks before the study begins. All of the enrolled study participants have not received a fractional CO₂ laser therapy. The studied keloid does not include the face, ears, and neck area. All study participants had good general conditions and did not have systemic disease.

The age of study participants was determined in the range of 15-64 years. No younger than 15 years old because of concern the patient can not cooperate during the research procedure. The age of 15 and above is also selected according to the WHO adult criteria.¹¹ Not older than 64

Table 1. Timeline of treatment schedule in research.

Initial visitation	Visitation II	Visitation III
Week 0	3 rd Week	6 th Week
Skin biopsy and lesion measurement of pre treatment, followed by CO ₂ laser (treatment group only), then injection of the 1 st triamcinolone	2 nd triamcinolone Injection	Skin biopsy and post treatment measurement of the lesion

Table 2. Result of analysis of difference of degradation of collagen density between control and treatment group using T-Test.

Decrease density of collagen	Mean (SD)	Difference	CI 95%	p value
Control group	-5.69(6.41)	-2.69	(-2,87)-(-8,26)	0.328

years-old because the invasive procedure of this study is feared to affect the general condition of the patient. The mean age of the subjects in this study was 29.4 years-old. Most participants were in the 15-24 year age group (53.8%), followed by the 25-34 year age group. Participants of female sex (57.7%) slightly more than men.

According to Chike-Obi *et al.* keloid can occur at all ages, the incidence is highest at the age of 11-30 years, and slightly more in women.² Age between the treatment group and the control group in this study did not differ significantly ($p=0.537$), and also the sex of the study subjects between the two study groups ($p=0.694$).

The duration of illness was not homogeneous between the control group and the treatment group, as there were patient who suffer keloid for 15 years in the treatment group. The patient was not excluded from the study because it met the inclusion criteria. The length of illness in study subjects varied from 6 months to 15 years. A total of 9 patients (34%) had ever undergone standard treatment, intralesional triamcinolone acetonide injections. A total of 4 patients are still undergoing several injection sessions, so there is no change from the initial condition. These patients complain of pain during the injection so they underwent the treatment regularly.¹²

Patients who did not undergo standard treatment will not get the maximum treatment result. There were 3 patients who had undergone surgical removal of keloid, then the three patients had keloid relapse. This is in accordance with the literature which states that keloid recurrence after excision is 45-100% if not accompanied by adjuvant therapy.¹²

Histopathological parameters were rare in the study of keloids, most of which were parameters of scar assessment scores.^{13,14} This study attempts to prove that triamcinolone acetonide and combination therapy can decrease the collagen density. Triamcinolone significantly decreased the collagen density in the control and combination therapy group, but the difference of degradation was insignificant (Table 1). It could be caused by the laser therapy in the combination therapy was performed only once and the evaluation time was only 6 weeks after treatment.

Triamcinolone acetonide in the both group suppresses fibroblast proliferation and enhance fibroblast degeneration, thus decrease collagen production. Triamcinolone acetonide also has vasoconstriction effect that diminish vascularization

to keloid.¹⁵ The fractional CO₂ lasers decrease the collagen density in a some ways. It enhance fibroblast proliferation, but diminish TGF- β that has pivotal role in collagen synthesis. It also shorten collagen fiber to one-third of initial length.¹⁰ The MTZ depth that formed by fractional CO₂ laser is about 400 μ m. The depth has reached the depth of papillary dermis, so that MTZ can be a depot and assist in the distribution of injected triamcinolone acetonide. The collagen density decreased more significant after fractional CO₂ laser-triamcinolone injection combination therapy in only 6 weeks follow up (1 laser and 2 times triamcinolone acetonide injection) than after triamcinolone injection alone. It suggest that the combination therapy gives a synergis effect.

Conclusions

The collagen density that decrease significantly in a shorter time shows that fractional CO₂ laser-triamcinolone acetonide injection could be a good combination therapy. Fractional CO₂ laser gives a synergis effect to intralesional triamcinolone acetonide injection. The combination therapy is an effective keloid therapy and may become the alternative for intralesional triamcinolone acetonide monotherapy. Intralesional triamcinolone acetonide monotherapy remains the manstays for keloid therapy, because the combination therapy still not showed a significant deference to triamcinolone acetonide injection monotherapy.

References

1. Ko CJ. Dermal hypertrophies and benign fibroblastic/myofibroblastic tumours. In: Goldsmith LA, Katz SI, Gilchrist BA, Paller AS, Leffell DJ, Wolff K, editors. Fitzpatrick's dermatology in general medicine. 8th ed. New York. Mc Graw Hill; 2012. p. 707-10.
2. Chike-Obi CJ, Cole PD, Brissett AE. Keloids: pathogenesis, clinical features, and management. *Semin Plast Surg* 2009; 23: 178-84.
3. Monstrey S, Middelkoop E, Vranckx JJ, et al. Updated scar management practical guidelines: non-invasive and invasive measures. *JPRAS* 2014; 67: 1017-25.
4. Butler PD, Longaker MT, Yang GP. Current progress in keloid research and treatment. *J Am Coll Surg* 2008; 206: 731-41.
5. Moshref SS, Mufti ST. Keloid and hypertrophic scar: comparative histopathological and immunohistochemical study. *JKAU Med Sci* 2010; 17: 3-22.
6. Khan MA, Bashir MM, Khan FA. Intralesional triamcinolone alone and in combination with 5-fluorouracil for the treatment of keloid and hypertrophic scars. *JPMA* 2014; 64: 1003-7.
7. Garg GA, Sao PP, Khopkar US. Effect of carbon dioxide laser ablation followed by intralesional steroids on keloids. *J Cutan Aesthet Surg* 2011; 4: 2-6.
8. Waibel JS, Wulkan AJ, Shumaker PR. Treatment of hypertrophic scars using laser and laser assisted corticosteroid delivery. *Lasers Surg Med* 2013; 45:135-40.
9. Listiawan MY. Fractional Photothermolysis in Laser. In: Lumintang H, Listiawan MY, Prakoeswa CRS, Bandem AW, editors. Recent Management of Dermatology in Daily Practice. Surabaya: Insan Cendekia; 2013. p. 41-54.
10. Tanzi EL, Alster TS. Ablative lasers, chemical peels, and dermabrasion. In: Goldsmith LA, Katz SI, Gilchrist BA, et al. Fitzpatrick's dermatology in general medicine. 8th ed. New York. Mc Graw Hill; 2012. p. 3021-31.
11. World Health Organization. International statistical classification of diseases and related health problems 10th revision. 4th ed. Geneva: WHO Press; 2011.
12. Robles DT, Berg D. Abnormal wound healing: keloids. *Clin Dermatol* 2007; 25: 26-32.
13. Sharquie KE, Noaimi AA, Al-Karhi MR. Debulking of keloid combined with intralesional injection of 5-fluorouracil and triamcinolone versus intralesional injection of 5-fluorouracil and triamcinolone. *JCDSA* 2014; 4: 85-91.
14. Draaijers LJ, Tempelman FR, Botman YA, et al. The patient and observer scar assessment scale: a reliable and feasible tool for scar evaluation. *Plast Reconstr Surg* 2004; 113: 1960-5.
15. Cruz NI, Korchin L. Inhibition of human keloid fibroblast growth by isotretinoin and triamcinolone acetonide in vitro. *Ann Plast Surg* 1994; 33: 401-5.