

# Case report of Malignant Lymphoma of The Breas

*by* Ami Ashariati

---

**Submission date:** 09-Jul-2020 09:00PM (UTC+0800)

**Submission ID:** 1355377627

**File name:** Case\_report\_of\_Malignant\_Lymphoma\_of\_The\_Breast.pdf (696.72K)

**Word count:** 3533

**Character count:** 18912

## The Cases of Malignant Lymphoma of the Breast

Ami Ashariati\*  
Ario Djatmiko\*\*  
Iskandar Ali\*\*  
Wiwien Ristanto\*\*  
Lies Mardiyana\*\*  
Sindravati\*\*

\*Department of Internal Medicine, Faculty of Medicine, Airlangga University, Dr.  
Soetomo Hospital, Surabaya

\*\*RS Onkologi Surabaya

### Abstract

Four cases of malignant lymphoma (ML) of the breast are discussed, diagnosed and managed. The first case is a 68 years old woman who had a left breast tumor. In the ultrasonogram (USG) revealed hypoechoic lesion in the left breast with FNA result of malignant lymphoma, but still differential diagnosis with Ductal Carcinoma Mamma. The second case is a 52 years old woman who had a left breast tumor. The USG revealed malignant lesion, left axilla node positive and FNA result was ductal carcinoma. The third case is a 51 years old woman, USG of the left breast revealed malignant lesion, left axilla node positive, and excision biopsy revealed non-Hodgkin's Lymphoma, diffuse large cell. The fourth case is a 51 years old woman, the USG revealed irregular hypoechoic lesions in both breasts and left supraclavicular node 5 mm. Core biopsy revealed bilateral breast non Hodgkin's lymphoma subcutaneous, T-cell lymphoma. In Immunohistochemistry showed CD3 : positive strong membrane staining in 30% of tumor cells, negative CD 20 expression, CD 30: positive membrane staining on few large cells, and Cytokeratin 7 was positive on normal gland epithel only.

### INTRODUCTION

Primary Breast Lymphoma (PBL) is a rare condition, accounting for only 0.04% to 0.5% of breast malignancies and less than 2% of extranodal lymphomas. Clinical presentation and imaging may suggest a benign condition. Reports of treatment vary widely. Although the adverse effect of mastectomy can be influenced by other confounding factors, radical surgery is at best unnecessary and should be avoided in Malignant Lymphoma (ML) of the breast. Ideally surgery should be limited to a biopsy to establish the correct histological diagnosis, leaving the treatment with curative intent to radiotherapy and chemotherapy. Chemotherapy with various agents is often used. Radiotherapy has been used in the adjuvant setting or as primary local therapy. Immunotherapy and radioimmunotherapy have shown some promise in other lymphomas and may be useful here as well. There is no standard or consensus of treatment for PBL.

## CASES REPORT

### Case#1 <sup>11</sup>

A 68-year-old woman presented with a mass in the lateral part of the left breast in October 2002. The patient had no contributory past or family history. Neither nipple discharge nor axillary lymphadenopathy was detected. An ultrasonogram (USG) of the left breast revealed hypoechoic lesion (Fig.1). A mammogram showed suspect malignant lesion in UOQ left breast with benign lesion lymphnode in left axilla. Results of a FNA of the tumor revealed high grade large B cell lymphoma. DD: Ductal carcinoma mamma. On admission, blood chemistry results, including serum levels of tumor markers CEA, CA15-3 and LDH showed no abnormalities. \Since graphical examinations gave no evidence of disease, and there are differential diagnosis with ducal carcinoma in FNA, we performed simple mastectomy with VC malignant lymphoma. The histology of the tumors revealed diffuse large B-cell lymphoma of REAL classification. After surgery, chemotherapy eight cycles was performed of the CHOP regiment. (CPA 750 mg/m<sup>2</sup>, d.i.v. day 1; ADM 50 mg/m<sup>2</sup>, d.i.v. day1; VCR 1.4 mg/m<sup>2</sup>, i.v. day-1; and prednisolone 100 mg, p.o. days 1–5). No indicating relapses were detected in nodes of the axillary, inguinal, mediastinum and para-aorta in April 2003. Complete remission was obtained until to date (Nov. 2010), the patient is free of disease.

### Case#2 <sup>11</sup>

A 52-year-old woman presented with a mass in the lateral part of the left breast 2 weeks in March 2006. The patient had no contributory past or family history. No nipple discharge but axillary lymphadenopathy was detected. An ultrasonogram of the left breast revealed malignant lesion, left axilla node positive (Fig. 1). A mammogram showed suspect malignant lesion in UIQ in left breast with lymphnode axilla positive. Results of a FNA of the tumor revealed ductal carcinoma mamma. On admission, blood chemistry results, including serum levels of tumor markers CEA, CA15-3 showed no abnormalities but LDH was abnormal. We was performed MRM. The histology of the tumors revealed diffuse large B-cell lymphoma of REAL classification. Immuno-histochemistry revealed ER, PR, Her-2/Neu negative, CD 20 positive 100 %, CD 30: negative. After surgery, followed by combination of immunotherapy (Rituximab) and chemotherapy (CHOP regiment) eight cycles. On May 2007, she complain pain in left hand, Lesi nervus ulnaris, and on August 2007 CT scan thorax revealed multiple nodules in both lung and showed LDH 361, because patient drop out, on November 2007 passed away with survival rate 20 months only.

### <sup>24</sup> Case#3.

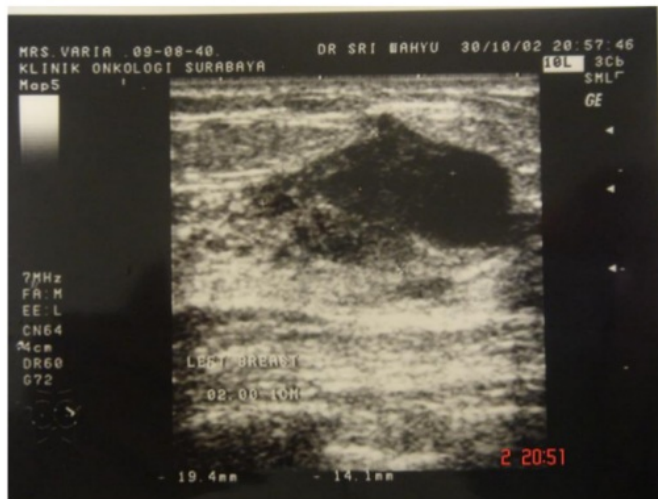A 51-year-old woman presented with a mass in the left breast and node enlargement in supraclavica, submandibula, neck, axilla on April 2005. The patient had no contributory past or family history. Nipple discharge was not detected. An ultrasonogram of the left breast revealed malignant lesion, node in left axilla and right submandibula positive (Fig. 1). On admission, blood chemistry results, including serum levels of tumor markers CEA, CA15-3 showed no abnormalities. Excision biopsy from right submadibula node revealed non Hodgkin's Lymphoma, diffuse large B cell.

Since graphical examinations gave no performed, we performed chemotherapy with eight cycles of CHOP regiment without radiation because she had rejected due to financial problem. No indicating relapses were detected in nodes of the right axilla, inguinal, mediastinum and para-aorta in April 2008. Complete remission was obtained. On May 2009 (DFI around three years), evaluation in the USG revealed left and right breast normal, left and right axillary nodes 10 mm, supraclavícula node negative, submandibular nodes positive, right 26 mm and left 24 mm in diameter (relapse). We decided to give a combination of chemotherapy (other regimen) and radiation, but she had rejected due to financial problem (drop out).

31

#### Case#4

A 51-year-old woman presented with a mass in the multiple nodule in right and left breast, fixed, on May 2008. The patient had no contributory past or family history Nipple discharge was not detected. An ultrasonogram of the breast revealed irregular hypoechoic lesion lesions in both breasts. Lymph edema negative, infiltration in pectoralis muscle negative. Left supraclavícula 5 mm node, normal liver. Left lower back, irregular skin nodule 10 x 7 mm. Mass UIQ RB below the muscle 18 x 6 mm (Fig. 1). Mammography showed a mass of homogeneous density with a regular border, but without microcalcification or speculation (Fig.2). On admission, blood chemistry results, including serum levels of tumor markers CEA, CA15-3 and LDH showed no abnormalities. Core biopsy revealed bilateral breast non Hodgkin's lymphoma subcutaneous, T-cell lymphoma. The Immuno-Histo-Chemistry (IHC) showed CD 3: positive strong membrane staining in 30% of tumor cells, CD 20: negative membrane staining in all tumor cells, CD 30: positive membrane staining on few large cells, and Cytokeratin 7 was positive on normal gland epithel only. We were performed chemotherapy with planning of eight cycles of CHOP regiment and radiation. But, the response of treatment no good (Progression Disease), and the patient passed away on one year later.



27

Figure 1. USG of left breast reveals heterogeneous hypoechoic mass of patient case # 1

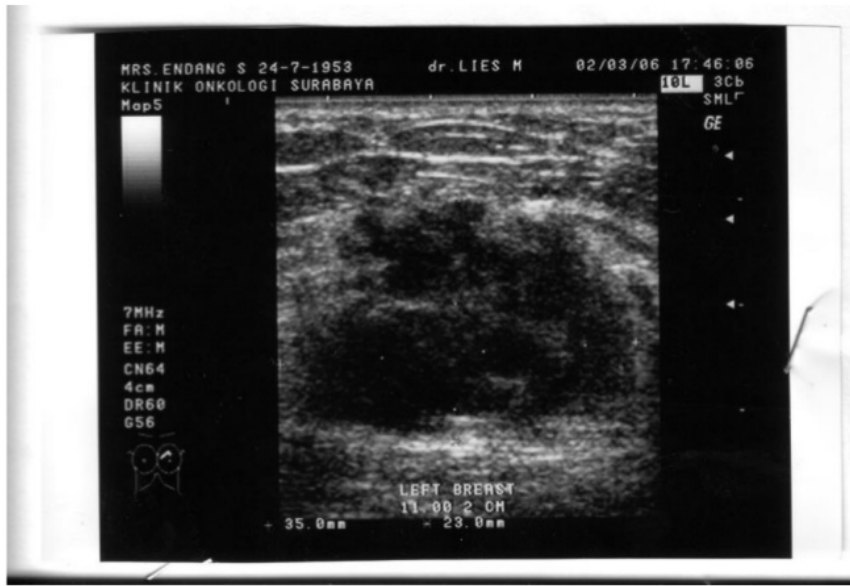

Figure 1. USG of left breast reveals heterogenous hypochoic mass of patient case # 2

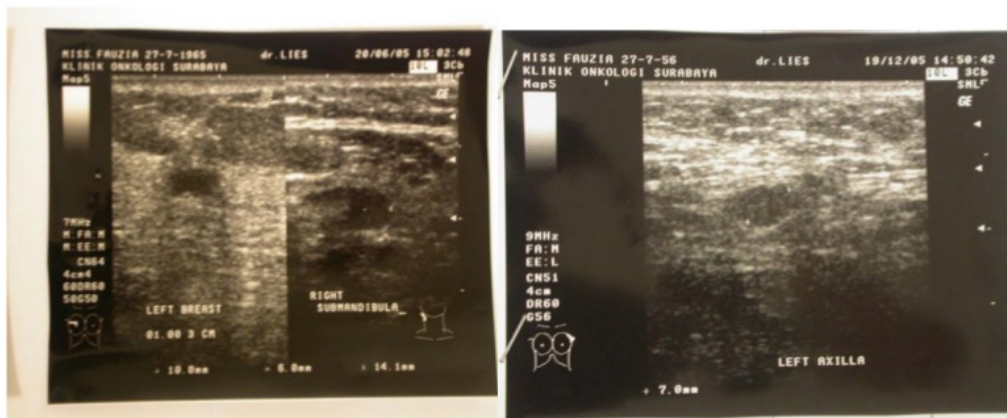
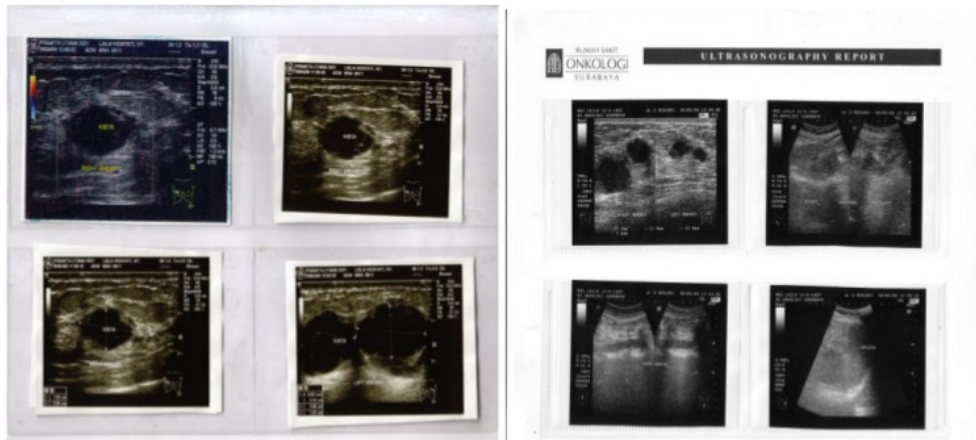
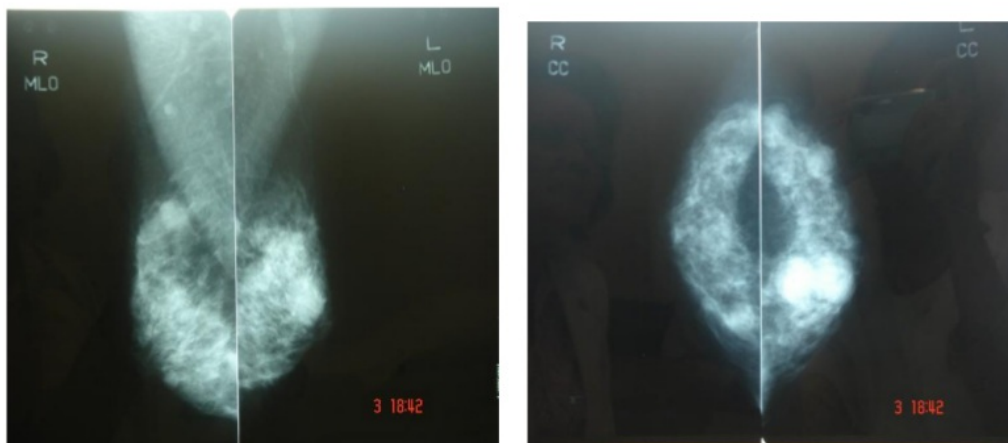


Figure 1. USG of left breast reveals heterogenous hypochoic mass of patient case# 3

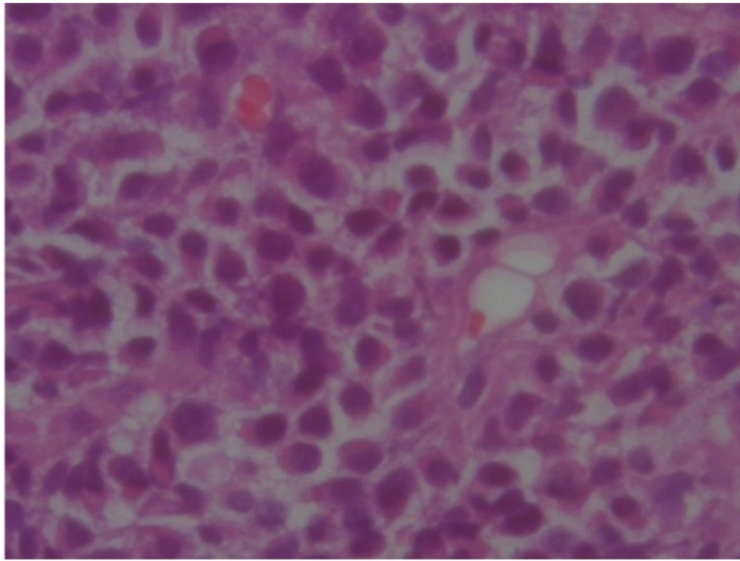




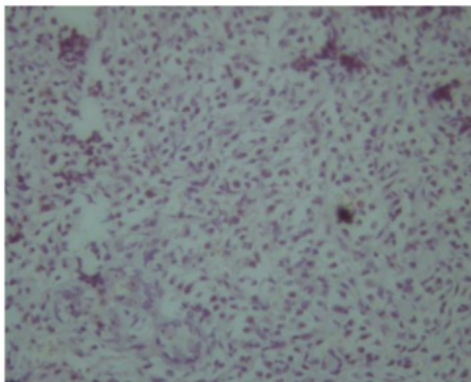
**Figure 1.** An ultrasonogram of the breast revealed irregular hypoechoic lesion lesions in both breasts (patient case # 4)



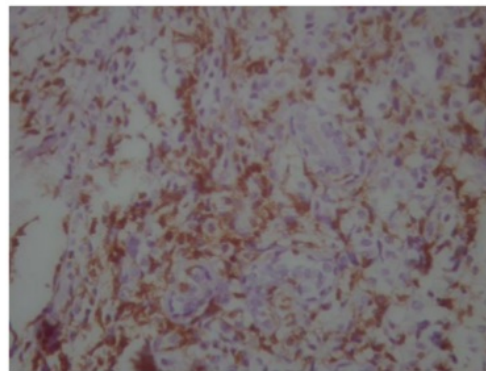
**Figure 2.** Mammography shows a mass of homogeneous density with a regular border, but without microcalcificaton or spiculation.



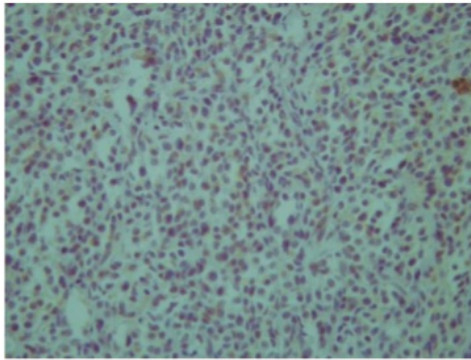
**Figure 3 (from case # 4).** Light microscopy of tissue from resected **breast** shows malignant **lymphoma** of diffuse, large cell type (hematoxylin and eosin stain; original magnification x40).



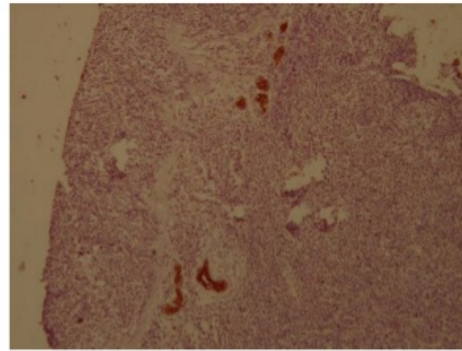
**Figure 3 (case#4).** IHC x10.  
CD 20 negative membrane staining  
In all tumor cells



**Figure 3 (case#4).** The Immuno-Histo-  
Chemistry (IHC x40) showed CD3: positive  
strong membrane staining in 30% of tumor  
cells



**Figure 3 (case#4) IHC x40**  
CD 30: positive membrane staining on few large cells



**Figure 3 (case#4) IHC x 10**  
Cytokeratin 7 was positive on normal gland epithel

### MANAGEMENT

We used simple mastectomy and chemotherapy CHOP for tumors of patient #1, and complete remission was obtained, until to date (eight years) the patient is free of disease. For tumors of patient #2, we performed Modified Radical Mastectomy (MRM), because the result of USG prone like malignancy and FNA ductal carcinoma, followed by rituximab plus CHOP (CD 20 strongly expression), but this patient passed away passed away with survival rate 20 months only. For patient #3, assuming that the histology is diffuse large B cell lymphoma, and the tumors are not only in the breast, CHOP followed by involved field irradiation would seem to be a reasonable choice. But the patient denied radiation, therefore she only received eight cycles CHOP chemotherapy. Complete remission was obtained until April 2008 (DFI around 3 years), after that recurrent and she was denial to treatment (drop out). The last patient (case #4), what should be done in this case? Assuming that the histology is non Hodgkin's lymphoma subcutaneous, T-cell lymphoma, bilateral in the breast and there are skin nodules in the left lower back, we considered it to be of systemic origin, therefore eight cycles of CHOP followed by involved field irradiation would seem to be a reasonable choice. But, the response of treatment no good (Progression Disease), and the patient passed away on one year later.

### DISCUSSION

Malignant Lymphoma (ML) is a neoplasm originating from lymph tissue, and extranodal ML can occurs in the intestinal tract and or Waldeyer's ring. Primary non-Hodgkin's lymphoma of the breast is a rare disease, representing only 0.12–0.53% of all reported malignant breast tumors<sup>(2)</sup>. It is important to determine whether ML of the breast is originated in the breast or systemic. From 2002 to 2008, we treated four patients only, three of them with unilateral tumors only in the breast, and other with tumors in both breasts.<sup>21</sup>

Wiseman and Liao<sup>(3)</sup> reported that a diagnosis of primary malignant lymphoma of the breast must satisfy several criteria: (a) adequate pathological evaluation; (b) both



mammary tissue and lymphomatous infiltrate must be in close association; and (c) the exclusion of either systemic lymphoma or previous extra-mammary lymphoma (the presence of ipsilateral axillary node involvement was considered acceptable).

On radiographic examination, there are no characteristic findings in ML of the breast. A mammogram often shows a homogeneous faint tumor shadow without either microcalcification or spiculation. An ultrasonogram reveals a coarse internal echo, a hypoechoic mass with an irregular border and occasionally a lobulated mass representing a huge tumor<sup>(4)</sup>. At any rate, it is difficult to distinguish ML from breast cancer during its early stages. Because neither an excisional biopsy with frozen sections nor an FNAC is helpful in differentiation, ML is often misdiagnosed as breast cancer<sup>(5)</sup>.

In the first case, the ultrasonogram (USG) revealed hypoechoic lesion in the left breast. And, the result of FNA of the tumor revealed high grade large B cell malignant lymphoma, but still differential diagnosis with Ductal Carcinoma Mamma. The second case, the USG revealed malignant lesion, left axilla node positive and the result of FNA was Ductal Carcinoma. The third case, USG of the left breast revealed malignant lesion, left axilla node positive, and excision biopsy revealed non Hodgkin's Lymphoma, diffuse large cell. The fourth case, USG revealed irregular hypoechoic lesions in both breasts and left supraclavicular node 5 mm. Core biopsy revealed bilateral breast non-Hodgkin's lymphoma malignant subcutaneous, T-cell lymphoma. In Immunohistochemistry showed CD 3: positive strong membrane staining in 30 % of tumor cells, CD 20: negative membrane staining in all tumor cells, CD 30: positive membrane staining on few large cells, and Cytokeratin 7 was positive on normal gland epithel only.

Therapeutic management of ML in the breast is controversial and is not fully established as yet. Surgery, strikingly, mastectomy was associated with a poorer survival in the univariate analysis, compared with conservative procedures or biopsy. A higher risk of failures with radical surgery was also noted in Fruchart et al's report. Although the adverse effect of mastectomy can be influenced by other confounding factors, radical surgery is at best unnecessary and should be avoided in ML of the breast. Ideally surgery should be limited to a biopsy to establish the correct histological diagnosis, leaving the treatment with curative intent to radiotherapy and chemotherapy<sup>(11)</sup>.

DeCosse et al<sup>(6)</sup> reported that localized tumors within the breast had a good prognosis by surgical intervention alone. However, relapses were reported 10 years after surgery<sup>(7)</sup> without adjuvant therapy. On the other hand, if the ML is determined to be of systemic origin, surgery plus chemotherapy is effective<sup>(4, 8)</sup>. In addition, an opinion exists that irradiation alone is effective<sup>(9)</sup>.

Primary lymphoma of the breast is rather uncommon, but several reports suggest that the clinical outcome and management is dependent upon histology and seems to parallel that of patients with nodal presentations of lymphoma. The majority of patients with localized presentations had intermediate-grade lymphoma, and most with disseminated disease had low-grade lymphoma. Unfortunately, the type of lymphoma was not specified in this case, which is critical to determining the natural history of the disease. For patients with limited-stage low-grade lymphoma (e.g. follicular lymphoma), an irradiation alone is potentially curative. For patients with limited-stage intermediate-grade lymphoma (e.g. diffuse large B cell lymphoma), a short course of chemotherapy plus involved field irradiation may be the treatment of choice.

Two trials have evaluated the role of involved field irradiation plus chemotherapy in patients with localized disease, although in both studies, patients generally had localized nodal rather than extranodal disease. A Southwest Oncology Group (SWOG) trial demonstrated that 3 cycles of cyclophosphamide, doxorubicin, vincristine, and prednisolone (CHOP) plus radiotherapy (RT) was more effective than 8 cycles of CHOP in patients with non-bulky stage I or II disease<sup>(3)</sup>. However, a follow-up analysis of that study with 8.2 years median follow-up indicated that the relapse-free survival curves had converged. Five-year estimates for CHOP-RT (40 Gy) versus CHOP were essentially unchanged from the original report, with an overall survival (OS) of 82% versus 74% and a failure-free survival (FFS) of 76% versus 67%, respectively. Of note, Kaplan-Meier estimates showed overlapping curves at 7 years for FFS and at 9 years for OS, presumably due to late relapses and deaths from lymphoma occurring between years 5 and 10. In addition, a continuous rate of death was seen over the first 10 years, with no evidence of plateau in the survival curve.

Another trial, this one conducted by the Eastern Cooperative Oncology Group (ECOG), also compared CHOP-RT versus CHOP, although the population was substantially different. The ECOG trial demonstrated that CHOP for 6-8 cycles plus RT (30 Gy for CRs; 40 Gy for PRs) was more effective than CHOP alone in patients with bulky stage II disease who achieved complete response to therapy.<sup>(4)</sup>

A follow-up report resulted in similar findings in a SWOG trial<sup>(11)</sup>. The study included 352 eligible patients with untreated bulky or extranodal stage I or stage II diffuse aggressive lymphoma. After 8 cycles of CHOP, the CR rate was 61% and the PR rate was 28%. Of those who demonstrated PR after CHOP, 28% showed CR after 40 Gy RT. Disease-free-survival, time to progression, and OS were significantly greater in the CHOP-RT arm, but OS was similar between the groups.

For patients with advanced-stage intermediate-grade B-cell lymphoma, an interim analysis of a phase 3 trial performed by the Groupe d'Etude des Lymphomes de L'Adulte (GELA trial LNH 98-5) recently indicated a significantly improved CR rate (76% versus 63%), event-free survival (69% versus 49%), and 1-year survival (83% versus 68%) in 328 elderly patients (60-80 years of age) treated with rituximab plus CHOP compared with CHOP alone.<sup>(1, 6)</sup> It is unclear whether the addition of rituximab confers a similar advantage in patients with early-stage disease. Treatment of recurrent or relapsed ML by second- and third-generation chemotherapy has a poor prognosis.

Recently, Katsuki et al. reviewed 104 patients concerning therapy for ML of the breast<sup>(1,5)</sup>; 38 patients (36.5%) were treated by surgery and chemotherapy, 38 (36.5%) by surgery, chemotherapy and irradiation and 20 (19.2%) by surgery and irradiation. Abbondanzo et al. reviewed 31 patients in the recent literature<sup>(10)</sup>; 22 patients (70.9%) were treated by surgery and chemotherapy, four (12.9%) by surgery and irradiation, two (6.4%) by surgery, chemotherapy and irradiation and two (6.4%) by surgery alone.

In this case reports, we used simple mastectomy and chemotherapy CHOP for tumors of case #1, and complete remission was obtained, the patient is free of disease until to date (eight years). For tumors of case #2, MRM was performed, because the result of USG prone like malignancy and FNA ductal carcinoma. After surgery, was followed by combination of Rituximab (CD 20 strongly expression) and chemotherapy (CHOP regiment) eight cycles. On May 2007, she complained pain in left hand, Lesi nervus ulnaris, and on June 2007 CT scan thorax revealed small nodule in lung and

showed LDH 361. On November 2007 passed away without treatment after relapses (denial). DFI around one year and survival rate around 20 months. <sup>14</sup>

For tumors of patient #3, assuming that the histology is diffuse large B cell lymphoma, and the tumors are not only in the breast, 3 cycles of CHOP followed by involved field irradiation would seem to be a reasonable choice. But the patient denied radiation, therefore she received eight cycles CHOP chemotherapy. Complete remission was obtained until April 2008 (DFI 3 years), after that recurrent and she was denial treatment (DO=drop out).

The last patient (case #4), what should be done in this case? Assuming that the histology was non Hodgkin's lymphoma subcutaneous, T- cell lymphoma, bilateral in the breast and there were skin nodules in the left lower back. We considered it to be of systemic origin (8 cycles of CHOP), if followed by involved field irradiation would seem to be a reasonable choice.

## CONCLUSION <sup>15</sup>

We report four cases of malignant lymphoma (ML) of the breast and discuss diagnosis and management. Although there are no data, breast lymphoma has a poor prognosis and the therapeutic management of breast lymphoma is controversial and is not fully established as yet. Ideally, surgery should be limited to a biopsy to establish the correct histological diagnosis, leaving the treatment with curative intent to radiotherapy and chemotherapy.

On the other hand, a relatively high relapse rate was reported in stage I disease of primary lymphomas in the breast despite the use of chemotherapy. In addition, in patients with intermediate- or high-grade lymphoma, combined modality has been shown to yield a higher survival rate than radiation therapy alone, and a strategy consisting of three cycles of CHOP followed by involved-field radiation therapy is reportedly superior to eight cycles of CHOP alone.

## SUGGESTION

Although the follow-up periods for our patients are still not so long, they have been alive and disease-free for 72 and 36 months. We suggest that the combination of local irradiation and short-course chemotherapy, as a choice but in this study, chemotherapy alone still gave a choice in the treatment of Primary Breast Lymphoma.

## REFERENCES

**1.Suzuki Y, Ito J, Hasegawa M, et al (2002).** Primary Breast Lymphoma Successfully Treated with Combination Therapy Including Local Radiation Therapy: A Report of Two Cases. *Radiation Medicine*: Vol. 20 No. 1, pp 37-39..

**2.Miller TP, Dahlberg S, Cassady JR, et al (1998).** Chemotherapy alone compared with chemotherapy plus radiotherapy for localized intermediate- and high-grade non-Hodgkin's lymphoma. *N Engl J Med*, 339: 21–26.

- 3.Lyons JA, Myles J, Pohlman B, Macklis RM, Crowe J, Crownover RL (2000).** Treatment and prognosis of primary breast lymphoma. *Am J Clin Oncol*, 23: 334–336.
- 4.Fruchart C, Denoux Y, Chasle J, Peny AM, Boute V, Ollivier JM, Genot JY, Michels JJ (2005):** High-grade primary breast lymphoma: is it a different clinical entity? *Breast Cancer Res Treat*, **93**:191-198.
- 5.Ganjoo K, Advani R, Mariappan MR, McMillan A, Horning S (2007):** Non-Hodgkin's lymphoma of the breast. *Cancer*, 110:25-30. [PubMed Abstract](#) | [Publisher Full Text](#)
- 6.Domchek SM, Hecht JL, Fleming MD, Pinkus GS, Canellos GP (2002):** Lymphomas of the breast: primary and secondary involvement. *Cancer*, **94**:6-13. [PubMed Abstract](#) | [Publisher Full Text](#)
- 7.Kuper-Hommel MJJ, Snijder S, Jansen-Heijnen ML, Vrints LW, et al (2003).** Treatment and survival of 38 female breast lymphomas: a population-based study with clinical and pathological reviews. *Ann Hematol*, **82**:397-404. [PubMed Abstract](#) | [Publisher Full Text](#)
- 8.Jeanneret-Sozzi W, Taghian A, Epelbaum R, Poortmans P, et al (2008).** Primary breast lymphoma: Patient profile, outcome and prognostic factors. A multicentre Rare Cancer Network study. *BMC Cancer*, **8**:86
- 9.Wong WW, Schild SE, Halyard MY, Schomberg PJ (2002).** Primary non-Hodgkin lymphoma of the breast: the Mayo Clinic experience. *J Surg Oncol.*; 80:19-25. [Abstract](#)
- 10.Domchek SM, Hecht JL, Fleming MD, Pinkus GS, Canellos GP (2002).** Lymphomas of the breast. *Cancer. J Surg Oncol.*; 94:6-13. [Abstract](#)
- 11.Sparano JA, MD (2003).** Treating Non-Hodgkin's Lymphoma of the Breast?. *Medscape Hematology-Oncology* 6(1), 2003.



# Case report of Malignant Lymphoma of The Breas

## ORIGINALITY REPORT

24%

SIMILARITY INDEX

14%

INTERNET SOURCES

22%

PUBLICATIONS

0%

STUDENT PAPERS

## PRIMARY SOURCES

1

Randal Baker. "Multifocal Primary Breast Lymphoma", Southern Medical Journal, 10/2005

Publication

1%

2

[www.theonc.org](http://www.theonc.org)

Internet Source

1%

3

Eiji Hinoshita, Hideya Tashiro, Ikuo Takahashi, Toshihiro Onohara et al. "Primary non-hodgkin's lymphoma of the breast: a report of two cases", Breast Cancer, 1998

Publication

1%

4

R I Fisher, P Shah. "Current trends in large cell lymphoma", Leukemia, 2003

Publication

1%

5

[www.encyclopedia.com](http://www.encyclopedia.com)

Internet Source

1%

6

Neoplastic Diseases of the Blood, 2013.

Publication

1%

7

Eiji Hinoshita. "Primary non-hodgkin's lymphoma of the breast: a report of two cases",

1%

# Breast Cancer, 07/1998

Publication

---

8	<b>Oncology, 2006.</b> Publication	1%
9	<b>Management of Rare Adult Tumours, 2010.</b> Publication	1%
10	<b>tessera.spandidos-publications.com</b> Internet Source	1%
11	<b>"Essentials of Diagnostic Breast Pathology", Springer Science and Business Media LLC, 2007</b> Publication	1%
12	<b>www.mysciencework.com</b> Internet Source	1%
13	<b>content.nejm.org</b> Internet Source	1%
14	<b>Ferry, Judith A.. "Diagnosis of Lymphoma in Extranodal Sites Other Than Skin", Hematopathology, 2011.</b> Publication	1%
15	<b>www.omicsonline.org</b> Internet Source	1%
16	<b>www.senology.org</b> Internet Source	1%

---

**"International Surgical Week ISW 2011", World**

17

[Journal of Surgery, 2011](#)

Publication

1%

18

Yeon Hee Park, Se-Hoon Lee, Won Seog Kim, Soo-Mee Bang et al. "CHOP followed by involved field radiotherapy for localized primary gastric diffuse large B-cell lymphoma: Results of a multi center phase II study and quality of life evaluation", *Leukemia & Lymphoma*, 2009

Publication

1%

19

[indonesianjournalofcancer.org](http://indonesianjournalofcancer.org)

Internet Source

1%

20

[www.cancerbio.net](http://www.cancerbio.net)

Internet Source

&lt;1%

21

Shahrzad Negahban, Nasrollah Ahmadi, Ahmad Oryan, Habib N. Khojasteh et al. "Primary Bilateral Burkitt Lymphoma of the Lactating Breast", *Molecular Diagnosis & Therapy*, 2012

Publication

&lt;1%

22

Thirukonda, Venu K., and Adam M. Petrich. "Treatment of Diffuse Large B-cell Lymphoma :", *Pathology Case Reviews*, 2012.

Publication

&lt;1%

23

[www.ncbi.nlm.nih.gov](http://www.ncbi.nlm.nih.gov)

Internet Source

&lt;1%

24

Ronald F. Pinheiro, Gisele W.B. Colleoni, Otavio C.G. Baiocchi, Fábio R. Kerbauy, Luiz Cláudio

&lt;1%

C. Duarte, José O. Bordin. "Primary Breast Lymphoma: An Uncommon but Curable Disease", *Leukemia & Lymphoma*, 2009

Publication

25

[doaj.org](http://doaj.org)

Internet Source

<1%

26

[oncolink.com](http://oncolink.com)

Internet Source

<1%

27

RICHARD H. MEADE, RICHARD A. RASMUSSEN. "The Clinical Problem of Infected Cystic Disease of the Lung", *Diseases of the Chest*, 1953

Publication

<1%

28

Susan M. Domchek, Jonathan L. Hecht, Mark D. Fleming, Geraldine S. Pinkus, George P. Canellos. "Lymphomas of the breast", *Cancer*, 2002

Publication

<1%

29

[www.perlp.com](http://www.perlp.com)

Internet Source

<1%

30

Alessandro Neri. "Primary non-Hodgkin's breast lymphoma: Surgical approach", *Cases Journal*, 2008

Publication

<1%

31

VURAL, Filiz, SAYDAM, Güray, ŞAHİN, Fahri, SOYER, A. Nur, HEKİMGİL, Mine, OCAKCI,

<1%



Serkan, TOMBULOĞLU, Murat and ÇAĞIRGAN, Seçkin. "Non-Hodgkin s lymphoma of the breast: report of five cases and review of the literature", Akademi Doktorlar Yayınevi, 2012.

Publication

32

Ganti, Apar, and James Armitage. "Systemic therapy of lymphoma", The Lymphoid Neoplasms 3ed, 2010.

Publication

<1%

33

Satoshi Ishikura. "Japanese multicenter phase II study of CHOP followed by radiotherapy in stage I-II1, diffuse large B-cell lymphoma of the stomach", Cancer Science, 6/2005

Publication

<1%

34

[aap.onlinelibrary.wiley.com](http://aap.onlinelibrary.wiley.com)

Internet Source

<1%

35

[link.springer.com](http://link.springer.com)

Internet Source

<1%

36

"Radiation Therapy in Hematologic Malignancies", Springer Science and Business Media LLC, 2017

Publication

<1%

37

[www.jstage.jst.go.jp](http://www.jstage.jst.go.jp)

Internet Source

<1%

38

"A Comprehensive Guide to Core Needle

Biopsies of the Breast", Springer Science and Business Media LLC, 2016

Publication

<1%

39

Tatsuhiko Ikeda, Hiroko Bando, Akiko Iguchi, Yuko Tanaka, Eriko Tohno, Hisato Hara. "Malignant lymphoma of the breast in a male patient: ultrasound imaging features", Breast Cancer, 2012

Publication

<1%

40

Breast Disease, 2016.

Publication

<1%

41

Tomoko Ogawa. "A case of burkitt's lymphoma involving both breasts", Breast Cancer, 07/2005

Publication

<1%

Exclude quotes On

Exclude matches Off

Exclude bibliography On

# Case report of Malignant Lymphoma of The Breas

---

## GRADEMARK REPORT

---

FINAL GRADE

**/100**

GENERAL COMMENTS

**Instructor**

---

PAGE 1

---

PAGE 2

---

PAGE 3

---

PAGE 4

---

PAGE 5

---

PAGE 6

---

PAGE 7

---

PAGE 8

---

PAGE 9

---

PAGE 10

---

PAGE 11

---