

A Rare widespread tuberculous spondylitis extended from the T5-T10 levels-a case report

by Viskasari Pintoko Kalanjati

Submission date: 22-Jan-2020 04:30PM (UTC+0800)

Submission ID: 1244849845

File name: us_spondylitis_extended_from_the_T5-T10_levels-a_case_report.pdf (198.1K)

Word count: 2467

Character count: 14017

PAPER • OPEN ACCESS

⁴
A rare widespread tuberculous spondylitis extended from the T5-T10 levels – a case report

²
To cite this article: L G Evayanti *et al* 2018 *IOP Conf. Ser.: Mater. Sci. Eng.* **434** 012323

View the [article online](#) for updates and enhancements.

4 A rare widespread tuberculous spondylitis extended from the T5-T10 levels – a case report

L G Evayanti^{1,4*}, V P Kalanjati² and A Machin³

¹ Master Study Program of Basic Medical Science, Faculty of Medicine, Universitas Airlangga, Surabaya, Indonesia

² Department of Anatomy and Histology, Faculty of Medicine, Universitas Airlangga, Surabaya, Indonesia

³ Department of Neurology, Faculty of Medicine, Universitas Airlangga, Surabaya, Indonesia.

⁴ Department of Anatomy and Histology, Faculty of Medicine and Health Science, Universitas Warmadewa, Bali, Indonesia

*eva4chiraime@gmail.com

Abstract. Tuberculous spondylitis is an infection of *Mycobacterium tuberculosis* in the spine and might compromise the vertebrae. Patients often come to treatment at an advanced stage; whilst early diagnosis might be quite tricky. Twenty two years old male patient experienced a weakness, tingling and thickness in both lower limbs that worsened since 1 week before the admission. The imaging results of the multi-slice computed tomography (MSCT) with contrast and X-ray was obtained by impression of pulmonary tuberculosis and lead to the diagnosis of tuberculous spondylitis. Infection developed into a paravertebral abscess in the form of back swelling that is clearly observed at the radiological features with T5-T10 levels of lesion. In this case, neuropathology may be caused by compression of the spinal cord by the abscess; worsened by an ongoing infection and inflammation. Motor deficits might be due to the extended lesion in the anterior horn of the spinal cord; whilst the sensory deficits due to the posterior horn lesion. After medication with anti-tuberculosis and stabilization of the back, patient achieved significant improvement. This underlining the importance of basic anatomy knowledge and its clinical correlation for optimizing patient's diagnosis and treatment.

8 1. Introduction

Tuberculosis (TB) is an infectious disease caused by *Mycobacterium tuberculosis* bacteria [1]. This infection can affect the lungs (pulmonary TB) and various other organ systems (extrapulmonary TB). Tuberculous spondylitis (TS) is one of the extrapulmonary TB that infects the spine. Tuberculous spondylitis was first described by Sir Percivall Pott (1714-1788), thus known as Pott's disease of spine [2]. The World Health Organization report in 2013 estimates that there were 8.6 million cases of TB in 2012 and of which 1.1 million people (13%) were patients with a positive human immunodeficiency virus (HIV). Tuberculosis prevalence rate of positive pulmonary TB smear in Indonesia in 2013 was 257 per 100,000 population aged 15 years and over [1]. In 2016, incidence of TB reached 391 per 100,000 population [3]. Twenty percent of pulmonary TB patients will spread to extrapulmonary TB

[4-6]. ³Eleven percent of extrapulmonary TB is osteoarticular TB, in which half of osteoarticular TB cases are TS [7].

Neurologic deficits of paraplegia and permanent spine deformity are the most common clinical manifestations of advanced stage TS. However, early diagnosis of TS might be quite tricky and often suspected as neoplasms or other pyogenic spondylitis [7]. This underlines the importance of basic anatomy knowledge and its clinical correlation for optimizing patient's diagnosis and treatment. This case report aims to report TS case occurring in a 22-year-old male patient treated in a neurological ward of Dr. Soetomo Academic Medical Center Hospital (RSUD Dr. Soetomo) Surabaya on September 12, 2017.

2. Case Report

A 22-year-old male from Sumberejo, came to the neurology clinic of RSUD Dr. Soetomo, Surabaya with a chief complaint of weakness of both lower limbs on September 12, 2017. The weakness of both lower limbs occurred gradually since 3 months and worsened since 1 week before admission to the hospital. Tingling and thickness in both lower limbs occurred since 4 months before admission. The patient also complained of a lump on the upper back region and felt pain. The patient has difficulty urinating since 2 weeks before admission. Symptoms such as chronic cough, hemoptysis, weight loss, dyspnea, fever, difficulty defecating, and lumps on other body parts are denied by the patient. The patient and his families denied history of TB.

Vital signs of the patient were normal range. On the physical examination of the thoracolumbar region, the lumps palpated firmly and cold at the T5-T6 level, and the knock pain at the T4 level. The patellar reflex increased on the both sides. Inferior paraplegia of both lower limbs, right side hypoesthesia at T8 level and left side at T10 level, decreased lower limbs proprioceptive abilities, bilateral anhidrosis at T8 level, and urinary retention were found on neurological examination.

Based on the laboratory examination on September 19, 2017, C-reactive protein 16.5 mg/L (normal range: 0-10 mg/L). Examination of complete blood count, kidney function, liver function, and blood glucose within normal limits. The imaging results of X-ray and Multi-Slice Computed Tomography (MSCT) shown on below (figure 1-3).

Based on these clinical findings, the treatment for the patient includes administration of 1x400 mg isoniazid, 1x600 mg rifampicin, 1x1250 mg pyrazinamide, 1x1000 mg streptomycin and 2x500 mg mecobalamin. The patient is planned for debridement and laminectomy surgery with posterior stabilization. After the surgery and medical treatment, the motor and sensory deficits were decreased; patient is under a comprehensive rehab to recover the full-gait-and standing position and to be able to fully walk independently.

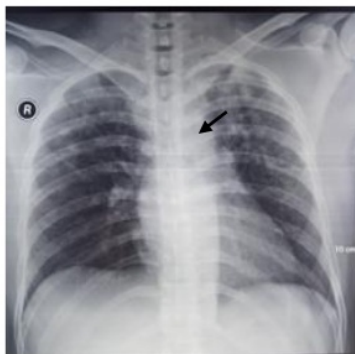


Figure 1. The AP chest X-ray shown that lung inflammation caused by specific process (TB process) and paravertebral soft tissue mass at the left side T5-T10 levels.

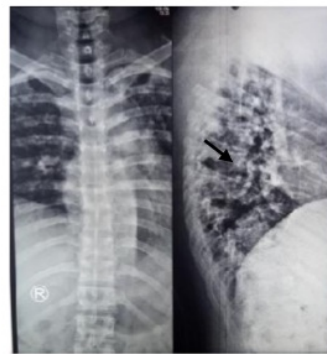


Figure 2. The AP/lateral thoracolumbar X-ray shown that paravertebral soft tissue mass at the left side T5-T10 levels.

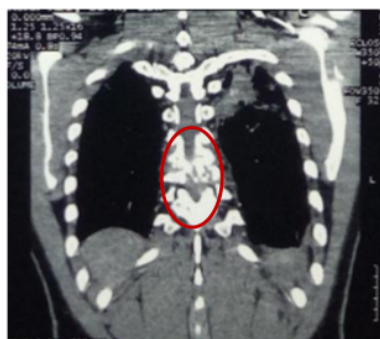

Figure 3. Chest MSCT examination with contrast obtained an image of pulmonary TB, and TS at T7-T8 vertebral levels.

3. Discussion

The vast extent of infection in this case is unusually found. Research at Cipto Mangunkusumo Hospital reported thoracic vertebrae lesions reached 71% of TS cases, followed by lumbar vertebrae, and cervical vertebrae. Five to seven percent of patients have lesions in 2-4 vertebral bodies with an average of 2.5 [8]. In adults, TS occurs mostly in the lower thoracic vertebrae and upper lumbar vertebrae, particularly T12 and L1 [7]. Expansion of Mycobacterium tuberculosis infection in this case showing early diagnosis might be quite tricky. The diagnosis was confirmed with proper radiology and laboratory tests. The wide spread TS was primarily resulted from the pulmonary TB of both lungs (asymptomatic, observed in the radiology images). Increased levels of C-reactive protein (CRP) are associated strongly with abscess formation [8]. In this case, it is known that CRP increased.

Generally the droplet containing Mycobacterium tuberculosis enters through the airways and raises the focus of infection on the lung tissue called primary focus or focus of Ghon. Furthermore, the bacteria spread through lymphatic system and cause local lymphangitis and regional lymphadenitis. Primary focus, localized lymphangitis, and regional lymphadenitis are then referred to as primary complex [5]. Tuberculous spondylitis results from the spread through the para-aortic lymph nodes from the previously established focus of tuberculosis beyond the spine. In adults the source of infection comes from the extrapulmonary focus such as from the intestine, kidney, tonsils. Bacteria spread from the lungs to the spine through the great radicular artery (artery of Adamkiewicz) and the Batson venous plexus [2,9]. The Batson venous plexus is a network of valveless veins that connect the deep pelvic veins and thoracic veins to the internal vertebral venous plexus [9,10]. The great radicular artery originates from the ascending cervical artery, the intercostal artery, and the lumbar artery at the altitudes of T8 and L3 [10].

Tuberculosis lesions in the spine begin with paradiscal inflammation. Bone has infection, hyperemia, spinal bone edema, and osteoporosis. Bone destruction due to lysis of bone tissue causes bone to become soft. Bone destruction is also exacerbated by secondary ischemia due to thromboembolism, periarteritis, and endarteritis [9]. Force of gravity and the pull of the thoracolumbar muscle also causes the bone to become flat. The gravitational load transmission in the anterior portion of the thoracic vertebral corpus that causing compression lesions and flossing are more common than the posterior portion. Then, there is a kyphotic deformity which is often referred to as gibbus [7,9]. When gibbus has been discovered, the pathogenesis of TS has been running for approximately 3-4 months [11]. The severity of kyphosis depends on the number of vertebrae and the spine segments involved. Thoracic vertebrae is more commonly encountered kyphotic deformity [2,7].

Based on anamnesis and physical examination on the thoracolumbar region in this case, there were reported that lumps palpated firm and cold at the T5-T6 level, and knock pain at T4 level. Tuberculous spondylitis can spread to form a palpable paravertebral abscess, even visible from the outside of the back in the form of swelling. The skin surface should also be carefully examined to look for sinus or

fistula estuaries up to the gluteal and below inguinal regions (femoral triangle). It is possible that the abscess is formed anterior to the chest or abdominal cavity [12]. Clinical manifestations of TS are relatively indolent (without pain). Patients usually complain of non-specific local pain in the area of the infected vertebra [9].

Neurologic deficits in TS patients usually occur if the TB lesion is in the thoracic vertebrae. Neurologic deficits and kyphotic deformities are less common when lesions occur in the lumbar vertebra [7,13]. This is because of the great radicular artery, the main artery that supplies the blood to the spinal cord of the thoracolumbar segment [10]. This arterial obliteration due to thrombosis will cause nerve and paraplegia damage. In addition, the relative diameter differs between the spinal cord and its vertebral foramen. Lumbar intolerance begins to widen approximately at the T10 vertebral level, whereas the vertebral foramen in the area is relatively small. In the lumbar vertebra, the vertebral foramen is larger and gives more room for compression of the anterior portion [13].

On neurological examination might be found motor, sensory, and autonomic dysfunction. The neurologic deficits found in this case were inferior paraplegia of both lower limbs, the patellar reflex increased on the both sides. Neurologic deficits occur in 12-50% of patients [8]. Possible neurologic deficits include: paraplegia, paresis, hypoesthesia, radicular pain and/or cauda equina syndrome. Radicular pain indicates a disturbance in the spinal radicle (radiculopathy) [9]. Local pain and radicular pain with motor disturbance, sensory, and distal sphincter due to vertebral lesions will worsen if the disease is not treated immediately [7]. The incidence of paraplegia in TS (Pott's paraplegia), as the most dangerous complication, occurs only in 4-38% of patients [7]. Pott's paraplegia is divided into two types: early-onset paraplegia and late-onset paraplegia [9]. Rapid-onset paraplegia occurs when acute, usually within the first two years. It is caused by compression of the spinal cord by abscess or infection process. While slow-onset paraplegia occurs when the disease is no signs of spondylitis reactivation and generally caused by fibrous tissue pressure or bone protrusions due to previous bone destruction [9,11]. The motor symptoms usually appear first because neuropathology occurs from the ventral side of the spinal horn and/or column that correlated to corticospinal tracts. The sensory deficits were highly correlated to the deficits of the dorsal column tract and the spinothalamic tract. The autonomic function could be compromised due to the pathology of the lateral horn of the spinal cord at the thoracolumbar levels that resided by the intermediolateral neurons of the sympathetic nerves system [10]. The sensory and autonomic deficits found in this case are right side hypoesthesia at the T8 and left side at the T10, decreased lower limbs proprioceptive abilities, bilateral anhidrosis at T8 level, and urinary retention.

4. Conclusion

Good understanding of the anatomy would help the clinicians to diagnose the pathology correctly, thus proper treatment could be done.

Acknowledgement

The authors would like thank to lecturers of Universitas Airlangga and RSUD dr. Soetomo, Surabaya for the support and contribution.

References

- [1] Kementerian Kesehatan Republik Indonesia 2016 Tuberkulosis temukan obati sampai sembuh. *Infodatin* Available from: <http://www.depkes.go.id/download.php?file=download/pusdatin/infodatin/InfoDatin-2016-TB.pdf> [Accessed: November 12, 2017]
- [2] Dass B, Puet T A and Watanakunakorn C 2002 Tuberculosis of the spine (Pott's disease) presenting as 'compression fractures' *Spinal Cord*. **40** 604-608
- [3] World Health Organization 2017 Global Tuberculosis Report Available from: http://www.who.int/tb/publications/global_report/en/ [Accessed: November 15, 2017]
- [4] Agarwal P, Rathi P, Verma R and Pradhan C G 1999 Tuberculous spondylitis: 'global lesion'. special issues on tuberculosis *Bombay Hospital J.*

- [5] Perhimpunan Dokter Paru Indonesia 2006 Tuberkulosis: pedoman diagnosis dan Penatalaksanaan di Indonesia (Jakarta: Grafika) p 5
- [6] Vitriana 2002 Spondilitis tuberkulosa Available from: http://pustaka.unpad.ac.id/wp-content/uploads/2009/05/spondilitis_tuberkulosa.pdf [Accessed: November 12, 2017]
- [7] Zuwanda and Janitra R 2013 Diagnosis dan penatalaksanaan spondilitis tuberkulosis *Cermin Dunia Kedokteran* **40**(9) 661-673
- [8] Albar Z 2002 Medical treatment of spinal tuberculosis *Cermin Dunia Kedokteran* **137** 29
- [9] Agrawal V, Patgaonkar P R and Nagariya SP 2010 Tuberculosis of spine *J. Craniovertebr. Junction Spine* **1**(2) 74-85
- [10] Crossman A R and Neary D 2015 *Neuroanatomy: an illustrated colour text* 5th ed (New York: Churchill Livingstone Elsevier)
- [11] Jain A K, Dhammi I K, Jain S and Mishra P 2010 Kyphosis in spinal tuberculosis: prevention and correction *Indian J. Orthop.* **44**(2) 127-136
- [12] Papavramidis T S, Papadopoulos V N, Michalopoulos A, Paramythiotis D, Potsi S, and Raptou G 2007 Anterior chest wall tuberculous abscess: a case report. *J. Med. Case Reports* **1** 152
- [13] Karraeminogullari O, Aydinli U, Ozerdemoglu R and Ozturk C 2007 Tuberculosis of the lumbar spine: outcomes after combined treatment of two-drug therapy and surgery. *Orthopedics.* **30**(1) 55-59

A Rare widespread tuberculous spondylitis extended from the T5-T10 levels-a case report

ORIGINALITY REPORT

14%

SIMILARITY INDEX

11%

INTERNET SOURCES

10%

PUBLICATIONS

1%

STUDENT PAPERS

PRIMARY SOURCES

- 1** aisberg.unibg.it Internet Source 3%
- 2** V Yudha, H S B Rochardjo, J Jamasri, R Widyorini, F Yudhanto, S Darmanto. "Isolation of cellulose from salacca midrib fibers by chemical treatments", IOP Conference Series: Materials Science and Engineering, 2018 Publication 2%
- 3** R Dharmajaya. "Tuberculous spondylitis in Haji Adam Malik hospital, Medan", IOP Conference Series: Earth and Environmental Science, 2018 Publication 1%
- 4** www.nature.com Internet Source 1%
- 5** www.thieme-connect.de Internet Source 1%
- 6** Badarudin Hakim, Basari. "Tuberculosis detection analysis using texture features on CXRs images", AIP Publishing, 2019 1%

7	docobook.com Internet Source	1%
8	link.springer.com Internet Source	1%
9	www.mdpi.com Internet Source	<1%
10	www.tandfonline.com Internet Source	<1%
11	www.highbeam.com Internet Source	<1%
12	tessera.spandidos-publications.com Internet Source	<1%
13	www.karger.com Internet Source	<1%
14	es.scribd.com Internet Source	<1%

Exclude quotes On

Exclude matches Off

Exclude bibliography On

A Rare widespread tuberculous spondylitis extended from the T5-T10 levels-a case report

GRADEMARK REPORT

FINAL GRADE

/100

GENERAL COMMENTS

Instructor

PAGE 1

PAGE 2

PAGE 3

PAGE 4

PAGE 5

PAGE 6
