

Effect of nifedipine on apoptosis, necrosis and viability of germinal epithelial cells in the contralateral testicle and plasma testosterone levels in male white rats (*rattus novergicus*, wistar

by Hajid Rahmadianto Mardihusodo

Submission date: 16-Sep-2020 12:24PM (UTC+0800)

Submission ID: 1388309410

File name: osterone_levels_in_male_white_rats_rattus_novergicus,_wistar.pdf (12.03M)

Word count: 61

Character count: 387

EFFECT OF NIFEDIPINE ON APOPTOSIS, NECROSIS AND VIABILITY OF GERMINAL EPITHELIAL CELLS IN THE CONTRALATERAL TESTICLE AND PLASMA TESTOSTERONE LEVELS IN MALE WHITE RATS (*RATTUS NORVEGICUS*, WISTAR STRAIN) AFTER UNILATERAL TESTICULAR TORSION

¹Hajid Rahmadianto Mardihusodo, ¹Fikri Rizaldi, ¹Lukman Hakim.

¹Department of Urology, Faculty of Medicine/Universitas Airlangga, Soetomo General Hospital, Surabaya.

ABSTRACT

Objective: To compare the number of apoptosis, necrosis and viability of germinal epithelial cells in the contralateral testicle (CT) and plasma testosterone (PT) levels in white male rats which administered Nifedipine after unilateral testicular torsion (TT) compared with control group. **Material & Methods:** This research was an experimental study using male white rats (*Rattus Norvegicus*, Wistar strain) aged 10-12 weeks and body weight 150-200 gram. A total of 30 rats were then randomly divided into 5 groups (n=6) which were negative control group (KN), positive control group (KP1 and KP2) and Nifedipine-administered group (N1 and N2). Each group performed unilateral left side torsion of testicular of 1080° anticlockwise except the KN group. There was 4-hour ischemic duration in the KP1 and N1 groups while 10 hours in the KP2 and N2 groups. Administration of Nifedipine 30 minutes before detorsion by intraperitoneal injection dosed 100 µg/kgBW. All groups performed right orchidectomy and plasma blood sampling. Measurement of apoptosis, necrosis and viability of germinal epithelial cells in the CT using flowcytometry. Measurement of PT levels using Enzyme-Linked Immunosorbent Assay (ELISA). **Results:** The number of apoptosis, necrosis and viability of contralateral testicular germinal epithelial cells and PT levels in the KN group compared with KP1 and KP2 groups were significantly different (p<0.05). There was no significant discrepancy in apoptosis (p>0.05) in KP1 group compared with N1 group, as well as in KP2 group compared with N2 groups. The number of necrosis, viability of germinal epithelial cells in the CT and PT level in KP1 group in compared with N1 group, as well as in KP2 group in compared with N2 group were significantly different (p<0.05). **Conclusion:** Nifedipine administration prior to testicular detorsion can maintain cell viability and decrease the amount of necrotic germinal epithelial cells in the CT and prevent the decrease in PT levels after unilateral TT.

Keywords: Nifedipine, viability, apoptosis, necrosis, germinal epithelial cells, contralateral testicle, plasma testosterone, unilateral testicular torsion.

ABSTRAK

Tujuan: Membandingkan jumlah apoptosis, nekrosis dan viabilitas sel epitel germinal testis kontralateral serta kadar testosteron plasma pada tikus putih (*Rattus Norvegicus* strain Wistar) jantan dengan torsio testis unilateral antara kelompok yang diberi Nifedipine dan kelompok kontrol. **Bahan & Cara:** Penelitian ini merupakan studi eksperimental dengan menggunakan hewan coba tikus putih (*Rattus Norvegicus* strain Wistar) jantan umur 10-12 minggu dan berat badan 150-200 gram. Sebanyak 30 tikus dirandomisasi kemudian dibagi menjadi 5 kelompok (n=6) yaitu kelompok kontrol negatif (KN), kontrol positif (KP1 dan KP2) dan perlakuan Nifedipine (N1 dan N2). Masing-masing kelompok dilakukan torsio testis unilateral sisi kiri sebesar 1080° anticlockwise kecuali grup KN. Durasi iskemia 4 jam pada grup KP1 dan N1 sedangkan 10 jam pada grup KP2 dan N2. Perlakuan Nifedipine secara injeksi intraperitoneal 100 µg/kgBB, 30 menit sebelum dilakukan detorsi. Semua kelompok dilakukan orkidektomi kanan dan pengambilan sampel darah plasma. Pengukuran jumlah apoptosis, nekrosis dan viabilitas sel germinal testis kontralateral menggunakan flowcytometry. Pengukuran kadar testosteron plasma menggunakan Enzyme-Linked Immunosorbent Assay (ELISA). **Hasil:** Terdapat perbedaan jumlah apoptosis, nekrosis dan viabilitas sel epitel germinal testis kontralateral serta kadar testosteron plasma pada grup KN dibandingkan dengan grup KP1 dan KP2 secara bermakna (p<0.05). Tidak terdapat perbedaan jumlah apoptosis yang bermakna (p>0.05) antara grup KP1 dan N1 serta grup KP2 dan N2. Untuk jumlah nekrosis dan viabilitas sel tersebut serta kadar testosteron plasma terdapat perbedaan bermakna antara grup KP1 dan N1 serta KP2 dan N2. **Simpulan:** Pemberian Nifedipine sebelum dilakukan detorsi testis dapat mempertahankan viabilitas sel dan menurunkan jumlah nekrosis sel germinal testis kontralateral serta mencegah penurunan kadar testosteron plasma pasca torsio testis unilateral.

Keywords: *Nifedipine, viabilitas, apoptosis, nekrosis, sel epitel germinal testis kontralateral, testosteron plasma, torsio testis unilateral.*

Correspondence: Lukman Hakim; c/o: Department of Urology, Faculty of Medicine/Universitas Airlangga, Soetomo General Hospital Surabaya. Jl. Mayjen. Prof. Dr. Moestopo 6-8 Surabaya 60286. Phone: +62315501318; Fax: +62315024971. Mobile phone: +6281703552448. Email: lukman-h@fk.unair.ac.id.

INTRODUCTION

Testicular torsion is one of the factors causing infertility in men. According to research by Krarup (1978), abnormal sperm analysis results were found in 18 of 19 patients with unilateral testicular torsion (TT).¹ The prevalence of infertile men with a history of TT was about 0.1-1.2%.² Abnormal sperm analysis was obtained at 30-40% of men with a history of TT.^{3,4} Antisperm antibodies detected as many as 11% of patients with TT.^{5,6} The extent of loss of fertility in patients with TT determined by the degree of ischemia and resultant damage to the CT. The damage is an extensively increased apoptosis of the germinal epithelial cells in the CT.^{7,8} The finding was proved by Sukhotnik (2005) that the duration of 1-hour ischemia due to unilateral TT has caused apoptosis.⁹

There are various mechanisms of damage to the CT after IRI caused by unilateral TT. Several mechanisms have been investigated to explain the impairment to the CT: decreased testicular blood flow caused by sympathetic reflex response, autoimmune of spermatogonia, formation of free radical oxygen after detorsion and excessive production of nitric oxide (NO).¹⁰⁻¹²

In men exposed to hypoxia or with conditions that interfere with blood flow to the testes result in alterations in endocrine cell function and decreased sperm production. A common pathophysiological condition in the testes exposed to hypoxia in the TT are increasing temperature in the testes and ROS production. These two causes decreased PT, sperm motility and low sperm count.¹³

Many of the drugs and chemical compounds that have been studied in experimental animals have the potential to decrease or prevent damage caused by IR during TT. Some of the drugs or chemical compounds have been studied are selective endothelin-A receptor inhibitors, Apocynin, Phosphodiesterase Type 5 Inhibitors, Coenzyme Q10, Lycopene, Ginkgo Biloba, Rosuvastatin, Tyrosine Kinase Inhibitors and Nifedipine.¹⁴⁻²²

Nifedipine is a class of calcium antagonists. This drug is useful for vasodilation of smooth muscle

of blood vessels by inhibiting the entry of calcium ions into cells through a voltage gate channel. These effects will slow the damage progression of ischemic tissues. These drugs also have antioxidant effects. Its use is reported could prevent tissue injury caused by post-ischemic reperfusion in stroke and myocardial infarction.^{23,24} Nifedipine administration before testicular detorsion to the experimental animals could prevent further testicular tissue damage due to IRI. The mechanism is by diminishing concentrations of malondialdehyde (MDA), apoptosis and significantly increasing superoxide dismutase (SOD) and glutathione peroxidase (GPx) activity.¹⁶

In this study Nifedipine is expected could prevent further damage caused by IRI in the CT by evaluating the amount of apoptosis, necrosis and viability of germinal epithelial cells in the CT and PT levels in male white rats which unilateral TT had been done 4 and 10 hours previously.

OBJECTIVE

To compare the number of apoptosis, necrosis and viability of germinal epithelial cells in the CT and plasma testosterone (PT) levels in white male rats which administered Nifedipine after unilateral TT compared with control group.

MATERIAL & METHODS

This research was an experimental research using male white rats (*Rattus Norvegicus*, Wistar strain) aged 10-12 weeks and body weight 150-200 grams. The rats were kept in accordance with laboratory standards, the size floor area of the cage about 1500 cm², the height of the top of the cage 22 cm, the room temperature ranges from 20-26°C (air humidity ranges from 40-70%), dark and light exchange every 12 hours and feeding and drinking are provided on ad libitum. Each group was placed in a separate cage and maintained in such a way that it does not interact with each other. This research has obtained ethical eligibility from medical research ethics committee of our institution.

The sample in this study were grouped randomly into 5 groups: negative control (KN),

positive control (KP1 and KP2), Nifedipine group (N1 and N2) each contains 6 rats. Subsequently to group of KP1 and N1 were performed left TT for 4 hours and to group of KP2 and N2 for 10 hours. Surgical action performed sterile. The anesthesia was performed using an intramuscular injection of ketamine 75 mg/kg. Torsion of testicle was performed by twisting the spermatic cord as much as 1080° anticlock wise seen from the caudal. Detorsion of testicle was performed by rewinding spermatic cord as much as 1080° clock wise seen from the caudal. While the KN group performed sham surgery (without TT). In the N1 and N2 groups half an hour before detorsion was administered Nifedipine (Adalat 5 mg Infusions flasche, 0.01% solution; Bayer®, Germany) 100 µg/kgBW in 2 cc normal saline 0.9% (Wida® Normal Saline 0.9% Pasuruan, Indonesia) intraperitoneally. Furthermore, 4 hours after detorsion then performed right orchidectomy. Blood sampling through cardiac puncture as much as 3 ml was inserted in a vacutainer for measurement of PT levels in each group prior to right orchidectomy. At the end of studies, experimental rats did euthanasia procedure. The method uses an internationally agreed standard method. The dose of euthanasia uses 3 times the dose of anesthesia. Rats were incinerated after euthanasia.

The examination of the viability, apoptosis and necrosis of germinal epithelial cells in the CT was determined using flowcytometry with Annexin V binding buffer, propidium iodide (PI) reagents and FITC antibody annexin which purchased from Biolegend, San Diego, CA. Flowcytometry examination was done by making the cell suspension obtained from the CT within 1 hour after the testicular sample received. The preparation of this suspension was done according to previous research.²⁵ Hereafter all samples are ready, at a concentration of 0.25-1.0 x 10⁷ cells/ml, wash cells two times with cold cell staining buffer, and resuspend cells in Annexin V binding buffer. Transfer suspension of cell as much as 100 µl in a 5 ml test

tube. Then add FITC Annexin V(5 µl) and PI Solution (10 µl). Thus, vortex the cells and incubate for 15 min (temperature 25°C) in the dark. Annexin V Binding Buffer as much as 400 µl to each tube is added. Then the sample is inserted into tube and cell calculation analyzed by using automated cell counter FACScan flowcytometer (Becton Dickinson, San Jose, USA).

Plasma testosterone (PT) levels which measured from blood specimens were obtained from the heart puncture and subsequently examined using Enzyme-Linked Immunosorbent Assay (ELISA) kit which acquired from Bioassay Technology Laboratory, Shanghai, China. Blood plasma taken with EDTA or heparin as an anticoagulant. Half an hour after sampling, centrifugation sample for 15 minutes 2000-3000 rpm at temperature 2-8°C. Take the supernatant to run the assay. For each well, take 50 µL sample then add 50 µL HRP labeled Rat T and incubate for 1 hour at 37°C. Aspirate and wash for 5 times. Add substrate A and substrate B for each well. Incubate for 10 minutes at 37°C. Add 50 µL stop solution. Read directly on 450 nm using microplate reader and calculate the result.

The data of this research are presented in percentage form except testosterone levels. This research results are significant if p value less than 0.05. The next step is to do multiple comparison test or Post Hoc Test by Tukey if the test value of one-way ANOVA p<0.05, or Mann-Whitney test if the test value of Kruskal-Wallis p<0.05. Data analysis was evaluated using Statistical Package for Social Sciences (SPSS) software for Windows version 20.0 (IBM SPSS Statistic, IBM Corp., New York).

RESULTS

In this study, it can also be seen that based on homogeneity test of variance can be known that variant of data were non-homogeneous with p value <0.05 (Table 1). Based on this result, we continued to analyse by using Post-Hoc Tamhane test to know the

Table 1. Comparison the amount of viable germinal epithelial cells in the CT on each group.

Group (n=6)	Mean ± SD	Normality Test	Homogeneity Test	One-way Anova Test
KN	94.56 ± 2.38	0.07	0.05	0.00
KP1	89.19 ± 1.00	0.97		
KP2	37.50 ± 1.92	0.95		
N1	92.17 ± 0.85	0.86		
N2	63.62 ± 2.08	0.85		

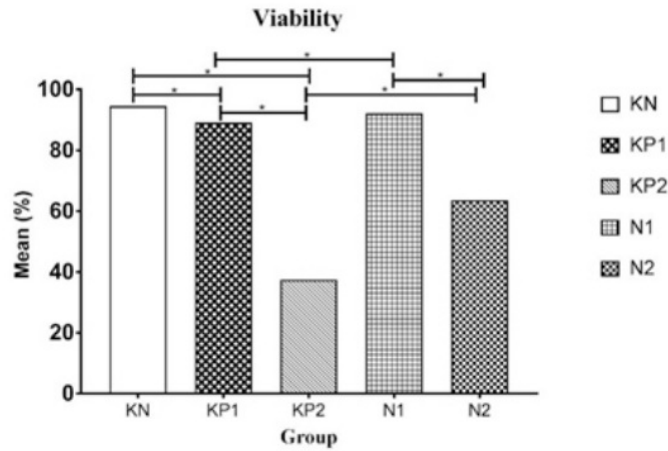


Figure 1. The mean comparison of viability in each group. Asterix sign (*) represents there are significant differences between group statistically.

Table 2. Comparison the amount of apoptotic germinal epithelial cells in the CT on each group.

Group (n=6)	Median (Min-Max)	Normality Test	Kruskal Wallis Test
KN	0.22 (0.14 – 2.85)	0.00	0.00
KP1	1.67 (0.36 – 3.51)	0.04	
KP2	13.00 (9.29 – 45.96)	0.00	
N1	1.33 (0.40 – 1.74)	0.58	
N2	25.39 (22.30 – 28.47)	0.43	

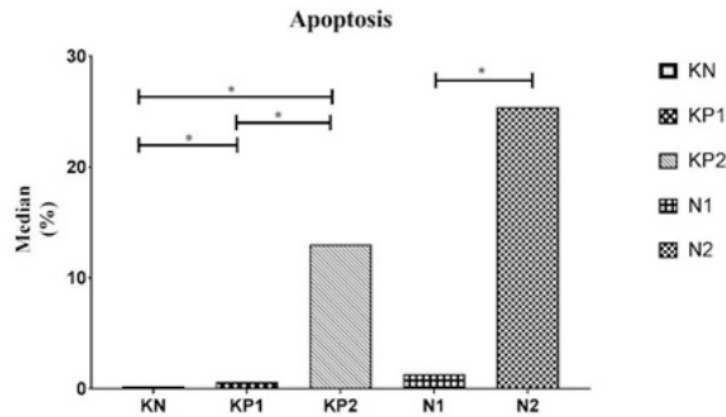


Figure 2. The median comparison of apoptosis in each group. Asterix sign (*) represents there are significant differences between group statistically.

differences of each group. Both in the KP1 group and KP2 group can significantly decrease the viability of germinal epithelial cells in the CT ($p < 0.05$).

Nifedipine administration at N1 group could maintain viability of germinal epithelial cell in the CT compared to KP1, KP2 and N2 group

significantly ($p < 0.05$). The administration of Nifedipine at N2 group was better than KP2 group and the results were statistically significant ($p < 0.05$) that viability of germinal epithelial cells in the CT was higher in group given Nifedipine.

Based on data analysis, there was significant difference of apoptosis of germinal epithelial cells in the CT between groups with p value < 0.05 (Table 2). Based on this result, we continued to analyse by using Post Hoc Mann-Whitney test to know the differences of each group. Post hoc analysis showed that both KP1 group and KP2 group increase apoptosis significantly ($p < 0.05$).

Nifedipine administration in N1 group could significantly inhibit apoptosis compared with KP2 group and N2 group ($p < 0.05$). In this research, it can be seen that the administration of Nifedipine in N1 and N2 group was unlikely able to inhibit cell apoptosis significantly compared with KP1 and KP2 group.

Based on the Post Hoc Mann-Whitney test it

can be seen that both KP1 group and KP2 group can significantly increase cell necrosis ($p < 0.05$). In this study, it can be seen that KP2 group is the group that has the highest necrosis rate (Table 3).

Nifedipine administration at N1 group inhibit necrosis compared with KP1 group, KP2 group and N2 group significantly ($p < 0.05$). It can also be seen that in N2 group showed less necrosis and was statistically significant compared with KP2 group that did not receive Nifedipine ($p < 0.05$).

Testosterone levels between groups in this study were statistically different ($p < 0.05$). In order to know the differences between each group, Post Hoc Mann-Whitney test was used to analysis (Table 4).

It can be noticed that both KP1 and KP2 group had lower PT levels than KN group significantly ($p < 0.05$). Similarly, a similar case occurred when compared to N2 group with a KP2 group ($p < 0.05$). However, when contrasted to N1 group with KP1 and N2 group, the results did not significantly distinction ($p > 0.05$).

Table 3. Comparison the amount of necrotic germinal epithelial cell in the CT on each group.

Group (n=6)	Median (Min-Max)	Normality test	Kruskal Wallis Test
KN	5.19 (1.21 – 7.48)	0.09	0.00
KP1	9.61 (8.82 – 10.19)	0.10	
KP2	48.88 (16.40 – 55.75)	0.02	
N1	6.65 (5.93 – 7.57)	0.79	
N2	10.90 (8.67 – 13.80)	0.63	

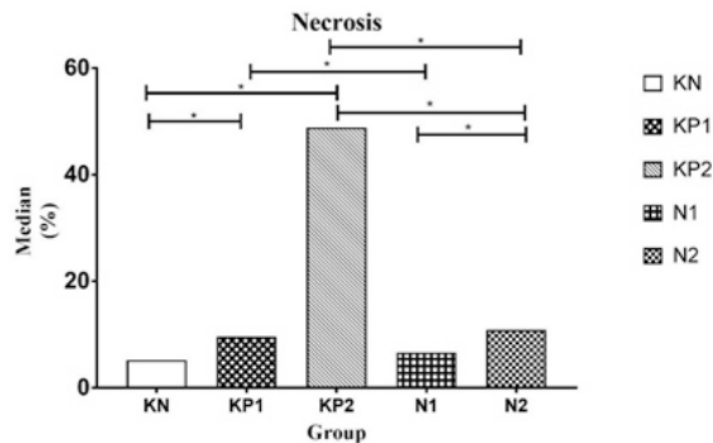
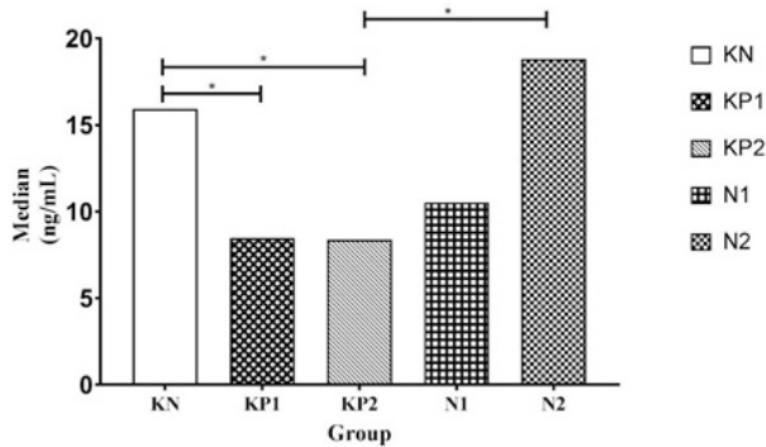


Figure 3. The median comparison of necrosis in each group. Asterix sign (*) represents there are significant differences between group statistically.

Table 4. Comparison of PT levels in each group.

Group (n=6)	Median (Min-Max)	Normality Test	Kruskal Wallis Test
KN	15.93 (11.33 – 21.93)	0.42	0.00
KP1	8.48 (2.47 – 16.15)	0.06	
KP2	8.38 (5.22 – 13.24)	0.04	
N1	10.53 (7.54 – 21.10)	0.78	
N2	18.83 (10.05 – 21.07)	0.58	

**Figure 4.** The median comparison of PT levels in each group. Asterix sign (*) represents there are significant differences between group statistically.

DISCUSSION

Apoptosis of testicular germ cell is a natural occurrence in normal spermatogenesis. This event origins 25-75% in depletion of sperm production.^{26,27} ROS detoxification disorder and increased oxidative stress simultaneously lead to increased apoptosis of testicular germ cells. Chaki et al. (2003) proved that more than 90% of germ cells experienced apoptosis due to ischemia for 12 hours. This is in line with increased lipid peroxidation, a gradual diminish in SOD and activity of catalase enzyme in ischemic testicle and increased glutathione-s-transferases (GST) enzyme activity and H₂O₂ levels.²⁸

Changes in Ca²⁺ mitochondrial deposition (mCa²⁺) and cellular Ca²⁺ are important in IRI pathogenesis. Intracellular Ca²⁺ was increased as well as the mCa²⁺ level increases through the mCa²⁺ uniporter channels. Cell apoptosis can be developed through permeability and pore-forming transitions

which loads of excessive mCa²⁺ could initiate irreversible events. Consequently, mCa²⁺ and cellular Ca²⁺ homeostasis are prominent strategies in preventing IRI. Hence, many studies focus on the role of CCB in the avoidance of IRI in multiple organs.^{29,30}

Nifedipine is a calcium channel blocker (CCB) class that is utilized as a vasodilator and is reported to improve IRI in the heart. Giving of Nifedipine also has the potential to have antioxidant properties. This treatment reduces the capability of monocytes to form superoxide anions from patients who suffered systemic sclerosis by inhibiting the activity of protein kinases. Administration of Nifedipine prior to detection in the case of TT may prevent cellular tissue damage caused by IRI. The experimental study was conducted by Mestrovic et al (2014) in Sprague-Dawley rats treated with unilateral TT of 720 degrees with duration of 3 hours and Nifedipine administration 100 µg/kgBW

intraperitoneally half an hour before detorsion. Superoxide dismutase (SOD) and GPx activity increased in ipsilateral testicle in the Nifedipine treatment group. The levels of malondialdehyde (MDA) and germ cell apoptosis in this group compared with control group were also lower.¹⁶

Other CCB groups studied are useful for preventing IRI due to TT namely Verapamil and Amlodipine. Sarica et al (1999) concluded that the Verapamil administration showed a protective effect both in terms of tubular diameter and histology of testes in the CT. Particularly, protective effect of Verapamil is found to be more prominent after orchidectomy of ipsilateral testicle. The greater part of the specimens acquired from the CT demonstrated normal tubular structures and histologic findings, 1 week after ipsilateral testicular orchidectomy than did testicular detorsion. Thus, Verapamil has a protective effect on histology and tubular characteristics of the CT, particularly after ipsilateral testicular orchidectomy after a certain period of TT.³¹ Amlodipine has a protective effect on testicular tissue damage caused by IRI after TT. Evaluated biochemically there is an increase in SOD and glutathione (GSH) as well as diminished MDA. According to histopathological findings, when seminiferous tubule boundary damage is increased in ischemic testicle, administration of both doses of Amlodipine (5 and 10 mg/kg) significantly decreases this deterioration. This is due to Amlodipine can decrease the increase of mRNA TGF- β expression and TNF- α .³²

In this study duration of ipsilateral TT is linked with an enhance in the amount of germinal epithelial cells apoptosis in CT. Similar results have been demonstrated by Sutkhonik et al (2005) that degree of apoptosis of germ cell in the CT showed a interrelationship with ischemic time. Increased apoptosis of germ cells in the CT integrated with ischemia-induced cell death in the testicle, may cause a deterioration in germ cell and possible lead to a loss of fertility significantly. This is because after IR testicle, there is a histologic change in the CT.⁹ In this study, Nifedipine administration did not significantly affect the prevention of further apoptosis in germinal epithelial cells in the CT due to ipsilateral TT. Different results were obtained when treatment with diclofenac sodium diminished apoptosis of germ cell both in the CT and ischemic testicle but did not alter the histologic parameters of both testicular spermatogenesis because of IRI.³³

Necrosis occurs when cells are severely damaged resulting in loss of membrane integrity,

swelling, and cell rupture. During the necrosis process, cell content released to surrounding area of the cells that cause damage and stimulate a great inflammatory response. The apoptosis and necrosis can be simultaneous, depending on the availability of ATP in the cell. Reactive Oxygen Species (ROS) can cause cell death through the activation of caspase 3-like proteases. Low levels of ROS can stimulate cell death by apoptosis, whereas its high levels stimulate necrosis.³⁴ Between necrosis and serum prostaglandin E2 levels there is a positive correlation after the TT. This is to consider the possibility of immunological process that cause damage to CT.³⁵ In this study Nifedipine was able to prevent necrosis and maintain significant germ cell epithelial viability in the CT due to ipsilateral testicular ischemia for 4 hour and 10 hour. This is in accordance with a study by Mestrovic (2014) that Nifedipine may inhibit further ROS formation due to TT so that in this study there is a decrease in the amount of necrosis in the CT and viability of the cell can be maintained.

In this study, PT levels decreased significantly after the torsion for 4 hours and 10 hours compared with the negative control. According to Becker and Turner (1995) that there is a decline in testosterone levels of more than 80% of the normal value in ipsilateral testicle due to unilateral TT for 1 hour and 4 hours.³⁶ Also, there is decrease testosterone levels in the CT but statistically not significant compared with negative control.

There is an ultrastructural change in the CT due to ipsilateral TT. Leydig cells are the last cell populations affected by testicular ischemia. The proprietary tunica fibers enclosing the seminiferous tubules are thickened due to the increase in collagen fibers. The space between the germ cells and basal lamina is widen by collagen fibers. Mitochondrial degeneration with the loss of crystals was showed in the Leydig cells. This cells lose contact with their environmental cells in several areas, and collagen fibers fulfilled these area. Germ cells of testes indicate the internal dilatation of the fine endoplasmic reticulum and electron-dense bodies of cytoplasm. According to Savas et al (2002), these events may be caused by a decrease in blood flow in the CT which caused by neurovascular reflexes due to unilateral post-testicular ischemia affecting these ultrastructural changes.³⁷ However, Leydig cells are still capable of producing testosterone because it is still sensitive to excitatory Luteinizing Hormones (LH).³⁸ In this study Nifedipine was able to prevent the decrease of testosterone in the 10-hour TT group.

This is probably because Nifedipine has a vasodilator and antioxidant effect that can prevent the dysfunction of Leydig cells so that the production of testosterone is not disturbed. Further study were needed to assess the levels of Follicle Stimulating Hormone (FSH) and LH related to PT levels after unilateral TT in male white rats.

Based on this research, we required a variable dose of Nifedipine to assess the optimal dose of treatment. The effect of Nifedipine on NO and ROS levels can be estimated by measuring MDA, SOD and GPx in contralateral testes in the further research.

CONCLUSION

We deduced that unilateral TT induces an increase in germinal epithelial cells apoptosis and necrosis in the CT. In this experimental study, administration of Nifedipine before testicular detorsion able to maintain viability and inhibit necrosis of germinal epithelial cells in the CT following testicular IRI. Furthermore, reduction of plasma testosterone levels because of it can be inhibited by Nifedipine administration. The treatment of Nifedipine may be advantageous in preventing fertility disorder after IRI because of TT. Absolutely it needs more investigation to support this evidence.

REFERENCES

1. Krarup T. The testes after torsion. *Br J Urol.* 1978; 50(1): 43-46.
2. Osegbe DN, Amaku EO. The causes of male infertility in 504 consecutive Nigerian patients. *Int Urol Nephrol.* 1985; 17(4): 349-58.
3. Anderson JB, Williamson RCN. Fertility after torsion of the spermatic cord. *Br J Urol.* 1990; 65(3): 225-30.
4. Anderson JB, Williamson RCN. The fate of the human testes Following Unilateral Torsion of the Spermatic Cord. *Br J Urol.* 1986; 58(6): 698-704.
5. Hagen P, Buchholz MM, Eigenmann J, Bandhauer K. Testicular dysplasia causing disturbance of spermiogenesis in patients with unilateral torsion of the testis. *Urol Int.* 1992; 49(3): 154-7.
6. Anderson MJ, Dunn JK, Lipshultz LI, Coburn M. Semen quality and endocrine parameters after acute testicular torsion. *J Urol.* 1992; 147(6): 1545-50.
7. Hadziselimovic F, Geneto R, Emmons LR. Increased apoptosis in the contralateral testis in patients with testicular torsion. *Lancet.* 1997; 350(9071): 118.
8. Hardjowijoto S. The effects of unilateral testicular torsion upon immunity modulation and apoptosis of germinal cells in the contralateral testis. *Folia Medica Indones.* 2005; 41(1): 9-17.
9. Sukhotnik I, Miselevich I, Lurie M, Nativ O, Coran AG, Mogilner JG. The time relationship between ipsilateral testicular ischemia and germ cell apoptosis in the contralateral testis in rat. *Pediatr Surg Int.* 2005; 21(7): 512-6.
10. Harrison RG, Moreno De Marval M, Lewis-Jones DI, Connolly RC. Mechanism of damage to the contralateral testis in rats with an ischaemic testis. *Lancet.* 1981; 318(8249): 723-5.
11. Sarica K, Kupeli B, Budak M, Kosar A, Kavukcu M, Durak I, et al. Influence of experimental spermatic cord torsion on the contralateral testis in rats. Evaluation of tissue free oxygen radical scavenger enzyme levels. *Urol Int.* 1997; 58: 208-12.
12. Shiraiishi K, Naito K, Yoshida K. Nitric oxide promotes germ cell necrosis in the delayed phase after experimental testicular torsion of rat. *Biol Reprod.* 2001; 65: 514-21.
13. Reyes JG, Farias JG, Henriquez-Otavarrieta S, Madrid E, Parraga M, Zepeda AB, et al. The hypoxic testicle: Physiology and pathophysiology. *Oxid Med Cell Longev.* 2012; 2012: 929285.
14. Bajory Z, Varga R, Janovszky A', Pajor L, Szabo' A. Micro circulatory effects of selective endothelin- A receptor antagonism in testicular torsion. *J Urol.* 2014; 192(6): 1871-7.
15. Ozbek O, Altintas R, Polat A, Vardi N, Parlakpinar H, Sagir M, et al. The protective effect of apocynin on testicular ischemia reperfusion injury. *J Urol.* 2015; 193(4): 1417-22.
16. Mestrovic J, Drmic-Hofman I, Pogorelic Z, Vilovic K, Supe-Domic D, Seselja-Perisin A, et al. Beneficial effect of nifedipine on testicular torsion-detorsion injury in rats. *Urology.* 2014; 84(5): 1194-8.
17. Ustun H, Akgul KT, Ayyildiz A. Effect of phosphodiesterase 5 inhibitors on apoptosis and nitric oxide synthases in testis torsion: an experimental study. *Pediatr Surg Int.* 2008; 24(2): 205-11.
18. Erol B, Bozlu M, Hanci V, Tokgoz H, Bektas S, Mungan G. Coenzyme Q10 treatment reduces lipid peroxidation, inducible and endothelial nitric oxide synthases, and germ cell-specific apoptosis in a rat model of testicular ischemia/reperfusion injury. *Fertil Steril.* 2010; 93(1): 280-2.
19. Hekimoglu A, Kurcer A, Aral F, Baba F, Sahna E, Atessahin A. Lycopene, an antioxidant carotenoid, attenuates testicular injury caused by ischemia/reperfusion in rats. *Tohoku J Exp Med.* 2009; 218(2): 141-7.
20. Akgul T, Karaguzel E, Surer H. Ginkgo biloba (EGB 761) affects apoptosis and nitric-oxide synthases in testicular torsion: an experimental study. *Int Urol Nephrol.* 2009; 41(3): 531-6.
21. Karakaya E, Ates O, Akg'ur FM, Olguner M. Rosuvastatin protects tissue perfusion in the experimental testicular torsion model. *Int Urol Nephrol.* 2010; 42(2): 357-60.

22. Karaguzel E, Sivrikaya A, Mentese A, Yulug E, Turkmen S, Kutlu O, et al. Investigation of tyrphostin AG 556 for testicular torsion-induced ischemia reperfusion injury in rat. *J Pediatr Urol.* 2014; 10(2): 223-9.
23. Higginson L, Tang A, Knoll G. Effect of intracoronary diltiazem on infarct size and regional myocardial function in the ischemic reperfused canine heart. *J Am Coll Cardiol.* 1991; 18: 868-75.
24. Allanore Y, Borderie D, Perianin A. Nifedipine protects against overproduction of superoxide anion by monocytes from patients with systemic sclerosis. *Arthritis Res Ther.* 2005; 7: 93-100.
25. Krishnamurthy H, Weinbauer GF, Aslam H, Yeung CH, Nieschlag E. Quantification of apoptotic testicular germ cells in normal and methoxyacetic acid-treated mice as determined by flow cytometry. *J Androl.* 1998; 19(6): 710-7.
26. Huckins C. The morphology and kinetics of spermatogonial degeneration in normal adult rats: an analysis using a simplified classification of the germinal epithelium. *Anat Rec.* 1978; 190: 905-6.
27. de Rooij DG, Lok D. Regulation of the density of spermatogonia in the seminiferous epithelium of the Chinese hamster: II. Differentiating spermatogonia. *Anat Rec.* 1987; 217: 131-6.
28. Chaki SP, Ghosh D, Misro MM. Simultaneous increase in germ cell apoptosis and oxidative stress under acute unilateral testicular ischaemia in rats. *Int J Androl.* 2003; 26(6): 319-28.
29. Trocha M, Szelag A. The role of calcium and calcium channel blocking drugs in damage to the liver preserved for transplantation. *Ann Transplant.* 2004; 9: 5-11.
30. Vercesi AE, Kowaltowski AJ, Oliveira HCF, Castilho RF. Mitochondrial Ca^{2+} transport, permeability transition and oxidative stress in cell death: implications in cardiotoxicity, neurodegeneration and dyslipidemias. *Front Biosci.* 2006; 11: 2554-64.
31. Sarica K, Bakir K, Yagci F, Erbagci A, Topcu O, Uysal O. Unilateral testicular torsion: protective effect of verapamil on contralateral testicular histology. *Urol Int.* 1999; 62(3): 159-63.
32. C Dogan, Z Halici, A Topcu, E Cadirci, E Karakus, Y Bayir, et al. Effects of amlodipine on ischaemia/reperfusion injury in the rat testis. *Andrologia.* 2016; 48: 441-52.
33. Mogilner JG, Lurie M, Coran AG, Nativ O, Shiloni E, Sukhotnik I. Effect of diclofenac on germ cell apoptosis following testicular ischemia-reperfusion injury in a rat. *Pediatr Surg Int.* 2006; 22(1): 99-105.
34. Higuchi M, Honda T, Proske RJ, Yeh ET. Regulation of reactive oxygen species-induced apoptosis and necrosis by caspase 3-like proteases. *Oncogene.* 1998; 17(21): 2753-60.
35. Özgür GK, Pişkin B, Sivrikaya A, Gacar N, Erkul S. Effect of testicular torsion on the contralateral testis. *Int Urol Nephrol.* 1990; 22(5): 461-6.
36. Becker EJ Jr, Turner TT. Endocrine and exocrine effects of testicular torsion in the prepubertal and adult rat. *J Androl.* 1995; 16(4): 342-51.
37. Savas C, Ozogul C, Karaoz E, Bezir M. Ischemia, whether from ligation or torsion, causes ultrastructural changes on the contralateral testis. *Scand J Urol Nephrol.* 2002; 36(4): 302-6.
38. Baker LA, Turner TT. Leydig cell function after experimental testicular torsion despite loss of spermatogenesis. *J Androl.* 1995; 16(1): 12-17.

Effect of nifedipine on apoptosis, necrosis and vialibility of germinal epithelial cells in the contralateral testicle and plasma testosterone levels in male white rats (rattus novergicus, wistar

ORIGINALITY REPORT

0 %	%	%	%
SIMILARITY INDEX	INTERNET SOURCES	PUBLICATIONS	STUDENT PAPERS

PRIMARY SOURCES

Exclude quotes	On	Exclude matches	Off
Exclude bibliography	On		

Effect of nifedipine on apoptosis, necrosis and viability of germinal epithelial cells in the contralateral testicle and plasma testosterone levels in male white rats (rattus norvegicus, wistar)

GRADEMARK REPORT

FINAL GRADE

/100

GENERAL COMMENTS

Instructor

PAGE 1

PAGE 2

PAGE 3

PAGE 4

PAGE 5

PAGE 6

PAGE 7

PAGE 8

PAGE 9
