

# Bite Mark Analysis with ‘Stamping’ Method in Child Abuse Case - A Case Report

*by* Dina Karimah Putri

---

**Submission date:** 03-Sep-2020 06:23PM (UTC+0800)

**Submission ID:** 1378816800

**File name:** sis\_with\_Stamping\_Method\_in\_Child\_Abuse\_Case\_-\_A\_Case\_Report.pdf (437.07K)

**Word count:** 2520

**Character count:** 12593

## Bite Mark Analysis with “Stamping” Method in Child Abuse Case A Case Report

Dina Karimah Putri<sup>1</sup>, Mieke Sylvia MAR<sup>2</sup> and Ahmad Yudianto<sup>3</sup>

<sup>1</sup>Student in Postgraduate School of Forensic Science, Universitas Airlangga, Surabaya, Indonesia

<sup>2</sup>Department of Forensic Odontology, Faculty of Dental Medicine, Universitas Airlangga, Surabaya, Indonesia

<sup>3</sup>Department of Forensic Medicine and Medicolegal, Faculty of Medicine, Universitas Airlangga, Surabaya, Indonesia

**Keywords:** Bite Marks, Child Abuse, Forensic Odontology, Human Identification

**Abstract:** Bite marks as evidence of a crime cases are commonly found in cases such as sexual assault, struggle, homicide and child abuse. Bite marks are thought to help uncover the biter because human teeth are individualistic and have different shapes, sizes and patterns for each individual, even identical twins. This report is to explain how to analyze bite marks using a “stamping” method in child abuse cases. In this case report, we present a case of 17-month-old toddler who was found dead in his house with head trauma and two scars resembling human bite marks on the right chest and abdomen. Those scars appeared not as a new bite and that implies these bites happened before the death of the toddler. Investigators assumed that he was a victim of child abuse which led to the murder. Although the autopsy results showed the cause of death was not from the bite but from the blunt object trauma to his head, by analyzing the evidence of bite marks found on the victim's body it can be expected to provide information about the motives and background of the murder and help find the perpetrator of the bite-related injury. Analysis was done by using a “stamping” method of the suspect's bite marks who was asked to bite a wax that had been flexed with heat and then superimposed with a photo of bite marks on the victim's body with a size close to the actual size. The result showed that the bite marks matched the bite of the victim's father who was also suspected of being the murderer. The bite pattern of the toddler's father had similarity with the bite marks found on the victim's body, so he has possibility to be included as the suspected biter.

### 1 INTRODUCTION

Abuse is a word commonly translated into violence, ill-treatment, torture, or mistreatment, improper behavior that results in physical, psychological or financial harm, whether experienced by individuals or groups. Child abuse (CA) is a term often used to describe violence against children, sometimes referred to as child maltreatment. In an Encyclopedia Article from Encarta, CA is defined as a deliberate act that causes harm to children physically or emotionally. The term CA covers a wide range of behaviors, from direct physical threats by parents or other adults to neglect of the basic needs of the child (Huraerah, 2007).

CA is a common case type in Indonesian society with low handling and uncoordinated levels and lack of cooperation from related fields. CA itself can adversely affect the child's life from the failure of growth and development, brain damage, bone

fracture, mental retardation, psychiatric disorders and even death (Huraerah, 2007).

Bite marks as evidence of a crime are commonly found in cases such as sexual assault, struggle, homicide and child abuse, in consequence ante-mortem human bites are highly significant from a medico-legal point of view (Prasad *et al.*, 2013). Bites can be attack actions by the perpetrator as well as a form of self-defense for the victim. Bite marks are thought to help uncover the biter because human teeth are individualistic and have different shapes, sizes and patterns for each individual, even identical twins (Verma *et al.*, 2013).

A bite mark may be defined as the physical alteration on a surface such as skin or food that is caused by the dentition of a human or animal (Kieser *et al.*, 2007). Bite mark is a pattern mold as a result of contact with an object or teeth (bite) on the skin. The bite pattern has an image of highly characteristic dental anatomy that leaves the bite pattern on human

connective tissue caused by both animals or humans, each of which is very different. Bite patterns in child abuse cases can occur in all locations or around the body of children. This is due to an application of impingement of the psychic disorder of the offender. Location of bite pattern on certain body parts includes back area, upper shoulder, and neck (Lukman, 2006; Senn and Weems, 2013).

Occlusional bite marks are described as oval-to circular-patterned injuries that typically consist of two opposing U-shaped arches, each representing a maxillary and mandibular arch, separated to some degree at their bases (Kieser *et al.*, 2007).

Bite mark comparisons are accepted in court as roughly equivalent to finger prints (Rhai and Vidanapathirana, 2008). Analyzing bite marks is a complicated procedure which is conducted by forensic odontologists because it requires comparison data from the biter (Adams, Carabott and Evans, 2014). The reliability of bite mark evidence rests on the assumption that no two humans have identical dentitions in respect to the size, shape, or arrangement of the teeth (Kieser *et al.*, 2007). Based on American Board of Forensic Odontologist guidelines, there are some methods to compare exemplars of human bite marks, such as overlays, test bites, comparison techniques, and other methods including transillumination of tissue, superimposition histology, computer enhancement and/or digitization of mark and/or teeth, and so on (American Board of Forensic Odontology, 2016).

## 2 CASE REPORT

A 17-month-old toddler, boy, was found asleep by his mother after work at his home. The mother thought her son was sick and then took him to the hospital. At that time his father was at home. After being examined at the hospital, the toddler was already dead. Because so many injuries were found on his body, it was presumed that the toddler was a victim of murder. Since the last person with the toddler was his father, then his father was arrested and examined related to injuries found on the victim's body. Upon investigation, it turned out that the father of the child had a history of being treated at a mental hospital.

The victim was found dead at his home with his body wrapped in an adult jacket and still wearing pampers. There were many bruises on his face and there were livor mortis and rigor mortis when examined in the morgue. There was no sign of violence in the neck and genitals but many scars and bruises were found on parts of his body, including:

- on the lower area of the right armpit to the chest there was a dark brown scar resembling a bite mark with size 3 cm x 2.5 cm (see Fig. 1).
- on the abdominal area below the right nipple, there was an oval-shaped scar, dark brown in color, resembling a bite mark with size 3 cm x 2 cm. (see Fig. 2).

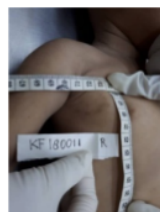

Figure 1 Bite mark on victim's body, near right armpit.

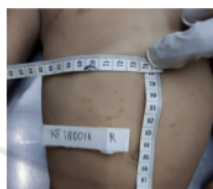

Figure 2 Bite mark on the abdominal area below the right nipple.

The results of internal examination (autopsy) found blood absorption in the right chest cavity, middle and lower right and left lung and also in the liver and kidney. There was bleeding as much as 81 ml on the underlying scalp tissue. There were fractures on the forehead bone, left cranium, left eyelid bone and occipital bone. There were rips behind the left cerebral membrane and on the back of the left cerebrum along 8 cm, as well as bleeding in the cerebellum. There were no abnormalities in toxicology, pathology and bacteriology examinations. Based on the autopsy result, cause of death of this toddler is homicide caused by blunt objects.

## 3 ANALYSIS METHOD

Analyzing bite mark is done by various steps. Before the comparison, firstly, the bite mark should be carefully documented by digital photography from different angles with the plane of the film at right angles to that of the lesion with a scale. Bite marks should not be touched before the swab is carried out to recover saliva. This step is important in helping to

identify or exclude the perpetrator. But sadly in our case, this step can't be done because the bite mark was not a new lesion that happened during the incident, so the saliva was already dry.

After those steps, an impression of the bite should be made. In this case, authors used a test bite method with wax material, which is a dental modelling wax. Although in this method we didn't use the technique of "stamping" in general due to a condition that was not possible, but we still call this method "stamping" because we did teeth printing – it's just that in this case we used wax not alginat -then tracing it on mica paper, without first stamping the occlusal plane on the stamp pad. The wax was heated using spiritus brender until the wax is pliable and easy to bite. Authors chose to use this material to make prints of the subject's bite mark due to the condition of the subject who experienced mental disorders, so we thought if we used impression materials such as alginat, it would be more difficult and could make the subject uncomfortable and uneasy.

After the bite patterns on the wax were obtained, then these patterns were traced on mica paper. The tracing results of the bite patterns on mica paper were then put on top of a photo of bite marks on the victim's body with scale close to actual size, for a comparison. To prevent anxiety from the suspected perpetrator who is the toddler's father, so the process of taking bite patterns was also done to the mother of

the toddler. It is also used as comparison material in the analysis of bite marks on the body of the toddler. We just did a comparison on the bite marks found on the victim's abdominal area because it is easily done for analysis and no distortion of the pattern.

The typical features to record for comparisons include rotation of teeth, displacement of teeth from the arch form, spacing between teeth, and anatomy of incision edges (Omar *et al.*, 2015). After observing carefully, bite marks found on the victim's body were similar to the bite patterns on the upper teeth of the toddler's father, because there was a space between left central insicivus and right lateral insicivus of the bite mark, which means there were missing teeth of right central insicivus, as seen on upper teeth wax.

The use of image editing and computer-assisted bitemark analysis has been documented for more than 20 years. The efficacy of such techniques has been tested among forensic odontologists and general dentists. The most commonly used image processing software is Adobe Photoshop (Kieser *et al.*, 2007), but because that software is not free software, therefore, the authors then did superimposition images using computer software (GIMP 2.0) to compare patterns of upper teeth bite with bite marks on the victim's body, by changing the opacity of the image until both pictures truly coincide and match (Fig. 5).



Figure 3 Bite patterns on the dental modelling wax from the suspected biter (toddler's father). (A) upper teeth; (B) lower teeth.



Figure 4 Tracing on mica paper from (A) upper teeth and (B) lower teeth.

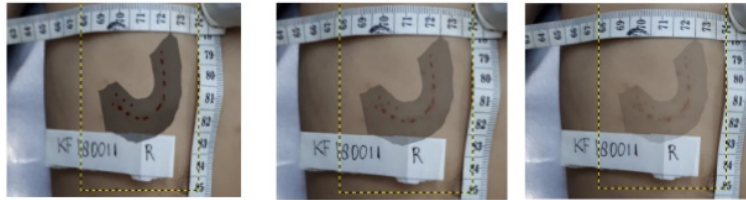


Figure 5 Superimposed images of traced-bite patterns and bite mark on victim's body with opacity, from left to right: 100 %; 60 % and 30 %.

#### 4 CONCLUSIONS

Based on this analysis, we can conclude that the bite mark which is on the abdominal area of the victim's body was from the upper teeth which means the strongest bite comes from the upper teeth. Also the position of the biter was next to the right of the victim during the attack. As forensic odontologists in Indonesia, we can not make our own conclusion about who the biter is, because the decision is for the investigator. We only act as experts who help the investigator to analyze the bite marks according to our ability and knowledge. That is why, we can only conclude based on this analysis result that the bite pattern of the toddler's father has similarity with bite marks found on the victim's body, so he has possibility to be included as the suspected biter. To confirm more precisely, we need to do DNA analysis from a saliva swab on bite marks and then compare with DNA from the suspected biter, but because this bite mark was not new we can not do that. Because the bite marks were not the bite performed while killing the toddler, which is marked by prints of each tooth, it was not so clear and dark brown in color which means skin tissue has already started to repair, then it is presumed that before the incident which caused the death, the toddler was already a victims of violence/abuse. This can be proof in digging for information related to the motives and background of the murder committed by the victim's father, who is also known to have a history of mental illness.

#### ACKNOWLEDGEMENTS

Thank you to Forensic Medicine and Medicolegal Department RSUD Dr. Soetomo, Polsek Tambaksari Surabaya, our advisors, and all those who have supported us furthering our case report through feedback and presentations opportunities.

#### REFERENCES

- Adams, C., Carabott, R. and Evans, S. (2014) *Forensic Odontology: An Essential Guide*.
- American Board of Forensic Odontology (2016) *ABFO Bitemark Methodology Standards and Guidelines Standards*. Available at: <http://abfo.org/wp-content/uploads/2016/03/ABFO-Bitemark-Standards-03162016.pdf> (Accessed: 16 October 2017).
- Huraerah, A. (2007) *Child Abuse (Kekerasan terhadap Anak)*. Edisi revi. Bandung: Penerbit Nuansa.
- Kieser, J., Tompkins, G., Buckingham, D., Firth, N. A. and Swain, M. (2007) 'Bitemarks: Presentation, Analysis, and Evidential Reliability', in *Forensic Pathology Review*. Humana Press Inc., pp. 157–176.
- Lukman, D. (2006) *Ilmu Kedokteran Gigi Forensik: Jilid 2. Jilid 2*. Jakarta: CV. Sagung Seto.
- Omar, K., Priyadarshi, P., Singh, A. and Srivastava, R. (2015) 'The bite that bites back the perpetrator', 3(2), pp. 21–33.
- Prasad, Y. S., Lalwani, S., Rautji, R. and Dogra, T. D. (2013) 'Case Report Perimortem Human Teeth Bite Mark : A Resuscitative Artefact Introduction : External Examination : Corresponding Author : Internal Examination : Discussion ', 35(2), pp. 184–186.
- Rhai, R. and Vidanapathirana, M. (2008) 'An alleged case of unusual human bite', 13(1), pp. 74–75.
- Senn, D. R. and Weems, R. A. (2013) *Manual of Forensic Odontology*. 5th ed. Boca Raton: CRC Press, Taylor and Francis Group.
- Verma, K., Joshi, B., Joshi, C. H. and MP, R. P. (2013) 'Bite Marks as Physical Evidence from the Crime Scene - An Overview', *Open Access Scientific Reports*, 2(1), pp. 1177–1188. doi: 10.4172/scientificreports.

# Bite Mark Analysis with 'Stamping' Method in Child Abuse Case - A Case Report

## ORIGINALITY REPORT

14%

SIMILARITY INDEX

7%

INTERNET SOURCES

10%

PUBLICATIONS

1%

STUDENT PAPERS

## PRIMARY SOURCES

1	Jules Kieser. "Bitemarks", Forensic Pathology Reviews, 2005 Publication	4%
2	RHAI Rathnaweera, M Vidanapathirana. "An alleged case of unusual human bite", Galle Medical Journal, 2009 Publication	2%
3	iafmonline.in Internet Source	2%
4	Forensic Pathology Reviews, 2005. Publication	1%
5	unair.ac.id Internet Source	1%
6	www.jdentistry.ui.ac.id Internet Source	1%
7	Submitted to iGroup Student Paper	1%

Ghassem Ansari, Mojtaba Vahid Golpayegani,

8	Richard Welbury. "Etiology and Pathology of Teeth Disturbances", Wiley, 2018	1%
Publication		
9	"A Practical Guide to the Evaluation of Child Physical Abuse and Neglect", Springer Science and Business Media LLC, 2019	1%
Publication		
10	repository.unair.ac.id	<1%
Internet Source		
11	api.research-repository.uwa.edu.au	<1%
Internet Source		

Exclude quotes  On

Exclude matches  Off

Exclude bibliography  On

# Bite Mark Analysis with ‘Stamping’ Method in Child Abuse Case - A Case Report

---

GRADEMARK REPORT

---

FINAL GRADE

**/100**

GENERAL COMMENTS

**Instructor**

---

PAGE 1

---

PAGE 2

---

PAGE 3

---

PAGE 4

---