

The morphological endogenous development of *Eimeria necatrix* at primary and secondary infected chickens and its histopathological effect

by Endang Suprihati

Submission date: 21-Aug-2020 02:56PM (UTC+0800)

Submission ID: 1372143868

File name: The_morphological_endogenous....pdf (339.21K)

Word count: 1985

Character count: 11286

The morphological endogenous development of *Eimeria necatrix* at primary and secondary infected chickens and its histopathological effect

M Yunus^{1*}, E Suprihati¹ and A Wijaya²

¹Department of Veterinary Parasitology, Universitas Airlangga

²Department of Veterinary Clinic, Bogor Agricultural University

*Corresponding author: (muhyunus_99@yahoo.com)

Abstract. The endogenous development of *E. necatrix* was observed at primary and secondary infected chicken to know protective immunity development on host. The present study used 25 broiler chickens at 3 weeks old were divided into 2 groups. Group 1 was 10 chickens administered aquades, after 14 days then challenged 5×10^3 *E. necatrix* oocysts, 4 days post challenged 5 chickens were sacrificed to observe morphological endogenous development of parasites by histopathological changes examination, while oocysts production was calculated on 5 other chickens from day 6 to 12 post challenged. Group 2 was 15 chickens inoculated 5×10^2 *E. necatrix* oocysts, 4 days pi 5 chickens were sacrificed to observe morphological endogenous development of parasites by histopathological changes examination for primary infection. The results show that group 1, in si, parasites were development and proliferation well, whereas group 2, in si was seen few development and proliferation of parasites. In conclusion, the endogenous development disabilities of parasites occur as a result of protective immunity generated resulting from the first antigen exposure so that proliferation and multiplication of parasites became decreased.

4 Introduction

Coccidiosis in chickens is a parasitic disease with great economic significance, which has been controlled successfully for decades using mainly anticoccidial products. However, large-scale and long-term use of anticoccidial drugs has led to the worldwide development of resistance against all these drugs [1], together with their possible toxic effect to the human consumers. To overcome this condition the choice to approach vaccine use in controlling a more intensive and planned disease is needed. The use of vaccines to control coccidiosis is expected to avoid or reducing dependence on the use of coccidiostats and other chemicals. *E. necatrix* has been recognised as the most pathogenic *Eimeria* species which infects chickens [2].

The exploring potency of *E. necatrix* oocyst in inducing protective immunity is important done particularly the low dose exposure in order to the initial development of material part of chicken coccidiosis polyvalent live vaccine. The low dose at the primary exposure was purposed to observe the morphological endogenous development of *E. necatrix* in the non *E. necatrix* exposure chicken then compared with secondary exposure at *E. necatrix* challenged chicken at the infected dose.

2. Materials and Methods

Twenty five broiler chickens at three weeks old were divided into two groups. Group 1 was 10 chickens administered aquades, after 14 days then challenged 5×10^3 *E. necatrix* oocysts, 4 days post challenged 5 chickens were sacrificed to observe morphological endogenous development of parasites

by histopathological changes examination, while oocysts production was calculated on 5 other chickens from day 6 to 12 post challenged. Group 2 was 15 chickens inoculated 5×10^2 *E. necatrix* oocysts, 4 days post inoculation 5 chickens were sacrificed to observe morphological endogenous development of parasites by histopathological changes examination for primary infection, while oocysts production was calculated on 10 other chickens from day 6 to 12 post primary inoculation, 14 days post primary inoculation then challenged 5×10^3 *E. necatrix* oocysts, at 4 days post secondary infection, 5 chickens were sacrificed to observe morphological endogenous development of parasites by histopathological changes examination for secondary infection, while oocyst production calculation was done at 6 to 12 days post challenged on other chickens for secondary infection

3. Results and Discussion

The clinical signs of infected chicken groups (Group 2) at low doses of *E. necatrix* were not seen clearly during the primary infection such as dehydration, dysentery, diarrhea, and only few decreased appetites, whereas in secondary infection there were no coccidiosis clinical signs. The group 1, chicken group without primary infection appeared clearly coccidiosis clinical signs after challenge infection. On group 2, in primary infection, the stages of parasite were histologically normal as well as the multinucleated immature schizonts, however few the generation schizonts were observed within epithelial cells synergistically with primary infected doses, whereas in secondary infection, few the multinucleated immature schizonts and generation schizonts appeared less developed in epithelial cells. On group 1, in primary infection, there was no endogenous development stage of parasite due to only water administered, while in secondary infection, the stages of parasite were histologically normal as well as the multinucleated immature schizonts, numerous the generation schizonts were observed within epithelial cells. Furthermore on group 2, total oocyst production at primary infection was higher than secondary infection, whereas on group 1, total oocyst production of chicken group without primary infection was higher than secondary infection in chicken group with primary infection (Group 2).

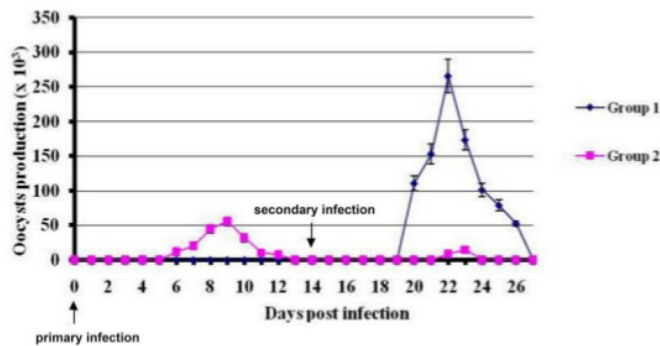


Figure 1. The pattern of daily oocyst production at each groups (G1 and G2) during primary and secondary infections. The reduction of oocyst production in secondary infection after primary infection using low doses of parasites (*E. necatrix*) showed potential capacity low doses in induction of protective immunity on hospes.

The low doses of each *Eimeria* sp were not enough to become massive propagation in site infection so that limited development and parasites were not enough to cause damage at site infection for manifestation of clinical signs. Those signs were not seen clearly during primary infection at low dose but the low dose already able to induce protective immunity on host so that on secondary infection was also not seen clinical signs although in higher doses. The same conditions also occur in the development and multiplication of parasites. Infection with one species of *Eimeria* induces protective immunity in the host that is long lasting and exquisitely specific to that particular parasite [3].

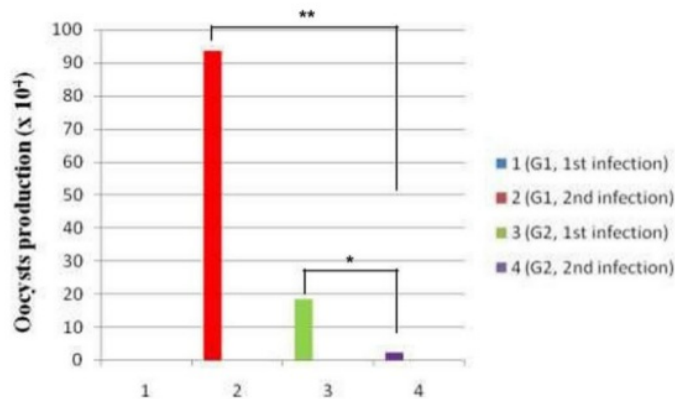


Figure 2. The comparison of totally oocysts production between low doses (primary infection) and infected doses (secondary infection) of G2 and the comparison of totally oocysts production at secondary infection between G1 (without primary infection) and G2 of *E. necatrix*. There was significantly difference between low doses and infected doses of G2 *E. necatrix* infected chicken. Reduction of oocyst production in secondary infection due to the presence protective immunity by primary infection. It means potential capacity of low doses could express immunogenicity that can suppress the propagation level against challenge infection. **, $p < 0.01$

1 While a large number of inoculating oocysts is generally required to generate an immune response against *Eimeria*, some exceptions have been noted, e.g. *E. maxima* is highly immunogenic and requires only a small number of oocysts to induce almost complete immunity. In this study proved that low doses of *E. necatrix* in primary infection can suppress propagation level by oocyst production at challenge infection (**Figure. 3**).

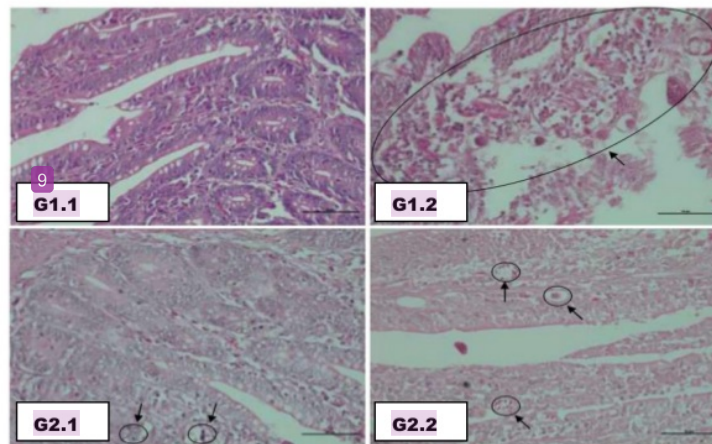


Figure 3. Histopathological changes of mid small intestine by *E. necatrix* oocyst infected chickens.

1 The early endogenous stages of the parasite life cycle are considered to be more immunogenic than the later sexual stages [3] although Wallach et al. [4, 5] showed that immunization with recombinant gamete associated antigen induced partial protection against challenge infection. Studies using oocysts irradiated to prevent intracellular development, but not invasion, demonstrated partial protection against challenge infection, thereby suggesting that sporozoites may also be immunogenic [6]. Immunity to *Eimeria* is stimulated by the initial developing parasite stages, particularly the schizonts, and subsequently boosted and maintained by multiple re-exposure to oocysts in the litter. Thus, the recycling of infection following administration of live oocysts is critical for the

development of protective immunity [7].

In primary infection, (G1.1), there was no endogenous development stage of parasite due to only water administered, the same condition occurred at *E. necatrix* in low doses infected chickens (G2.1), arrow, which parasite appeared clearly well development in the primary infection, although few proliferation and multiplication of *E. necatrix* in epithelial cell of small intestine. In secondary infection, (G1.2), erosion of surface and damage of epithelial cell of mid small intestine due to development of *E. necatrix* continuously, arrow, propagation of *E. necatrix* in site infection, erosion of mucosa surface of mid small intestine and be accompanied many parasites proliferation, arrow. On G2.2 chicken infection, a few endogenous development of parasites due to the presence of protective immunity by induction of primary infection, arrow. Magnification x400.

Researchers used different criteria to evaluate coccidial infections. Some suggested that oocyst production might be a very unreliable quantitative criterion [8] as the number of oocysts produced is affected by factors such as the inherent potential of each species to reproduce in a non-immune host; immunity or resistance developed by the host; the 'crowding' factor; competition with other species of coccidian or other infectious agents; nutrition of the host; and strain differences of the host. The inherent difference in reproductive potential is high for *E. tenella* and *E. acervulina*, and low for *E. maxima*. Immunity, which is specific to each coccidian species, results in decreased production of oocysts after ingestion of infective oocysts [9].

4. Conclusions

We concluded that the endogenous development disabilities of parasites occur as a result of protective immunity generated resulting from the first antigen exposure so that proliferation and multiplication of parasites became decreased.

5

Acknowledgements

This research was supported by Directorate of Higher Education, Ministry of Education and Culture of the Republic of Indonesia for funding through higher education excellence research grant for a research contract number Nomor: 122/SP2H/PTNBH/DRPM/2018

References

- [1] Peek H W and Landman W J 2011 Coccidiosis in poultry: anticoccidial products, vaccines and other prevention strategies. *Vet. Q* 31(3):143-61.
- [2] Blake D P, Clark E L, Macdonald S E, Thenmozhi V, Kundu K, Garg R, et al 2015 Population, genetic, and antigenic diversity of the apicomplexan *Eimeria tenella* and their relevance to vaccine development. *Proc. Natl. Acad. Sci. U. S. A* **112**: E5343 - 50.
- [3] Yun C H, Lillehoj H S and Lillehoj E P 2000 Intestinal immune responses to coccidiosis. *Develop. Comp. Immunol* **24** 303-24.
- [4] Wallach M, Pillemer G, Yarus S, Halabi A, Pugatsch T and Mencher D 1990 Passive immunization of chickens against *Eimeria maxima* infection with a monoclonal antibody developed against a gametocyte antigen. *Infect. Immun* **58** 557- 62.
- [5] Wallach M, Smith NC, Petracca M, Miller CM, Eckert J. and Braun R 1995 *Eimeria maxima* gametocyte antigens: potential use in a subunit maternal vaccine against coccidiosis in chickens. *Vaccine* **13** (4) 347-54.
- [6] Jenkins M C, Augustine P C, Danforth H D. and Barta J R 1991 X-irradiation of *Eimeria tenella* oocysts provides direct evidence that sporozoite invasion and early schizont development induce a protective immune response(s). *Infect. Immun* **59** 4042-8.
- [7] Chapman H D. and Cherry T E 1997 Eyespray vaccination: infectivity and development of immunity to *Eimeria acervulina* and *Eimeria tenella*. *J. Appl. Poult. Res.* **6** (3) 274-8.
- [8] Oikawa H, Kawaguchi H, Nakamoto K. and Tsunoda K 1975 Field surveys on coccidial infection in broilers in Japan--results obtained in autumn and winter and summarized in 1973 *Nihon Juigaku Zasshi* **37**(3) 271-9.
- [9] Arabkhazaeli F, Nabian S, Modirsaneii M, Mansoori V and Rahbari S 2011. Biopathologic characterization of three mixed poultry *Eimeria* spp. isolates. *Iran J. Parasitol.* **6** (4): 23-32.

The morphological endogenous development of Eimeria necatrix at primary and secondary infected chickens and its histopathological effect

ORIGINALITY REPORT

25%

SIMILARITY INDEX

21%

INTERNET SOURCES

21%

PUBLICATIONS

0%

STUDENT PAPERS

PRIMARY SOURCES

| | | |
|---|--|----|
| 1 | C Yun. "Intestinal immune responses to coccidiosis", <i>Developmental & Comparative Immunology</i> , 2000 Publication | 7% |
| 2 | www.pubmedcentral.nih.gov Internet Source | 6% |
| 3 | sirtsignaling.com Internet Source | 3% |
| 4 | www.tandfonline.com Internet Source | 3% |
| 5 | s3-eu-west-1.amazonaws.com Internet Source | 2% |
| 6 | www.j3.jstage.jst.go.jp Internet Source | 1% |
| 7 | B. Chengat Prakashbabu, V. Thenmozhi, G. Limon, K. Kundu et al. "Eimeria species occurrence varies between geographic regions" | 1% |

and poultry production systems and may influence parasite genetic diversity", *Veterinary Parasitology*, 2017

Publication

8

YUNUS, Muchammad, Yoichiro HORII, Susumu MAKIMURA, and Adrian L. SMITH. "The Relationship Between the Anticoccidial Effects of Clindamycin and the Development of Immunity in the *Eimeria pragensis*/Mouse Model of Large Intestinal Coccidiosis", *Journal of Veterinary Medical Science*, 2005.

Publication

1%

9

citeseerx.ist.psu.edu

Internet Source

1%

Exclude quotes Off

Exclude matches Off

Exclude bibliography On

The morphological endogenous development of Eimeria necatrix at primary and secondary infected chickens and its histopathological effect

GRADEMARK REPORT

FINAL GRADE

/0

GENERAL COMMENTS

Instructor

PAGE 1

PAGE 2

PAGE 3

PAGE 4
